

## Case report

# Resistant orbital pseudotumor treated with rituximab in a patient with systemic lupus erythematosus. A case presentation

Carmen María Escudero González,\* Sergio Rodríguez Montero, Rosalía Martínez Pérez, Carolina Pastor Mañosa, María Luisa Velloso Feijoo, and José Luis Marengo de la Fuente

Servicio de Reumatología, Hospital Universitario Virgen de Valme, Sevilla, Spain

### ARTICLE INFO

#### Article history:

Received April 27, 2009

Accepted July 8, 2009

#### Keywords:

Exophthalmos

Systemic lupus erythematosus

Orbital pseudotumor

Rituximab

### ABSTRACT

Ocular manifestations in Systemic Lupus Erythematosus (SLE) are relatively frequent, with a major prevalence of the Keratoconjunctivitis sicca. Nevertheless, the appearance of unilateral exophthalmos secondary to orbital pseudotumor in patients with SLE is extremely rare,<sup>1-7</sup> and on occasion it can be refractory to conventional pharmacological treatment (glucocorticoids and immunosuppressants). We present the case of a patient with SLE and orbital pseudotumor refractory to treatment with Cyclophosphamide (CF) and an excellent clinical response, with disappearance of the ophthalmological condition after the beginning of therapy with Rituximab (1 g×2), continuing after the infusion of two complete cycles without incidents.

© 2009 Elsevier España, S.L. All rights reserved.

## Pseudotumor orbitario refractario tratado con rituximab en paciente con lupus eritematoso sistémico. A propósito de un caso

### RESUMEN

Las manifestaciones oculares en el lupus eritematoso sistémico (LES) son relativamente frecuentes, con mayor prevalencia de la queratoconjunctivitis seca. Sin embargo, la aparición de exoftalmos unilateral secundario a pseudotumor orbitario en pacientes con LES es extremadamente rara,<sup>1-7</sup> y en ocasiones puede presentarse refractaria al tratamiento farmacológico convencional (glucocorticoides e inmunosupresores). A continuación presentamos el caso de una paciente con LES y pseudotumor orbitario refractario a tratamiento con ciclofosfamida y excelente respuesta clínica con desaparición de la clínica oftalmológica tras el inicio de la terapia con rituximab (1 g × 2), eficacia mantenida tras la infusión de dos ciclos completos sin incidencias.

© 2009 Elsevier España, S.L. Todos los derechos reservados.

#### Palabras clave:

Exoftalmos

Lupus eritematoso sistémico

Pseudotumor orbitario

Rituximab

## Introduction

Ocular manifestations related to Systemic Lupus Erythematosus (SLE) have an incidence estimated between 3–30%<sup>2,6</sup> according to different series, affecting both the anterior and posterior segments of the eye. However, the appearance of exophthalmos secondary to inflammatory orbital pathology in patients with SLE, of which there are few published cases, is extremely rare.<sup>1-7</sup> When faced with a

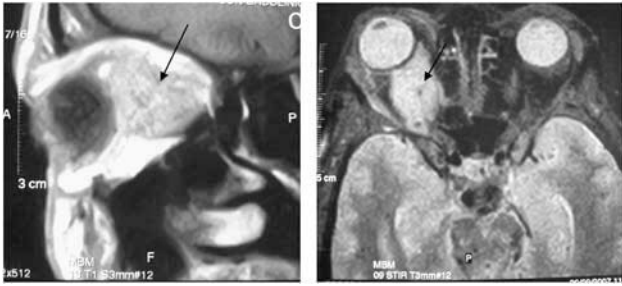
unilateral exophthalmos, one must consider a differential diagnosis that includes infectious, neoplastic and endocrine processes (Graves disease), connective tissue diseases and systemic pathologies (vasculitis, SLE), among others.<sup>9,10</sup> We present the case of a patient with SLE and unilateral exophthalmos which was secondary to a steroid and immunosuppressant resistant orbital pseudotumor, treated satisfactorily with rituximab (RTX).

## Case report

Forty-nine year old woman with a history of hypertension, diabetes type 1 under insulin treatment with good glycemic control, extrinsic asthma and intermittent episodes of unilateral amaurosis of the right eye. In November 2006 she presented

\* Corresponding author.

E-mail address: [carmenescu1@hotmail.com](mailto:carmenescu1@hotmail.com) (C.M. Escudero González).



**Figure.** Parasagittal (left) and coronal (right) views of a nuclear magnetic resonance, where a great occupying lesion can be seen in the intraorbital space (arrow).

headache, diplopia and unilateral exophthalmos, and was evaluated and treated at the Neurology department. A magnetic resonance imaging (MRI) test displayed a cranial space-occupying lesion compatible with right intraorbital or dilated ophthalmic or orbital vein and a partial occupation of the right cavernous sinus. Suspecting a cavernous sinus syndrome, the start of anticoagulation was decided upon with acenocoumarol and testing for hypercoagulability and autoimmunity was carried out, with these findings: aCL IgG and IgM +, ANA + and anti-native DNA+. She was referred to our consultation in September 2007 due to data suggesting an autoimmune disease. The patient reported a history of rhythmic inflammatory polyarthralgia for 2-3 years prior which improved after taking NSAIDs, as well as fever, fatigue and recurrent oral ulcers with an onset 6-7 months prior and a progressive increase of dyspnea in the last two months going to present with mild-moderate efforts to occurring at rest. Physical examination revealed mucocutaneous pallor, right exophthalmos, purpuric lesions on the lower limbs, residual oral ulcers, tachycardia (110 bpm) and synovitis of the wrists. We performed a biopsy of the lesions, and indicated the need for hospitalization to complete her study. The complementary tests revealed microcytic hypochromic anemia with a positive direct antiglobulin test, elevated acute phase reactants, hypocomplementemia, positive ANA with a high titer (>1/320) and positive anti-native DNA, positive IgG and IgM anti-beta 2 glycoprotein antibodies, positive IgG and IgM aCL, a urinary sediment without evidence of renal activity, global cardiac enlargement (cardiothoracic ratio 65%), mild pericardial effusion with severe hypertensive cardiomyopathy, with echocardiography and pulmonary function tests revealing decreased volumes with an obstructive pattern. A skin biopsy was performed and presented dense superficial perivascular and interstitial infiltration by lymphocytes and neutrophils with marked leucocytoclasia of the dermis. Given the persistence of the ocular symptoms and the absence of an accurate diagnosis, we requested a new orbital MRI, which showed a space-occupying lesion compatible with right intraorbital pseudotumor or orbital granulomatous process (Figure). We started 1 mg/kg dose of glucocorticoids which led to a reduction of proptosis and improvement of systemic manifestations. The diagnosis of SLE was confirmed (oral ulcers, positive ANA, positive anti-native DNA, pericarditis, nonerosive arthritis, positive IgG and IgM aCL) and immunosuppressive therapy with cyclophosphamide (CF) (0.75 g/m<sup>2</sup> body surface area, monthly for 6 months) was established. After moving to a quarterly infusion of the drug, the patient presented ophthalmic activity once again, leading to the administration of intravenous glucocorticoids (500 mg×3) for its control. Given the lack of effectiveness of CF in relation to the orbital inflammatory disease, we decided upon compassionate RTX therapy. The first cycle was administered (1g×2), with rapid improvement and complete disappearance of the proptosis in about six weeks after the infusion of the first dose. Six months after the second cycle

was administered, applying the pattern introduced for rheumatoid arthritis due to the absence of specific indications in the literature for this case in particular, leading to excellent clinical control (no proptosis or laboratory tests suggestive of active disease).

## Discussion

Patients with SLE may have a variety of ocular manifestations, the most common being keratoconjunctivitis sicca. The appearance of exophthalmos as a manifestation in patients with SLE is extremely rare, occurring as secondary to orbital pseudotumor in most cases. The first description of orbital pseudotumor dates back to 1905, and was published by Birch-Hirschfeld, who classified it as a non-neoplastic inflammatory entity of unknown etiology in a large percentage of cases. It was composed of partly mature lymphocytes, plasma cells, macrophages and leukocytes, with varying degrees of fibrosis. This inflammatory process can affect the orbital tissues diffusely or specifically leading to different clinical variables: lacrimal gland (dacryoadenitis), muscle (miosistis), Tenon capsule (tenositis) and, less frequently, orbital vessels and nerves affection.<sup>8,9</sup> For its etiologic diagnosis it is necessary to perform a proper history and physical examination and additional laboratory and imaging tests (mainly CT or MRI). Sometimes it is necessary to perform a biopsy of the lesion to determine the underlying pathology.

In patients with unilateral exophthalmos and orbital pseudotumor, one should consider diseases such as Graves' disease, neoplasms, infectious or less common causes such as cavernous sinus thrombosis, amyloid deposition, retrobulbar hematoma, hemangioma, sarcoidosis and histiocytosis in association with connective tissue diseases as part of their differential diagnosis.<sup>9,10</sup>

In connection with treatment, high efficiency has been described with the use of corticosteroids administered as high dose intravenous pulses as induction therapy and half the dose later on as a maintenance dose to prevent recurrence. Immunosuppressants such as azathioprine, CF and antimalarials (chloroquine / hydroxychloroquine) have been used as adjuvants for remission or glucocorticoid-sparing therapy.<sup>9</sup> TNF-inhibiting therapies have been shown to be effective in patients with inflammatory orbital affection resistant to the drugs mentioned above.<sup>11,12</sup> In our case, because the case was a patient with a condition in which the B cell has a predominant role, and the resistance of the ocular problem to treatment with CF, we decided to initiate treatment with a monoclonal antibody directed against CD 20+cells (RTX), with an excellent clinical response and control of ocular symptoms after infusion of the first dose of the drug. This response persisted two months after the infusion of the second full cycle. Although we did not entirely rule out the probability of a lymphoproliferative process, the clinical presentation, with intense and very painful proptosis and conjunctival injection (findings found with greater prevalence in orbital pseudotumors),<sup>18</sup> and the presence of clinical and laboratory data suggesting the diagnosis of SLE, made us decline the possibility of a diagnostic biopsy of the lesion. Experience has shown that the use of RTX in the treatment of patients with SLE resistant to various immunosuppressive drugs, including CF, shows promising results, especially for the control of renal disease in a high percentage of cases.<sup>16,17</sup> There is little evidence for the treatment of orbital inflammatory disease with this molecule in the literature,<sup>13</sup> but in secondary ophthalmopathy due to Graves' disease, it appears to be effective.<sup>14,15</sup> In conclusion, RTX could be an alternative to conventional treatments when they show an insufficient response.

## Disclosures

The authors have no disclosures to make.

## References

1. Serop S, Vianna RN, Claeys M, De Laey JJ. Orbital myositis secondary to systemic lupus erythematosus. *Acta Ophthalmol (Copenh)*. 1994;72:520-3.
2. Bankhurst AD, Carlow TJ, Reidy RW. Exophthalmos in systemic lupus erythematosus. *Ann Ophthalmol*. 1984;6:669-71.
3. Siebert S, Srinivasan U. Proptosis can be the presenting feature of systemic lupus erythematosus. *Ann Rheum Dis*. 2004;63:908-9.
4. Jordan DR, McDonald H, Olberg B, McKim D, McKendy R. Orbital panniculitis as the initial manifestation of systemic lupus erythematosus. *Ophthalm Plast Reconstr Surg*. 1993;9:71-5.
5. Grimson BS, Simons KB. Orbital inflammation, myositis, and systemic lupus erythematosus. *Arch Ophthalmol*. 1983;101:736-8.
6. Feinfield RE, Hesse RJ, Rosenberg SA. Orbital inflammatory disease associated with systemic lupus erythematosus. *South Med J*. 1991;84:98-9.
7. Wildinson LS, Panush RS. Exophthalmos associated with systemic lupus erythematosus. *Arthritis Rheum*. 1975;18:188-9.
8. Snebold NG. Orbital pseudotumor syndromes. *Curr Opin Ophthalmol*. 1997;8:41-4.
9. Gordon LK. Diagnostic dilemmas in orbital inflammatory disease. *Ocul Immunol Inflamm*. 2003;11:3-15.
10. Gray RE, Jenkins EA, Hall MA, Kanski JJ, Ansell BM. Recurrent acute proptosis in atypical systemic lupus erythematosus. *Clin Rheumatol*. 1989;8:528-32.
11. Miquel T, Abad S, Badelon I, Vignal C, Warzocha U, Larroche C, et al. Successful treatment of idiopathic orbital inflammation with infliximab: an alternative to conventional steroid-sparing agents. *Ophthalm Plast Reconstr Surg*. 2008;24:415-7.
12. Kapadia MK, Rubin PA. The emerging use of TNF-alpha inhibitors in orbital inflammatory disease. *Int Ophthalmol Clin*. 2006;46:165-81.
13. Schafranski MD. Idiopathic orbital inflammatory disease successfully treated with Rituximab. *Clin Rheumatol*. 2009;28:225-6.
14. Salvi M, Vannucchi G, Campi I, Currò N, Dazzi D, Simonetta S, et al. Treatment of Graves' disease and associated ophthalmopathy with the anti-CD20 monoclonal antibody rituximab: An open study. *Eur J Endocrinol*. 2007;156:33-40.
15. Salvi M, Vannucchi G, Campi I, Currò N, Beck-Peccoz P. New immunomodulators in the treatment of Graves' ophthalmopathy. *Ann Endocrinol (Paris)*. 2008;69:153-6.
16. Sfikakis PP, Boletis JN, Tsokos GC. Rituximab anti-B-cell therapy in systemic lupus erythematosus: pointing to the future. *Curr Opin Rheumatol*. 2005;17:550-7.
17. Melander C, Sallée M, Trolliet P, Candon S, Belenfant X, Daugas E, et al. Rituximab in severe lupus nephritis: early B-cell depletion affects long-term renal outcome. *Clin J Am Soc Nephrol*. 2009;4:579-87.
18. Yan J, Wu Z, Li Y. The differentiation of idiopathic inflammatory pseudotumor from lymphoid tumors of orbit: analysis of 319 cases. *Orbit*. 2004;23:245-54.