

20 mg/dl, protein of 111 mg/dl, WBC 14 mm³, neutrophils 16%, lymphocytes 84 found %, gram stain + + + yeast and bacterial antigens, with encapsulated blastoconidias found after staining with China ink, compatible with *Cryptococcus* sp. Methotrexate and prednisone were discontinued or decreased. We started treatment with amphotericin B, in increasing doses up to 1 g intravenously, with an adequate clinical response and infection control. Due to the presence of *de novo* diabetes mellitus, treatment with insulin was started based on a recommendation of endocrinology.

Opportunistic CNS infections reported in patients with RA include progressive multifocal encephalopathy, aspergilloma, tuberculosis, infection with West Nile virus, bacterial meningitis, infection with rodococcus and cryptococcal meningitis; however, the patients who have been reported with these types of infection were undergoing biological therapy.^{3–5} Cryptococcal infections reported in RA patients are summarized in Table 1.^{6,8,9} When evaluating Table 1, it can be seen that most cryptococcal infections in patients with RA present in the lungs,¹⁰ followed by skin and meninges; one case showed spreading with multiorgan involvement and deadly consequences. The average age of presentation for any cryptococcal infection is 63.8 years (range: 47–82 years); the most frequently associated drugs are methotrexate and prednisone in 75% of cases. 66% of the patients who developed infections due to this micro-organism were on biological therapy. Of the 3 patients who presented cryptococcal meningitis, only the patient reported in this case was not undergoing biological therapy.

In conclusion, we report a case of cryptococcal meningitis in a patient with RA in non-biological antirheumatic treatment (glucocorticoids and methotrexate).

References

1. Ellis DH, Pfeiffer TJ. Ecology, life cycle, and infectious propagule of *Cryptococcus neoformans*. *Lancet*. 1990;13:923–5.

2. Satishchandra P, Mathew T, Gadre G, Nagarathna S, Chandramukhi A, Mahadevan A, et al. Cryptococcal meningitis: clinical, diagnostic and therapeutic overviews. *Neurol India*. 2007;55:226–32.
3. DaSilva V, Roux CH, Bernard E, Brocq O, Albert C, Chami H, et al. Neuromeningeal tuberculosis in a patient with rheumatoid arthritis previously exposed to ineffective etanercept therapy and revealed by infliximab. *J Rheumatol*. 2010;37:471.
4. Kroot EJ, Demeyere T, van der Linden AN, Visser C, Traksel RA. Intracranial aspergilloma in a patient with rheumatoid arthritis. *Scand J Rheumatol*. 2008;37:233–4.
5. López P, Martín I, del Pino M, Ruano A, Hernández JA, Hervas M. Meningeal and Guillain-Barré syndrome in a patient with rheumatoid arthritis receiving adalimumab therapy. *Reumatol Clin*. 2011;7:401–3.
6. De Bandt M, Delecoeuillerie G, Perronne C, Lepout C, Paolaggi JB. Cryptococcal meningitis in a patient with rheumatoid arthritis. *Presse Med*. 1988;17:592–3.
7. Muñoz P, Giannella M, Valerio M, Soria T, Díaz F, Longo JL, et al. Cryptococcal meningitis in a patient treated with infliximab. *Diagn Microbiol Infect Dis*. 2007;57:443–6.
8. Wingfield T, Jani M, Krutikov M, Mayer J, Uriel A, Marks J, et al. Cryptococcal meningitis in an HIV-negative patient with rheumatoid arthritis treated with rituximab. *Rheumatology (Oxford)*. 2011;50:1725–7.
9. Díaz-Sarrió C, García-Navarro X, Claver-Cercós JM, Baucells-Azcona JM, Martín-Plata C, Corcoy-Grabalosa M. Celulitis diseminada como presentación inicial de criptococcosis sistémica en un paciente con artritis reumatoide. *Actas Dermosifiliogr*. 2010;101:274–5.
10. Lu HC, Yang YY, Huang YL, Chen TL, Chuang CL, Lee FY, et al. Disseminated cryptococcosis initially presenting as cellulitis in a rheumatoid arthritis patient. *J Chin Med Assoc*. 2007;70:249–52.

Ramiro F. Trillos,^a Daniel Gerardo Fernández-Ávila,^{b,*} María C. Díaz,^b Juan M. Gutiérrez^b

^a Departamento de Neurología, Hospital Universitario San Ignacio, Pontificia Universidad Javeriana, Bogotá, Colombia

^b Unidad de Reumatología, Hospital Universitario San Ignacio, Pontificia Universidad Javeriana, Grupo Javeriano de Investigación en Enfermedades Reumáticas, Bogotá, Colombia

* Corresponding author.

E-mail address: danielfernandezmd@gmail.com (D.G. Fernández-Ávila).

Prosthesis Infection by *Mycobacterium tuberculosis* in a Patient With Rheumatoid Arthritis: A Case Report and Literature Review[☆]



Infección protésica por *Mycobacterium tuberculosis* en paciente con artritis reumatoide: reporte de un caso y revisión bibliográfica

To the editor:

Prosthetic knee infection by *Mycobacterium tuberculosis* (MT) is rare.^{1,2} Reviews in 2011 and 2013 found 7 and 15 cases of prosthetic infections due to MT, respectively.^{3–5} Since the introduction of biological treatment for rheumatoid arthritis (RA), there has been an increase in the incidence of infection by MT, mainly in patients treated with antagonists to tumor necrosis factor (anti-TNF).^{6,7} One study showed an MT infection rate of 49 per 100,000 person-years in patients with RA treated with anti-TNF versus 8.7^{6,7} in patients with RA not treated with these agents. Here, we present a case

of prosthetic infection by MT in a patient with RA treated with anti-TNF.

The patient is a 77-year-old woman who had RA treated with methotrexate 7.5 mg/weekly and infliximab (IFX) 3 mg/kg, and a right knee prosthesis. In March 2012 she developed cough, and fever with nightly sweating lasting for 2 months; BK and sputum culture were requested, both negative. She received IFX in May and in June went to a review visit referring multiple respiratory infections during that time. In August she was assessed by Orthopedics, finding fever, pain and swelling of the right knee; discharged with a suspected prosthetic infection (Fig. 1A). In November, she was hospitalized in Internal Medicine (IM) for partial bowel obstruction and was discharged on prednisone 15 mg/day; during admission, a computed tomography (Fig. 1B) was performed, showing a pulmonary nodule indicative of granuloma and chest and retroperitoneal lymphadenopathy. In January 2013 she came to the Rheumatology clinic due to knee pain, and IFX was suspended; she also was assessed by IM, who recommended surgery for the persistent intestinal subocclusion. In April, she was evaluated by General Surgery and operated. Pathologic examination showed necrotizing granulomatous lymphadenitis and necrotizing granulomatous inflammation and ulceration of the mucosa in the small intestine; microbiological study was negative for *Mycobacterium*. Rifater[®] was begun and QuantiFERON[®] performed, which

[☆] Please cite this article as: Egües Dubuc C, Uriarte Ecenarro M, Errazquin Aguirre N, Belzunegui Otano J. Infección protésica por *Mycobacterium tuberculosis* en paciente con artritis reumatoide: reporte de un caso y revisión bibliográfica. *Reumatol Clin*. 2014;10:347–349.

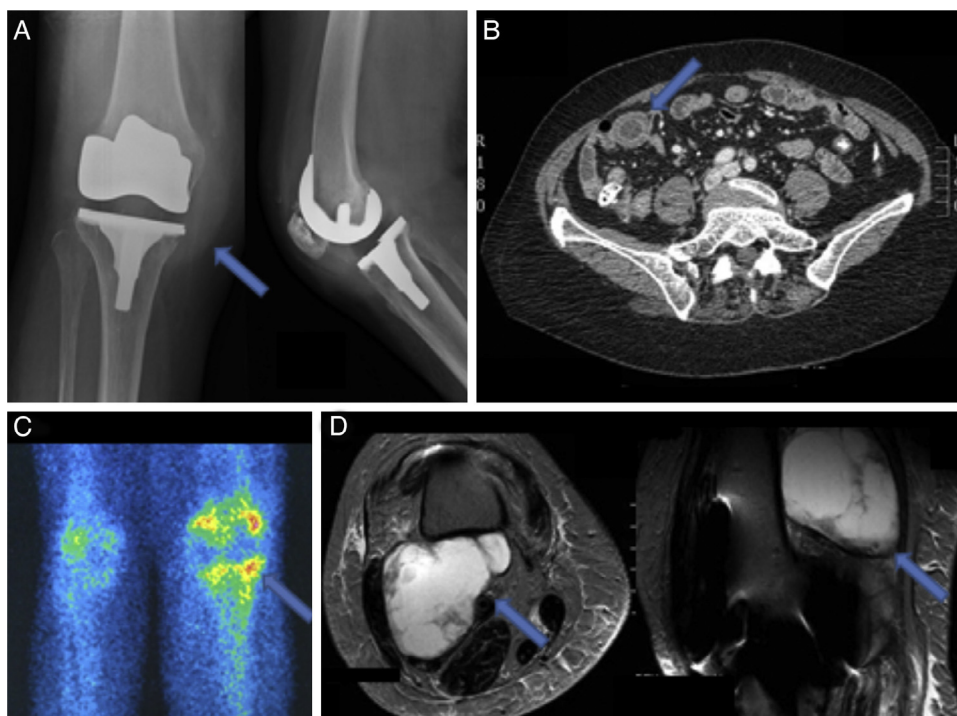


Fig. 1. (A) X-ray of the right knee: increased soft tissue is observed. (B) CT: an increase in thickness can be seen in the wall of the ileum. (C) Technetium and gallium bone scan: increased uptake is seen in the right knee. (D) MRI: a posterior cystic mass is seen on the femur.

was negative. In June, she went to Rheumatology for leg edema and pain in the right knee; Doppler ultrasound was performed, showing a cystic mass of 10 cm, which was drained and analyzed; an MRI was also requested (Fig. 1D). The drained fluid PCR was positive for *Mycobacterium tuberculosis* complex. During this period, the patient had slightly higher acute phase reactants; Orthopedics also performed a scintigraphy, suggestive of periprosthetic infection (Fig. 1C). Currently, Orthopedics dismissed surgery and the patient continues on a tuberculostatic.

Prosthetic infection MT may be a reactivation of a latent focus that reaches the joint by hematogenous or local reactivation.^{8,9} Risk factors for prosthetic infection are: RA or other immunosuppressive conditions, peri- and postoperative joint infections, non-adjacent previous infection, previous surgery on the same joint, prolonged surgery, higher body mass index, postoperative hematoma, advanced age and diabetes mellitus.¹⁰ Risk factors for MT prosthetic infection are: advanced age (>70 years), past MT infection and immunosuppressive conditions.⁵

Treatment usually is medical and surgical; it is recommended to obtain tissue samples or pre-antibiotic liquid; if the patient has a poor clinical condition, we recommend starting vancomycin and cephepime.¹¹ The surgery depends on: etiology, time of the infection presentation from the implantation of the prosthesis and comorbidities. Surgical options include prosthetic replacement (in one or two [the recommended] times), debridement and retention of the prosthesis and prosthetic resection in case a reimplantation is not contemplated.¹¹ A study in patients with RA and prosthetic infection concluded that prosthetic replacement in 2 times has a better prognosis.¹² The choice of surgery in MT infection is controversial for the few cases reported.⁶ 6–9 months of treatment are recommended for osteoarticular tuberculosis (2 months of isoniazid, rifampicin, pyrazinamide and ethambutol, followed by 4–7 months of isoniazid and rifampicin),¹² but can vary

according to the patient characteristics and outcomes between 6 and 24 months.¹¹

This patient had a prosthetic infection secondary to a tuberculosis, but we recommend, according to the literature, a combined treatment: prosthetic replacement in 2-times and 4-tuberculosis drugs for a minimum of 6 months.

Conflict of Interest

The authors have no disclosures to make.

References

- Widmer AF. New developments in diagnosis and treatment of infection in orthopedic implants. *Clin Infect Dis*. 2001;33 Suppl. 2:S94.
- Wang SX, Yang CJ, Chen YC, Lay CJ, Tsai CC. Septic arthritis caused by *Mycobacterium fortuitum* and *Mycobacterium abscessus* in a prosthetic knee joint: case report and review of literature. *Intern Med*. 2011;50:2227–32.
- Neogi DS, Kumar A, Yadav CS, Singh S. Delayed periprosthetic tuberculosis after total knee replacement: is conservative treatment possible? *Acta Orthop Belg*. 2009;75:136–40.
- Berberi EF, Hanssen AD, Duffy MC, Steckelberg JM, Osmon DR. Prosthetic joint infection due to *Mycobacterium tuberculosis*: a case series and review of the literature. *Am J Orthop*. 1998;27:219–27.
- Kim SJ, Kim JH. Late onset *Mycobacterium tuberculosis* infection after total knee arthroplasty: a systematic review and pooled analysis. *Scand J Infect Dis*. 2013;45:907–14.
- Winthrop KL, Baxter R, Liu L, Varley CD, Curtis JR, Baddley JW, et al. Mycobacterial diseases and antitumor necrosis factor therapy in USA. *Ann Rheum Dis*. 2013;72:37–42.
- Salgado E, Gómez-Reino JJ. The risk of tuberculosis in patients treated with TNF antagonists. *Expert Rev Clin Immunol*. 2011;7:329–40.
- Spinner RJ, Sexton DJ, Goldner RD, Levin LS. Periprosthetic infections due to *Mycobacterium tuberculosis* in patients with no prior history of tuberculosis. *J Arthroplasty*. 1996;11:217–22.
- Jämsen E, Nevalainen P, Eskelinen A, Huotari K, Kalliovalkama J, Moilanen T. Obesity, diabetes and preoperative hyperglycemia as predictors of periprosthetic joint infection: a single-center analysis of 7181 primary hip and knee replacements for osteoarthritis. *J Bone Joint Surg Am*. 2012;94:e101.

10. Lentino JR. Prosthetic joint infections: bane of orthopedists, challenge for infectious disease specialists. Clin Infect Dis. 2003;36:1157.
11. Elie FB, Douglas RO, Mary CTD, William Harmsen RN, Mandrekar JN, Hanssen AD, et al. Outcome of prosthetic joint infection in patients with rheumatoid arthritis: the impact of medical and surgical therapy in 200 episodes. Clin Infect Dis. 2006;42:216-23.
12. American Thoracic Society Documents. American Thoracic Society/Centers for Disease Control and Prevention/Infectious Diseases Society of America: treatment of tuberculosis. Am J Respir Crit Care Med. 2003;167:603-62.

César Egües Dubuc,* Miren Uriarte Ecenarro,
Nerea Errazquin Aguirre, Joaquín Belzunegui Otano

*Servicio de Reumatología, Hospital Universitario Donostia,
Guipúzcoa, Spain*

* Corresponding author.

E-mail address: tonoeguesdubuc@hotmail.com (C. Egües Dubuc).