



Sociedad Española
de Reumatología -
Colegio Mexicano
de Reumatología




Image in Clinical Rheumatology

Multicentric reticulohistiocytosis: A 20-year diagnosis beneath the surface

Reticulohistiocitosis multicéntrica: un diagnóstico oculto durante 20 años

David Fernández-Fernández^{a,*}, Ivonne Lourdes Mamani-Velarde^a, Maritza Tatiana Segarra-Ortega^a, José María Pego-Reigosa^{a,b}

^a Servicio de Reumatología, Complejo Hospitalario de Vigo, Pontevedra, Spain

^b Grupo IRIDIS (Investigation in Rheumatology and Immune-mediated Diseases), Instituto de Investigación Sanitaria Galicia Sur, Vigo, Pontevedra, Spain

Case presentation

A 65-year-old Caucasian male consulted for the appearance of nodular skin lesions in form of firm, raised bumps with a red-brown and yellowish hue on the dorsal surface of the hands, forearms (Fig. 1a) and nasal region. He was followed in rheumatology outpatient clinic for 20 years with chronic erosive seronegative polyarthritis with erosions affecting mainly Distal Interphalangeal (DIP) joints (Fig. 1b). A combined therapy with methotrexate 20 mg plus etanercept 50 mg weekly was established with complete clinical remission at the onset of the lesions. A skin and metacarpophalangeal biopsy were performed. A proliferation of cells with a wide eosinophilic cytoplasm and the presence of multinucleated giant cells (Fig. 1c) was observed. The immunohistochemical analysis reveals that the cells express CD45, CD68, CD11b, and HAM-56, but not the S100 or CD1a protein, compatible with histiocytosis.

Diagnosis

Multicentric reticulohistiocytosis (MRH) with joint and disseminated skin involvement was diagnosed.

Evolution

Cutaneous lesions improved spontaneously in three weeks. Eighteen months later, only a few lesions were seen on the forearms and dorsum of the hands. Due to the spontaneous improvement and the absence of impact on the patient's life, no modification of therapy was considered, and the previous treatment was maintained. No another involvement was referred in the follow-up. A PET-scan was considered to rule out malignancy, but the patient died prior the scheduled date due a respiratory sepsis.

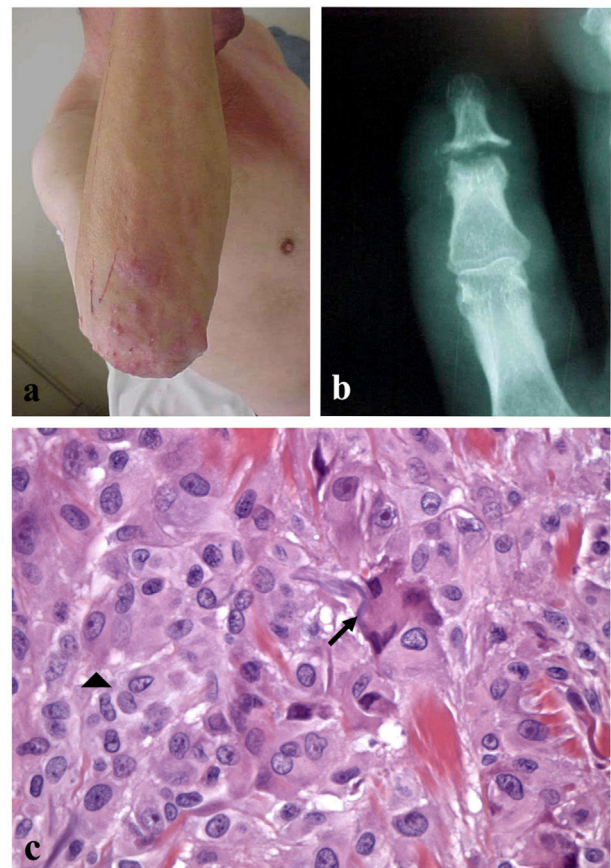


Fig. 1.

* Corresponding author.

E-mail address: David.fernandez.fernandez@sergas.es (D. Fernández-Fernández).

Discussion

Multicentric reticulohistiocytosis (MRH) is a rare idiopathic systemic inflammatory disease characterized by a tissue infiltrate of

non-Langerhans histiocytic cells primarily in joints and skin but also affecting other organ systems.¹ The disease often presents insidiously, beginning with articular symptoms and developing skin manifestations after a few months or even years. To our knowledge no report with such a long interval between articular and dermatological manifestations as in our patient (twenty years) has been described.² This case, with an unusual lag between the presence of erosive joint involvement and the presence of skin lesions, highlights the importance of considering this entity in the differential diagnosis of patients with erosive joint lesions, predominantly in distal interphalangeal joints.

Authors' contributions

All authors contributed equally to the data collection, analysis, and writing of the manuscript.

Patient consent

The patient has provided informed consent for the publication of this case and the associated images.

Conflict of interests

The authors declare that they have no competing interests.

Acknowledgements

We thank Dr. Carmen Fachal Bermudez from the Pathology Service of the Complejo Hospitalario Universitario de Vigo for her collaboration in the diagnosis of this case.

References

1. Ashaolu O, Ng S, Smale S, Hughes J. Multicentric reticulohistiocytosis – a rare and disabling disease. *Clin Case Rep.* 2023;11:e7846, <http://dx.doi.org/10.1002/ccr3.7846>. Published 2023 Aug 27.
2. Fujii Y, Hasegawa M, Yano K, Fukuda T. Multicentric reticulohistiocytosis: a case report and review of the literature. *Dermatol Online J.* 2020;26, 13030/qt8bm224b1.