

Case Report

Coincidence of Tuberous Sclerosis and Systemic Lupus Erythematosus—A Case Report[☆]



Carmen Carrasco Cubero,^{a,*} Verónica Bejarano Moguel,^b M. Ángeles Fernández Gil,^c
Jose Luis Álvarez Vega^a

^a Servicio de Reumatología, Hospital Perpetuo Socorro, Complejo Hospitalario Universitario de Badajoz, Badajoz, Spain

^b Centro de Salud San Fernando, Badajoz, Spain

^c Servicio Radiodiagnóstico, Hospital Perpetuo Socorro, Complejo Hospitalario Universitario de Badajoz, Badajoz, Spain

ARTICLE INFO

Article history:

Received 24 April 2015

Accepted 7 August 2015

Available online 26 May 2016

Keywords:

Systemic lupus erythematosus

Tuberous sclerosis

Mammalian target of rapamycin

ABSTRACT

Tuberous sclerosis, also called Bourneville Pringle disease, is a phakomatosis with potential dermal, nerve, kidney and lung damage. It is characterized by the development of benign proliferations in many organs, which result in different clinical manifestations. It is associated with the mutation of two genes: TSC1 (hamartin) and TSC2 (tuberin), with the change in the functionality of the complex target of rapamycin (mTOR). mTOR activation signal has been recently described in systemic lupus erythematosus (SLE) and its inhibition could be beneficial in patients with lupus nephritis.

We report the case of a patient who began with clinical manifestations of tuberous sclerosis complex (TSC) 30 years after the onset of SLE with severe renal disease (type IV nephritis) who improved after treatment with iv pulses of cyclophosphamide.

We found only two similar cases in the literature, and hence considered the coexistence of these two entities of great interest.

© 2015 Elsevier España, S.L.U. and Sociedad Española de Reumatología y Colegio Mexicano de Reumatología. All rights reserved.

Asociación lupus eritematoso sistémico y esclerosis tuberosa, un caso

RESUMEN

La esclerosis tuberosa (ET), también llamada enfermedad de Pringle Bourneville, es una facomatosis con posible afectación dérmica, neurológica, renal y pulmonar. Se caracteriza por el desarrollo de proliferaciones benignas en numerosos órganos, que dan lugar a las diferentes manifestaciones clínicas. Se asocia a la mutación de 2 genes: TSC1 (hamartina) y TSC2 (tuberina), con la alteración funcional del complejo diana de la rapamicina (mTOR). La activación de la señal mTOR ha sido descrita recientemente en el lupus eritematoso sistémico (LES), y su inhibición podría resultar beneficiosa en pacientes con nefritis lúpica. Presentamos el caso de una paciente que 30 años después del inicio de LES con afectación renal grave (glomerulonefritis tipo IV), resuelta con pulsos intravenosos de ciclofosfamida, comenzó con manifestaciones clínicas del complejo esclerosis tuberosa (CET).

Consideramos de interés la coexistencia de estas 2 entidades, ya que solo hemos encontrado 2 casos similares en la literatura.

© 2015 Elsevier España, S.L.U. y

Sociedad Española de Reumatología y Colegio Mexicano de Reumatología. Todos los derechos reservados.

Palabras clave:

Lupus eritematoso sistémico

Esclerosis tuberosa

Complejo diana de la rapamicina

Introduction

The tuberous sclerosis complex (TSC) is an autosomal dominant disease, with variable expression and multisystem involvement, characterized by the growth of benign tumors referred to as hamartomas (neurofibromas and angiofibromas). The organs most

[☆] Please cite this article as: Carrasco Cubero C, Bejarano Moguel V, Fernández Gil MÁ, Álvarez Vega JL. Asociación lupus eritematoso sistémico y esclerosis tuberosa, un caso. Reumatol Clin. 2016;12:219–222.

* Corresponding author.

E-mail address: mcarrascocubero@gmail.com (C. Carrasco Cubero).

frequently affected are brain, skin, kidneys, eyes, heart and lungs. The symptoms of TS may be present at birth or appear at later ages. The severity of the disorder varies widely, ranging from mild forms to severely disabling disease.

The prevalence ranges between 1/6000 and 1/10 000 live births¹. It is the result of the mutation of 1 of 2 genes, *TSC1* (encoding hamartin) or *TSC2* (encoding tuberlin), which leads to a change in the mammalian target of rapamycin (mTOR), characterized by continuous and deficient activation. A possible role of the alteration of the mTOR complex in the pathogenesis of systemic lupus erythematosus (SLE) has also been reported. As the mTOR pathway has been found to be activated in SLE, its inhibition would benefit patients with lupus nephritis.

Patients with TSC would have a high risk of developing SLE, since the mTOR pathway plays a key role in T cells and can activate autoimmunity.² Moreover, using rapamycin to block the mTOR signal has been effective in the treatment of SLE in humans.³ However, to our knowledge, only 2 cases of the association of TSC and SLE have been reported.^{4,5} Both patients were young women diagnosed with TS, who subsequently developed SLE with severe renal

involvement. One died, after experiencing seizures and developing sepsis, gastric bleeding and diffuse alveolar hemorrhage during treatment to induce remission.⁵ The authors describing the latter case suggest that the activation of mTOR by the mutations involved in TSC might have led to the activation of the immune system and to the development of severe SLE. In contrast, although our patient's disease presented with the signs and symptoms of SLE and severe lupus nephritis, her outcome was favorable and she has achieved complete remission of her renal condition.

Case Report

The patient was a 47-year-old woman who, at the age of 14 years, had been diagnosed with SLE on the basis of joint disease (polyarthritis), accompanied by mucocutaneous (aphthous stomatitis, malar rash and photosensitivity), renal (nephrotic syndrome) and hematologic (hemolytic anemia, leukopenia, lymphopenia) manifestations, hypocomplementemia and serological evidence (antinuclear antibody titer, 1:2560 [homogeneous pattern], anti-DNA antibody level, 62 IU/mL). The renal involvement

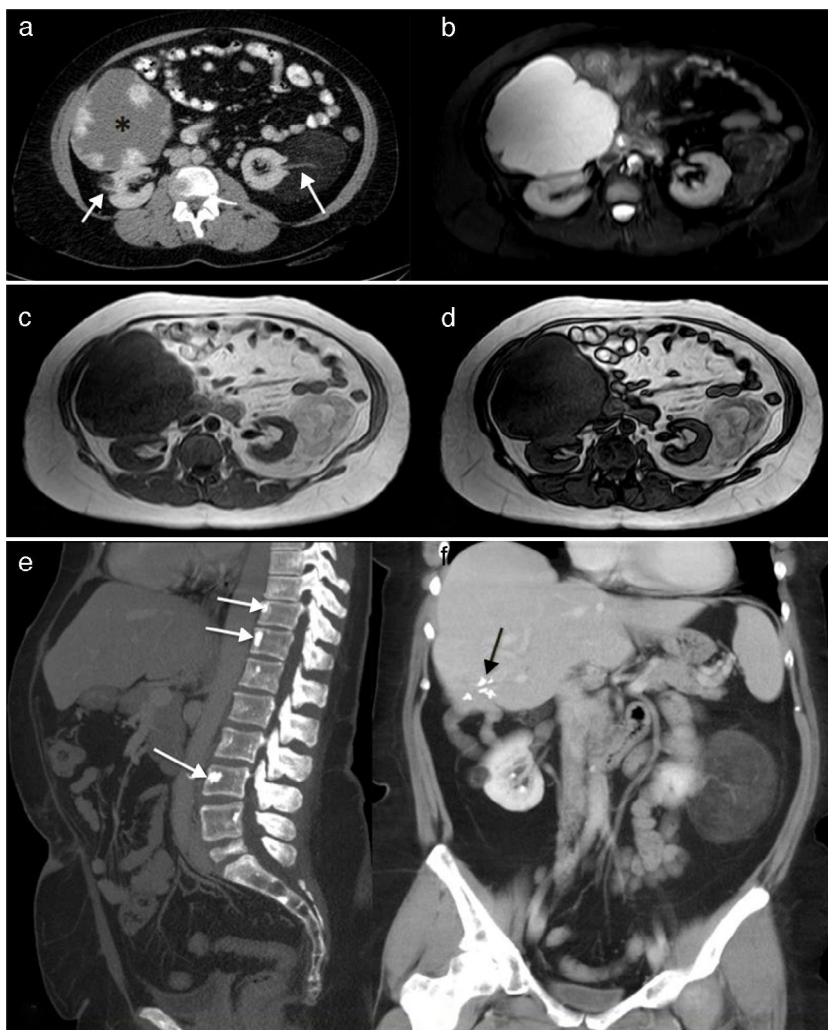


Fig. 1. (a) Renal computed tomography (CT) showing a giant hepatic hemangioma (*) and bilateral low-density renal angiomyolipomas, similar to fat and the vascular pedicle (arrows). (b) Axial short-tau inversion recovery (STIR) images. The hepatic hemangioma is markedly hyperintense and the renal angiomas show low signal intensity with a few hyperintense areas on the left that represent the tumor vascularization. (c and d) T1-weighted gradient echo images in phase and reversed phase, respectively, showing the left renal angiomyolipomas with an intensity similar to fat, and hypointense areas in its interior that correspond to the vascular structures. The reversed phase image (d) shows that the signal of part of the tumor is canceled out because of the fat content. (e) Sagittal maximal intensity projection (MIP) reconstruction of CT images, showing a few vertebral bodies corresponding to bone islands (arrows). (f) Coronal MIP reconstruction of CT images. The hepatic hemangioma has been resected and the black arrows indicate the clips that remained after surgery. The 2 renal angiomyolipomas are clearly seen.

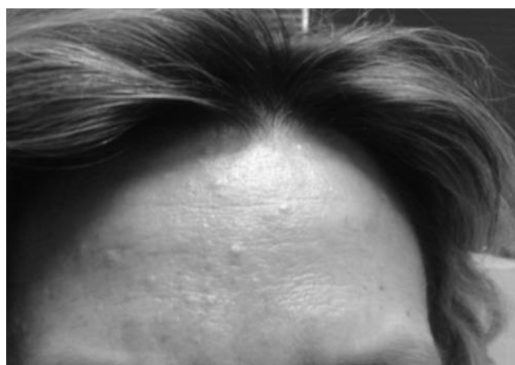

Fig. 2. Facial angiofibromas.

was defined by biopsy as diffuse proliferative glomerulonephritis (World Health Organization type IV). She was treated with high-dose glucocorticoids (1 mg/kg/day) and 6 cyclophosphamide pulses/month (750 mg/m² body surface area) to induce remission, followed by 1 cyclophosphamide pulse every 3 months for 2 years, with no complications. Since then, the patient has continued to take hydroxychloroquine and low-dose glucocorticoids. Her renal function has remained normal, and she has had no further serious manifestations of SLE or significant laboratory abnormalities, including complement levels and cell counts. She still tests positive for antinuclear antibodies, at a titer of 1:640, and has an anti-double-stranded DNA antibody level (enzyme-linked immunosorbent assay [ELISA]) of 18 IU/mL (slightly over the upper normal limit of 15 IU/mL).

A biopsy of the skin lesions performed in 2000 was consistent with pigmented dermatofibromas.

In February 2012, at the age of 44 years, with nothing notable in her obstetric history (no miscarriages and a normal pregnancy and delivery of a healthy daughter), she presented with heavy intermenstrual bleeding secondary to uterine myomas. Bilateral renal angiomyolipomas, a large hepatic hemangioma, rectal polyps and bone islands in axial skeleton were incidental findings on imaging studies (Fig. 1).

The presence of renal angiomyolipomas, together with facial angiofibromas (Fig. 2), 2 of the major criteria, led to the diagnosis of TSC; in addition, the patient had multiple dental enamel pits, hamartomatous rectal polyps and bone cysts (the latter being considered minor criteria), resulting in a definitive diagnosis according to the criteria for TSC (Table 1).⁶ She has never had seizures or other neurological manifestations. Since the diagnosis, she is being treated with everolimus and has not experienced any secondary effects or worsening of SLE.

Discussion

Our patient, like the 2 whose cases have been published to date,^{4,5} presented with severe renal involvement (diffuse proliferative glomerulonephritis) as the initial manifestation of SLE.

Table 2

Summary of the Major Features of the Three Cases.

Case	Diagnosis of SLE	Diagnosis of TSC	Nephritis (WHO)	Treatments	Outcome
Singh, ⁵ 2013	Woman, 22 years	Childhood (prior to SLE [*])	IV	Cyclophosphamide Plasmapheresis	Death (sepsis and respiratory failure)
Katada, ⁴ 2012	Woman, 26 years	Childhood (prior to SLE [*])	IV	Prednisolone	Clinical and biological monitoring
Case reported here	Woman, 14 years	Adult (30 years after SLE)	IV	Methylprednisolone Cyclophosphamide	Clinical and biological monitoring

SLE, systemic lupus erythematosus; TSC, tuberous sclerosis complex; WHO, World Health Organization.

* The exact age at which TSC was diagnosed is unknown.

Table 1

Diagnostic Criteria Corresponding to Tuberous Sclerosis Complex (TSC)⁶

Major criteria	Minor criteria
1. Facial angiofibromas or frontal plaque	1. Multiple dental enamel pits
2. Nontraumatic unguinal and periungual fibromas	2. Hamartomatous rectal polyps (histological confirmation)
3. Hypomelanotic macules (3 or more)	3. Bone cysts (radiological confirmation)
4. Shagreen patch	4. Migratory pathways in cerebral white matter ^{**}
5. Multinodular retinal hamartomas	5. Gingival fibromas
6. Cortical tubers	6. Nonrenal hamartoma (histological confirmation)
7. Subependymal nodules	7. Retinal achromic patch
8. Giant cell subependymal astrocytoma	8. "Confetti-like" skin lesions
9. Single or multiple cardiac rhabdomyomas	9. Multiple renal cysts (histological confirmation)
10. Pulmonary lymphangiomyomatosis [*]	
11. Renal angiomyolipoma [*]	

Definitive diagnosis of TSC: 2 major criteria or 1 major and 2 minor criteria.

Probable diagnosis: 1 major and 1 minor criterion.

Possible diagnosis: 1 major criterion or 2 or more minor criteria.

* When these 2 criteria are met, other factors related to tuberous sclerosis complex (TSC) must be present in order to establish a definitive diagnosis.

** When cerebral cortical dysplasia and migratory pathways in cerebral white matter are both present, they should be counted as a single criterion rather than 2 separate criteria for TSC.

Whereas the diagnosis of TSC preceded that of SLE in the other 2 cases, in ours, the clinical signs of TSC were detected 30 years after the diagnosis of SLE. Table 2 summarizes the major features of the 3 cases.

Singh et al.⁵ reported a case of the association TSC/SLE with a catastrophic outcome due to serious complications (seizures, diffuse alveolar hemorrhage, sepsis, etc.). According to the authors, the development of SLE in a patient with TSC, with activation of mTOR signaling, could produce an especially aggressive form of SLE, like that of the patient they describe. They suggest that, as a result of the altered mTOR signaling pathway, patients with TSC may have undetected autoimmunity and should undergo antinuclear antibody testing.

No genetic study was performed in the case we report. A definitive diagnosis of TSC was established because the patient met the clinical criteria (2 major and 3 minor criteria). The genetic criteria are not indispensable for the diagnosis.

The expressivity of TSC is highly variable, meaning that the manifestations and patient age at onset can differ widely.

On the other hand, we were unable to study the aforementioned gene sequences or their possible mutations to demonstrate the mechanisms that may have led to the association of the 2 diseases. However, despite the serious, florid manifestations of the 2 conditions observed in our patient, her course has been stable and she has responded well to conventional therapies, as also appears to have occurred in the case reported by Katada et al.⁴

Conclusion

The functional alteration of mTOR that occurs in TSC as a consequence of mutations in the *TSC1* or *TSC2* gene may play a role in the pathogenesis of SLE. Thus, we recommend that patients with TSC be tested for antibodies. The pathogenesis of SLE is complex and the coexistence of TSC does not necessarily imply a greater severity of SLE.

Ethical Disclosures

Protection of human and animal subjects. The authors declare that no experiments were performed on humans or animals for this study.

Confidentiality of data. The authors declare that they have followed the protocols of their work center on the publication of patient data.

Right to privacy and informed consent. The authors declare that no patient data appear in this article.

Conflicts of Interest

The authors declare they have no conflicts of interest.

References

1. Northrup H, Krueger DA. Tuberous sclerosis complex diagnostic criteria update: recommendations of the 2012 International Tuberous Sclerosis Complex Consensus Conference. *Pediatr Neurol.* 2013;49:243–54.
2. Fernandez D, Perl A. mTOR signaling: a central pathway to pathogenesis in systemic lupus erythematosus? *Discov Med.* 2010;9:173–8.
3. Fernandez D, Bonilla E, Mirza N, Niland B, Perl A. Rapamycin reduces disease activity and normalizes T cell activation-induced calcium fluxing in patients with systemic lupus erythematosus. *Arthritis Rheum.* 2006;54:2983–8.
4. Katada Y, Maeda Y, Yoshimura M, Watanabe A, Katayama M, Tanaka E, et al. Coincidence of tuberous sclerosis and systemic lupus erythematosus. *Mod Rheumatol.* 2012;22(suppl 2012):s155.
5. Singh N, Birkenbach M, Caza T, Perl A, Cohen PL. Tuberous sclerosis and fulminant lupus in a young woman. *J Clin Rheumatol.* 2013;19:134–7.
6. Crino PB, Nathanson KL, Henske EP. The tuberous sclerosis complex. *N Engl J Med.* 2006;355:1345–56.