

Images in clinical rheumatology

Lumbar myositis associated with *Toxocara* spp. infection

Miositis lumbar asociada a infección por *Toxocara* spp

Anne-Pauline Bellanger^{a,b,*}, Michel Runge^c, Daniel Wendling^d, Philippe Humbert^{e,f}

^a Department of Parasitology-Mycology, University Hospital, Besançon, France

^b CNRS-University of Franche-Comte/UMR 6249 Chrono-environnement, Besançon, France

^c Department of Radiology, University Hospital, Besançon, France

^d Department of Rheumatology, University Hospital, Besançon, France

^e Department of Dermatology, University Hospital, Besançon, France

^f SFR FED 4234 IBCT Cell and Tissue Engineering and Biology, INSERM U 1098, University of Franche-Comte, Besançon, France

A 67-year-old male patient presented with acute thoraco lumbar and right trochanteric pain at the consultation of Rheumatology. The patient could not sleep due to the pain, mostly localized in the right iliac crest but irradiating to the trochanter. Pain was aggravated by pressure, right side-lying and seating postures. Magnetic resonance imaging of the spine revealed a lumbar myositis, with T2 high signals in the paraspinal muscles (L3–L4 area) (Fig. 1). There was no cutaneous eruption, no neck stiffness, no biologic inflammatory syndrome, no biologic sign of muscular lysis and no hypereosinophilia. Results of immunological investigations including complement fractions explorations, rheumatoid factor dosage and cryoglobulins detection, were negative. Results of serum antibody tests for *Borrelia burgdorferi*, *Coxiella burnetii* and *Treponema pallidum* were also negative. In contrast, the *Toxocara canis* serologic tests were strongly positive by both *Toxocara* enzyme-linked Immunosorbent assay and *Toxocara* Western blot assays. The patient did not have a dog but was living in a rural area

and reported frequent contacts with soil. Pains disappeared rapidly after 4 days of albendazole treatment. Six months later, the patients relapsed with similar symptoms in intensity and location; the pains disappeared again after 4 days of albendazole treatment.

Human toxocarasis is a widespread soil-transmitted parasitic disease. Principal risk factors include contact with dogs and soil and residence in a rural region.^{1,2} After ingestion *Toxocara* spp. embryonated eggs hatch in the intestines and the larvae migrate via the blood circulation to the liver, lungs and left heart, from where they disseminate via the systemic circulation to eyes, brain or muscles.^{1,2} *Toxocara* spp. infections are highly pleiomorphic, depending on the number and location of encysted larvae in the body and the immune sensitivity of the host.

Definitive diagnosis of toxocarasis would require identification of larvae in human tissues such as skin biopsies, but this is rarely achieved. Besides, as *Toxocara* spp. infection is a parasitological dead-end, neither adult roundworms nor eggs can be found

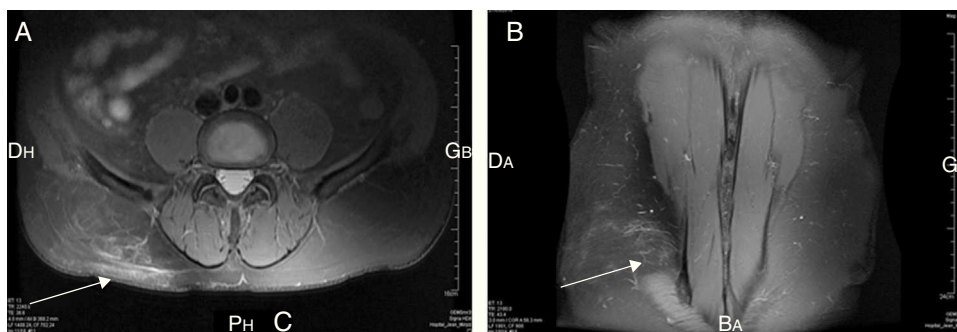


Fig. 1. Axial and coronal planes of the patient's MRI, both showing T2-Fat saturation high signals in intramuscular structures. (A) Axial plane. (B) Coronal plane.

* Corresponding author.

E-mail addresses: apbellanger@chu-besancon.fr, apbellanger@gmail.com (A.P. Bellanger).

in stools to make a direct diagnosis. Consequently, the diagnosis is usually made on the basis of serologic tests results. Two types of tests are available for the immunodiagnosis of toxocariasis: the ELISA and Western blot (WB), both using *T. canis* excretory-secretory antigens (TES). WB is the more sensitive and specific of the two assays.^{3,4}

Amongst all available drugs, albendazole, is the most commonly used and treatment of choice because its reaches higher serum levels, is well-tolerated and better absorbed outside the gastrointestinal tract.^{2,5} Repeated courses of anthelmintic treatments may be necessary to eliminate definitely the symptoms.^{6,7} Pharmacological treatment must be accompanied by prevention of recontamination by deworming dogs and sanitary education.^{1,6}

Ethical disclosures

Protection of human and animal subjects. The authors declare that no experiments were performed on humans or animals for this investigation.

Confidentiality of data. The authors declare that no patient data appears in this article.

Right to privacy and informed consent. The authors declare that no patient data appears in this article.

Conflicts of interest

The authors have no conflicts of interest to declare.

References

1. Magnaval JF, Glickman LT, Dorchie P, Morassin B. Highlights of human toxocariasis. *Korean J Parasitol.* 2001;39:1–11.
2. Pawlowski Z. Toxocariasis in humans: clinical expression and treatment dilemma. *J Helminthol.* 2001;75:299–305.
3. Magnaval JF, Fabre R, Maurieres P, Charlet JP, de Larrard B. Application of the western blotting procedure for the immunodiagnosis of human toxocariasis. *Parasitol Res.* 1991;77:697–702.
4. Bellanger AP, Humbert P, Gavignet B, Deschaseaux AD, Barisien C, Roussel S, et al. Comparative assessment of enzyme-linked immunosorbent assay and Western blot for the diagnosis of toxocariasis in patients with skin disorders. *Br J Dermatol.* 2010;162:80–2.
5. Vidal JE, Sztajnbock J, Seguro AC. Eosinophilic meningoencephalitis due to *Toxocara canis*: case report and review of the literature. *Am J Trop Med Hyg.* 2003;69:341–3.
6. Caumes E. Treatment of cutaneous larva migrans and *Toxocara* infection. *Fundam Clin Pharmacol.* 2003;17:213–6.
7. Menat C, Degouy A, Demoly P, Humbert P, Jacquet M, Woronoff-Lemsi MC. Focus of treatment of toxocariasis. *J Pharm Clin.* 2000;19:194–8.