



Sociedad Española
de Reumatología -
Colegio Mexicano
de Reumatología

Reumatología Clínica

www.reumatologiaclinica.org



Case Report

Unusual presentations and pitfalls of secondary syphilis: Periosteitis, tenosynovitis and hepatic abnormalities

Diana Rosa-Gonçalves*, Miguel Bernardes y Lúcia Costa

Rheumatology Department of Centro Hospitalar São João (CHSJ), Oporto, Portugal

INFORMACIÓN DEL ARTÍCULO

Historia del artículo:

Recibido el 31 de enero de 2017

Aceptado el 8 de marzo de 2017

On-line el 3 de junio de 2017

Keywords:

Syphilis infection

Periosteitis

Bone pain

Tenosynovitis

ABSTRACT

We herein describe two cases of secondary syphilis in patients with human immunodeficiency virus (HIV) infection with an unusual presentation, a diffuse polyostotic periosteitis. Patients referred mainly intense bone pain. Other relevant aspects of the clinical pictures were flexor tenosynovitis and hepatic abnormalities. Given the persistence of symptoms, the treatment duration performed was different from most described in literature. However, although more slowly than expected, both obtained a favorable clinical response after treatment with benzathine penicillin G.

© 2017 Elsevier España, S.L.U. and Sociedad Española de Reumatología y Colegio Mexicano de Reumatología. All rights reserved.

Presentaciones poco comunes y peligros de la sífilis secundaria: periosteitis, tenosinovitis y anomalías hepáticas

RESUMEN

Presentamos 2 casos de la sífilis secundaria en pacientes con infección por el virus de la inmunodeficiencia humana (VIH) con una presentación inusual, una periosteitis difusa polioestótica. Los pacientes han reportado principalmente al dolor óseo intenso. Otros aspectos relevantes de los cuadros clínicos fueron tenosinovitis y anomalías hepáticas. Dada la persistencia de los síntomas, la duración del tratamiento realizado ha sido diferente de la mayoría de los descritos en la literatura. Sin embargo, aunque más lentamente de lo esperado, ambos han obtenido una respuesta clínica favorable después del tratamiento con benzatina penicilina G.

© 2017 Elsevier España, S.L.U. y Sociedad Española de Reumatología y Colegio Mexicano de Reumatología. Todos los derechos reservados.

Palabras clave:

Infección de la sífilis

Periosteitis

Dolor óseo

Tenosinovitis

Introduction

Syphilis is a sexually transmitted disease caused by the spirochete *Treponema pallidum* and remains a global problem, with an estimated 12 million people infected every year.¹ Since the beginning of the 21st century, syphilis incidence has started to rise in high-income settings, in part driven by increases in cases among men who have sex with men, although more recent increases among heterosexual people have also been reported.¹ Most

cases of venereal syphilis are acquired through direct sexual contact with lesions of an individual who has active primary or secondary syphilis, and transmission occurs in approximately half of such contacts.¹

Musculoskeletal manifestations can be associated with congenital, secondary, and tertiary syphilis and can mimic a wide variety of rheumatic and systemic diseases of worse prognosis. Bone involvement is common in treponemal infections and is a usual finding in congenital syphilis. However, bone disease is considered rare, although well known, in acquired syphilis.²

We report two cases of secondary syphilis in patients with human immunodeficiency virus (HIV) infection that is presented as polyostotic periosteitis.

* Corresponding author.

Correo electrónico: di9.goncalves@hotmail.com (D. Rosa-Gonçalves).

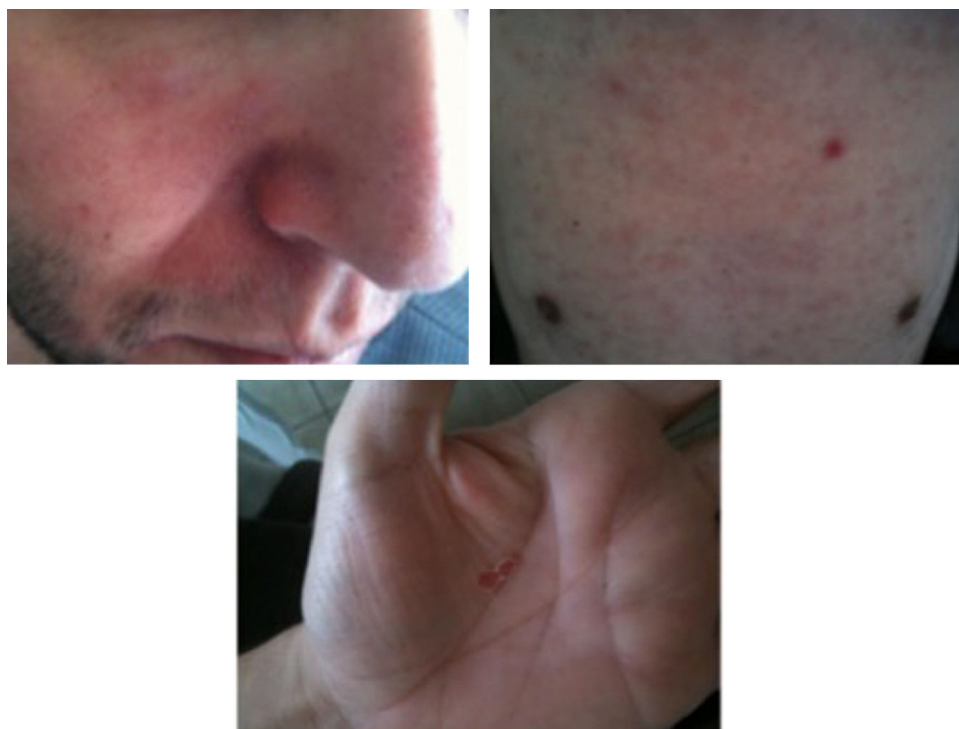

Fig. 1. Generalized macular and maculopapular skin rash.

Case report

The first case, a 40-year-old caucasian man without any significant past medical history, was initially observed due to a two months history of persistent pain at the anterior aspect of the left shin and forearm, which worsens at night. He also reported loss of appetite, weight loss, malaise and fever. Subsequently pain involved additional locations. Patient denied risk behaviors, recent travel or any sick contacts. Was under maximum dose of paracetamol 500 mg + codeine 30 mg without any improvement.

On physical examination, he exhibited a generalized macular and maculopapular skin rash, including palms and soles (Fig. 1). Significant pain on palpation of the left shin and ulnar bone was found. Multiple lymph nodes could be palpated around his neck and inguinal region. No other relevant changes were found.

Laboratory tests results were significant for a normal complete blood count and raised values of: erythrocyte sedimentation rate (ESR) (113 mm, 1st hour); C-reactive protein (CRP) (56.3 mg/L); gamma-glutamyl transferase (GGT) (501 U/L), alkaline phosphatase (AP) (321 U/L), aspartate aminotransferase (AST) (99 U/L); gamma globulins 4.24 g/L (42%); IgG (5040 mg/dl) and β 2-microglobulin (4657 μ g/l). Serum levels of creatinine, calcium and uric acid levels were normal, as was the routine urinalysis. Bone X-rays revealed periosteal reaction of the tibiae, fibulae and ulnar bones. Bone scintigraphy was impressive for bilateral, extensive polyostotic uptake within the skull, and humeral, ulnar, tibiae and fibulae diaphysis (Fig. 2). Patient was admitted to our service with suspicion of multiple myeloma. Other tumor markers were negative and urine light-chain concentrations were undetectable. Several febrile peaks (max. 39.1 °C) were registered. No pain relief was observed under buprenorfine 52.5 mcg/h and fentanyl 200 mcg in SOS. Computed tomography (CT) cervico-thoraco-abdominal-pelvic showed hepatomegaly and multiple cervical, thoracic, abdominal, pelvic and inguinal adenopathy suggestive of a lymphoproliferative disorder. Cranial radiography revealed changes suggestive of lytic lesions, subsequently excluded by CT scanning. Biopsy of lymph node and bronchoscopy revealed no

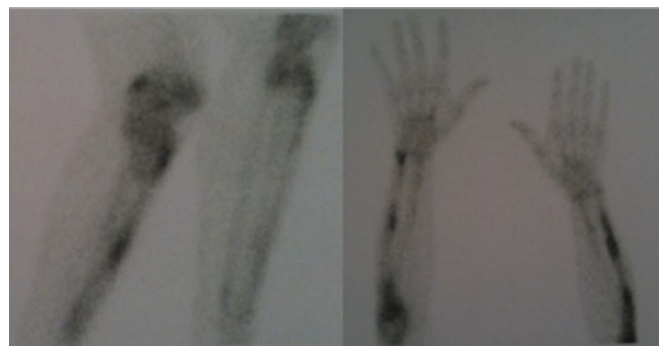


Fig. 2. Bone scintigraphy extensive polyostotic uptake.

significant changes. Serum immunofixation showed polyclonal gammopathy and myelogram was not compatible with lymphoproliferative disease. Serology results were as follows: reactive *treponema pallidum* particle agglutination assay (TPPA) with a venereal diseases research laboratory (VDRL) titer of 1/128; positive HIV (CD4: 444/mm³) and serology compatible with cured hepatitis B. A diagnosis of secondary syphilis with polyostotic periostitis was assumed. He started treatment with penicillin G benzathine 2.4 million units intramuscularly (IM) each at weekly intervals for 3 weeks. After the first dose of penicillin we observed resolution of the rash. Only at this time, the patient revealed his homosexual behavior. After discharge and at 6 months of follow-up he showed significant improvement in pain complaints. The VDRL titer was down to 1/4 and CRP, GGT and AP values returned to normal. Bone scintigraphy showed periostitis in subacute phase at tibiae diaphysis and chronic phase in other locations (Fig. 3). At 12 months, patient was practically asymptomatic and all bone scintigraphy abnormalities were in chronic phase.

The second case refers to a 58-years-old caucasian, homosexual man, with known HIV infection for the past 23 years (viral load undetectable; CD4: 657/mm³) on antiretroviral therapy. It was

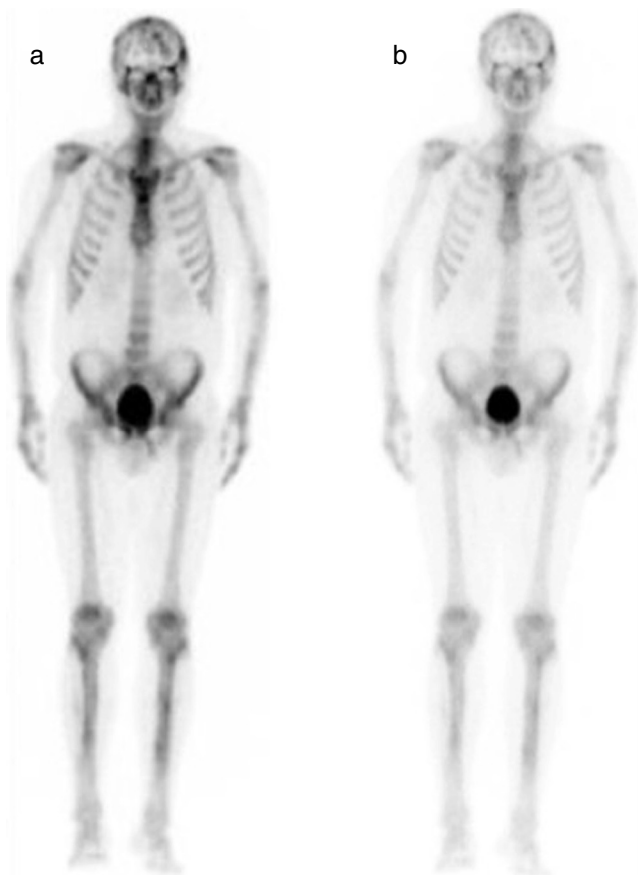


Fig. 3. Scintigraphy at presentation (a) and at 6-month (b) blood pool phase.

admitted to the Infectious Diseases service by severe pain in the shins and forearms with five months of evolution. Pain worse at night and was accompanied by daily episodes of throbbing holo-cranial headache, asthenia, loss of appetite and weight loss. He was under maximum dose of tramadol 37.5 mg + acetaminophen 325 mg without any improvement. No other relevant epidemiological data.

Initial analytic workup was significant for raised values of: ESR (46 mm, 1st hour); CRP (5.1 mg/L), GGT (991 U/L), AP (310 U/L) and β 2-microglobulin (5035 μ g/l). Bacteriological and mycological examination of cerebrospinal fluid (CSF) were negative; fluorescent treponemal antibody absorption (FTA-ABS) test in CSF was positive but VDRL in CSF was negative (had previous diagnosis of syphilis and appropriate response to therapy). The last serum screening was performed about 10 months earlier, which showed reactive TPHA with negative VDRL.

Skeletal X-rays showed changes consistent with lytic lesion in the left frontal cranial bone. CT scan of the lower limbs revealed permeative pattern lesion in the cortical of tibiae diaphysis and middle third of the left fibula. Bone scintigraphy showed hyperemia and bone uptake in the skull (more at left), upper orbital margin (intense), clavicles, 7th–9th left ribs (intense), lower half of the left femur, tibiae diaphysis (intense) and middle third of left fibula (intense). On suspicion of lymphoma, he held a first bone marrow biopsy that showed very suggestive alterations of classical Hodgkin lymphoma although the sample has been scarce and poorly processed. Thoraco-abdominal-pelvic CT scan showed only hepatomegaly. A percutaneous liver biopsy was performed and revealed poorly formed granulomatous reaction without necrosis or multinucleated giant cells; plasma cells in the lymphocytic cuff was observed. Blood cultures and *mycobacterium tuberculosis*

research in liver fragment and gastric lavage were negative. Bone biopsy was repeated, which did not corroborate the previous findings.

The patient was discharged; no significant pain improvement has been achieved. At 4 months of follow-up, he remained very symptomatic, mainly at the level of the forearms and shins, although under transdermal and sublingual fentanyl and pregabalin. We requested bone scan and new analytical study including syphilis serology. The same relevant laboratory changes were observed however, TPPA was reactive and VDRL 1/128. Bone scintigraphy shows overlapping changes but with greater extension and increased intensity of uptake.

Diagnosis of reinfection secondary syphilis with periostitis was assumed and benzathine penicillin G was administered as 2.4 million units IM each at weekly intervals for 3 weeks. Four months later, patient denied bone pain but referred inflammatory arthralgia with 2 months of evolution. On physical examination showed fingers flexors tenosynovitis of the hand. Analytical study revealed: ESR 30 mm/1 h; CRP 22.4 mg/L; GGT 127 U/L, AP 128 U/L and VDRL titer was down to 1/16. Bone scintigraphy exhibited decrease of osteoclastic activity and abnormalities were already in subacute (leg bones) and chronic phase (skull). Magnetic resonance imaging (MRI) of hands not showed arthritis but confirmed tenosynovitis of 4th–5th digits flexors, abductor pollicis longus, extensor pollicis brevis and minor changes in other tendons.

We prescribed benzathine penicillin G again (1.2 million units IM/week, 6 weeks), and we also started acetaminophen 150 mg/day and prednisolone 10 mg/day. A month later, patient was practically asymptomatic with normalization of acute phase reactants, GGT and AP. Corticosteroid therapy was stopped in about 1 year. After 3 months of its discontinuation, the patient restarts prolonged morning stiffness of the hands as well as bone pain in the lower limbs. Analytical study remained normal. Bone scintigraphy showed only osteoblastic lesions (lower activity) with mild hyperemia in the bones of the legs and osteoblastic lesion (lower activity) without hyperemia in upper orbital margin. At this time, a similar scheme of benzathine penicillin G was prescribed and started hydroxychloroquine 400 mg/day. Patient's pain symptoms resolved completely in about 2 months and VDRL titer was now 1/8.

Discussion

When the skeletal structures become involved during early syphilis, the involvement is usually proliferative periostitis and more rarely destructive osteitis and osteomyelitis occur. The mechanism of injury, in this stage, is considered to involve spirochetal invasion of periosteal vascular beds, leading to inflammation and granulation tissue formation. The extension of this inflammation into the haversian canals causes osteitis and osteomyelitis, most commonly in the tibia and skull, in which there were multiple lytic and sclerotic lesions. Relatively constant symptoms are the worsening of bone pain at night and febrile accesses; examination may reveal tenderness over the involved bones, which is sharply localized and may be accompanied with local edema.²

Early stage syphilitic bone involvement may be an underdiagnosed manifestation of this protean disease. The most comprehensive study on bone-destructive involvement in early syphilis was carried out by Reynolds and Wasserman between the years of 1919 and 1940. This study reported only 0.15% of bone-destructive lesions out of a total of 10,000 cases of early syphilis, suggesting that bone lesions are extremely rare in early-stage syphilis (primary and secondary). However, a 1952 study by Thompson and Preston reported that 9% of patients with secondary syphilis had cranial lesions. This difference in percentages may be attributed to the fact that until the 1932 there had been no recorded

X-ray observations and early bone-involvement syphilis may not have been identified. Even the introduction of X-ray examinations could not compare with the imaging modalities subsequently developed, which acted to detecting previously unrecognized bony involvement. Thus, there have been more frequent reports regarding skeletal involvement in early syphilis and this may imply that the true incidence of bone involvement in early-stage syphilis may be higher than had previously been appreciated.³

Documentation of syphilis periostitis has remained confined mainly to case reports and review articles.

The efficacy of penicillin for the treatment of syphilis has been well established through over 50 years of clinical experience. Almost all treatment recommendations are based on expert opinions and benzylpenicillin (penicillin G), administered parenterally, is the preferred drug. The preparations used, the dosage, and the length of treatment depend on the stage and clinical manifestations of disease and by geographical region. Although there has been some debate on the theoretical benefit of prolonged exposure to therapeutic doses of penicillin, limited data suggest that there is no difference between standard and prolonged regimens.^{1,2,4}

An infection with *Treponema pallidum* does not confer solid immunity to reinfection. The secondary stage lasts for several weeks or months and may reoccur in approximately 25% of untreated patients.¹ The titers of antibody during reinfection were usually higher than those during the first infection, and the clinical and serologic responses to treatment were always slower.⁵

The relation of syphilis with arthralgia and tenosynovitis is not so obvious. There are few reports in the literature to describe this rheumatological complications and those that exist have reported a rapid improvement after penicillin institution.⁶

There have been reported cases in the literature of hepatitis attributed to syphilis in HIV-infected individuals.⁷ The most prominent laboratory abnormality at the time of presentation was a marked cholestatic pattern with milder elevations in liver transaminase levels. The clinical manifestations of syphilitic hepatitis are thus attributable to the periportal inflammatory response accompanying treponemal invasion. Syphilis should be entertained as a potential etiology of abnormal liver enzyme levels in the proper clinical setting, and the condition is reversible with appropriate antimicrobial therapy.⁷

In conclusion, we present two cases of extensive lytic bone lesions and one of them, curiously, also presented tenosynovitis as part of the presenting symptoms of syphilis. While these presentations, including its appearance on imaging, is not usually considered a typical part of the clinical spectrum of early syphilitic infection, dogma on this point may be dated and indeed outdated. Even in the 21st century, syphilis continues to be a great imitator,

and a high index of suspicion must be kept for this classical (and highly treatable) diagnosis in the appropriate clinical set-up.

Ethical disclosures

Protection of human and animal subjects. The authors declare that no experiments were performed on humans or animals for this study.

Confidentiality of data. The authors declare that they have followed the protocols of their work center on the publication of patient data.

Right to privacy and informed consent. The authors declare that no patient data appear in this article.

Author disclosure

All authors make substantial contributions to acquisition, analysis and interpretation of data. All critically revise it for important critical content and give final approval of the version of the article accepted for publication.

Conflicts of interest

All authors declare no conflict of interest.

Sources of support in the form of grants or industrial support

Not applicable.

Bibliografía

1. Kevin A Fenton, Romulus B, Raffaele V, Justin T Okano, Tara M, Sevgi A, Sally B. Infectious syphilis in high-income settings in the 21st century. *Lancet Infect Dis.* 2008;8:244–53.
2. Boix V, Merino E, Reus S, Torrus D, Portilla J. Polyostotic osteitis in secondary syphilis in an HIV-infected patient. *Sex Transm Dis.* 2013;40:645–6.
3. Bezalely S, Jacob G, Flusser G, Ablin J. Syphilis: an unusual manifestation? *BMJ Case Rep.* 2014;2014, <http://dx.doi.org/10.1136/bcr-2014-204871>
4. Gurland IA, Korn L, Edelman L, Wallach F. An unusual manifestation of acquired syphilis. *CID.* 2001;32:667–9.
5. Fiumara NJ. Reinfection primary, secondary, and latent syphilis: the serologic response after treatment. *Sex Transm Dis.* 1980;7:111–5.
6. Reginato AJ, Schumacher R, Jimenez S, Maurer K. Synovitis in secondary syphilis. *Arthritis Rheumat.* 1979;22:170–6.
7. Mullick CJ, Liappis AP, Benator DA, Roberts AD, Parenti DM, Simon GL. Syphilitic hepatitis in HIV-infected patients: a report of 7 cases and review of the literature. *Clin Infect Dis.* 2004;39:e100–5.