

Clinicopathologic conference

## Young woman with relapsing arthritis<sup>☆</sup>

José A. Gómez-Puerta<sup>a,\*</sup> and Emma García-Melchor<sup>b</sup>

<sup>a</sup> Unidad de Artritis, Servicio de Reumatología, Hospital Clínic, Barcelona, Spain

<sup>b</sup> Servicio de Reumatología, Hospital Universitari Germans Trias i Pujol, Badalona, Barcelona, Spain

### ARTICLE INFO

#### Article history:

Received February 9, 2009

Accepted March 4, 2009

Available online November 7, 2009

#### Keywords:

Relapsing arthritis

Intermittent hydrarthrosis

Periodic fever syndromes

MEFV

### ABSTRACT

A 28-years old lady complains of self-limited episodes of relapsing knee arthritis of 48-72 h of duration every 2 weeks. Immunological profile was all negative. At the same time, radiological images did not reveal any abnormality. She underwent to knee arthroscopy, however, a definite diagnosis was not reached. We discuss the differential diagnosis of relapsing arthritis..

© 2009 Elsevier España, S.L. All rights reserved

#### Palabras clave:

Artritis intermitente

Hidrartritis intermitente

Síndromes de fiebre periódica

MEFV

### Mujer joven con artritis intermitente

#### RESUMEN

Mujer de 28 años con episodios autolimitados de artritis intermitente de rodilla de 48 a 72 h de duración, los cuales se repetían cada 2 semanas de forma periódica. El estudio inmunológico fue negativo, así como el estudio radiológico. Posteriormente se realizó artroscopia de rodilla sin llegar a un diagnóstico definitivo. Se discuten, a continuación, las diferentes causas de reumatismos intermitentes.

© 2009 Elsevier España, S.L. Todos los derechos reservados.

### Presentation of the case (Dr. Gómez-Puerta)

We present the case of a 28-year-old woman without any prior history, toxic habits or known allergies. She had recurrent ear infections, allergic rhinitis and asthma as a child and was operated due to a thyro-glossal cyst.

Since the age of 18 she presents intermittent and self-limited episodes of pain and swelling of the right knee. She did not refer trauma fever, oral ulcers or a history of genital or gastrointestinal infections, nor the presence of skin lesions.

In 1998 she was treated at another center where a magnetic resonance (MR) of the right knee was obtained, which was normal. Three years later and faced with a relapse of right knee arthritis, a new MR was performed and also resulted normal.

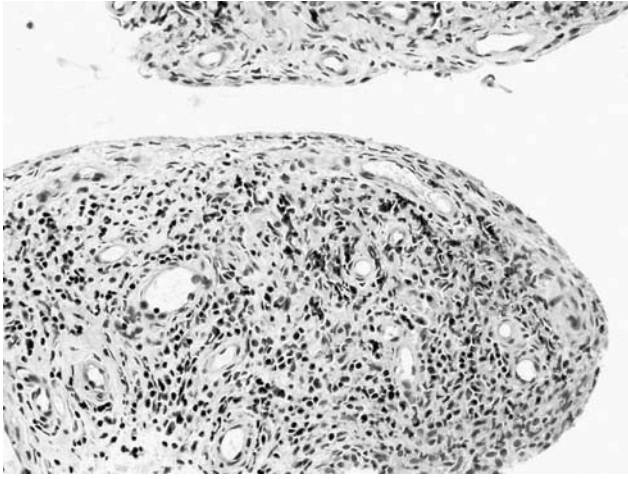
In July 2004 she visited our center for the first time, presenting a new episode of right knee swelling. Upon examination she was observed to have synovitis of the right knee, with marked effusion but no functional limitation. No arthritis was seen in other localizations. The examination of the spinal column was normal, as were the sacroiliac joints. Knee arthrocentesis yielded a clear yellow fluid, with 1,100 cells/mm<sup>3</sup> [4% polymorphonuclear, 93% lymphocytes and 3% monocytes], 1,400 red blood cells/mm<sup>3</sup>, no crystals. Synovial fluid glucose was 84 mg/dl (normal: 35-75 mg/dl). Simple x-rays of the knees and sacroiliac joints were normal.

Laboratory analysis showed a normal C reactive protein (CRP) and an erythrocyte sedimentation rate (ESR), (0.5 mg/dl and 3 mm, respectively); 4,700 leucocytes (58% polymorphonuclears, 27% lymphocytes and 6,5% eosinophils); hemoglobin 12.8 mg/

<sup>☆</sup>The present case was presented and discussed at the Session of the Sociedad Catalana de Reumatología, on 1 February 2008.

\* Corresponding author.

E-mail address: [jagomez@clinic.ub.es](mailto:jagomez@clinic.ub.es), [josealfredogomez@yahoo.com](mailto:josealfredogomez@yahoo.com) (J.A. Gómez-Puerta).



**Figure.** Synovial membrane pathology: a normal synovial lining with no signs of hypertrophy is observed. The stroma has abundant lymphocytes and perivascular plasma cells in the absence of polymorphonuclear cells (hematoxylin-eosin, 20x10) (image courtesy of Dr. J. D. Cañete and Dr. R. Celis).

dl; hematocrite 36%; platelets 196,000 cells/mm<sup>3</sup>, and uric acid concentrations of 4.2 mg/dl (normal: 3.5 to 7.0 mg/dl). The liver function tests, renal function and muscle enzymes, cholesterol, triglycerides and coagulations tests were all normal. Proteins were normal, total protein 65 g/l and serum albumin 42 g/l. Urine sediment and 24 h proteinuria were normal.

The patient had positive, low titer (1/40) antinuclear antibodies; the rest of the immunological tests were negative, including anti-double stranded DNA antibodies (anti-dsDNA), rheumatoid factor, anti-cyclic citrullinated peptide (anti-CCP), anti-Ro/SS-A, anti-La/SS-B, anti-Sm (Smith) and anti-RNP (ribonucleoproteins) antibodies, HLA B27, antiendomysial, antirreticulin and antigliadin antibodies. Immunoglobulins (IgA, IgE, IgG and IgM) and serum complement were normal.

A month later and during a flare up of right knee arthritis, an arthroscopy was carried out (July 2004), macroscopically showing synovial hypertrophy with small villous formations and tortuous vessels. Histopathology showed that the synovial villi were mildly thickened due to an extensive and diffuse lympho-plasmacyte infiltrate, especially on the vascular connective stroma, with a predominance of CD3 positive T lymphocytes, with a greater expression of CD4 than CD8 lymphocytes (Figure).

The patient remained asymptomatic for a few months after the arthroscopy but in March 2005 presented a new, milder episode of right knee arthritis.

These episodes, as had happened in earlier episodes, lasted between 48 and 72 h; important swelling and effusion accompanied them, although with mild pain. It always affected the right knee and were periodically repeated every 15–17 days.

### Discussion of the clinical case (Dr. García-Melchor)

Taking intermittent arthritis as a guideline, we can reach the differential diagnosis between the following entities presenting as intermittent rheumatism<sup>1,2</sup> (Table 1).

- Crystal arthritis due to monosodium urate, calcium pyrophosphate or hydroxyapatite is well known by all and can adopt a cyclic pattern.<sup>1</sup> Because the joint fluid from our case does not show crystals, microcrystalline arthritis can be ruled out as a diagnosis.
- Our patient had no history of diarrhea or intestinal abnormalities which suggested inflammatory intestinal disease. Although

**Table 1**  
Diseases associated to intermittent rheumatism

Micro crystal arthropathy (gout, calcium pyrophosphate, hydroxyapatite)
Reactive arthritis
Arthritis associated with inflammatory intestinal disease (Crohn's disease and ulcerative colitis)
Palindromic rheumatism
Behçet's disease
Sarcoidosis
Relapsing polychondritis
Whipple's disease
Autoinflammatory syndromes
Familial Mediterranean fever
TRAPS
Hyper-IgD syndrome
Hyperlipidemia
Intermittent hydrartrrosis

Modified from Sanmartí et al.<sup>2</sup>

IgD indicates immunoglobulin D; TRAPS, Periodic syndrome associated to the Tumor Necrosis Factor Receptor.

on occasion arthritis precedes (by months or a few years) the appearance of intestinal signs and symptoms, we consider it unlikely because the patient has had knee monoarthritis for 10 years with no intestinal symptoms or other data indicating a background inflammatory intestinal condition.<sup>3</sup>

- Reactive Arthritis (ReA) is defined as a mono or polyarticular inflammatory arthropathy, which is frequently accompanied by extraarticular manifestations that frequently appears after a suspected or demonstrated distant infection, with a variable latency period, generally under a month, without it being possible to isolate a germ responsible in the affected joints. Although its distribution is universal, Caucasians are more affected and between 60% and 80% of patients are positive for HLA B27. The disease usually develops in 3 phases: 1) pre-arthritis or pre-reactive phase, in which symptoms of the originating infectious process appear, if present, and is usually subclinical; 2) Acute phase which appears between one and three weeks after and may include arthritis (in 100% of patients) as a main sign, urethritis and conjunctivitis and, occasionally, other skin manifestations (and is self-limited after a few months), and 3) chronic phase characterized by relapses which can last in excess of 15 years after diagnosis. ReA is usually oligoarticular, asymmetric and asynchronous, predominantly in the lower limbs and may last for weeks or even several months.<sup>4</sup> The absence of a previous infection (intestinal or genital), B27 negativity and a cyclic, rhythmic and monoarticular pattern in our patient is contrary to a diagnosis of ReA.
- Patients with type II hyperlipoproteinemia may present monoarticular, oligoarticular or even polyarticular arthritis with a migrating pattern.<sup>5</sup> The joint fluid is usually inflammatory. Tendon xanthomas may be mistaken for rheumatoid nodules or tophi. Another musculoskeletal characteristic is Achillean tenosynovitis. Cholesterol and triglycerides in our patient were normal, excluding this diagnosis.
- Lyme disease is an infection caused by *Borrelia burgdorferi*, a spirochete transmitted through the Ixodes tick bites.<sup>6,7</sup> Three phases can be distinguished in its progression: localized infection, disseminated and persistent infection. The most important skin manifestation is erythema migrans, appearing in 80% of cases after a 3–32 day incubation period. Regarding the musculoskeletal manifestations, joint pain and myalgia may appear from the beginning of infection. Arthritis appears during the last phase in 60% of patients not receiving treatment. It usually appears as intermittent bouts of large joint oligoarthritis, with preference for the knees, resolving in weeks or months. Recurrence is reduced after a year. Some patients may present chronic and erosive arthritis. Our patient does not have a history of bites or skin

lesions; her arthritis is resolved within 48 hours and has constant cycles, something that does not occur in Lyme's disease, excluding this diagnosis.

- Sarcoidosis is a systemic disease that is characterized anatomopathologically by the presence of non-caseating granulomas.<sup>8,9</sup> Although it can clinically affect any organ, its characteristics are the presence of bilateral hilar adenopathy, pulmonary infiltrates and skin and eye lesions. 25% of patients have joint manifestations in the form of acute or chronic arthritis, or tenosynovitis. Acute arthritis can appear isolated or associated to the bilateral hilar adenopathy and erythema nodosum, something known as Löfgren's syndrome<sup>10</sup>. If a synovial biopsy is performed, non-caseating granulomas can be seen. The patient had no clinical signs suggestive of sarcoidosis or granulomas in the synovial biopsy, ruling out this diagnosis.
- Behçet's disease is a vasculitis that presents with recurrent orogenital ulcers, associated to other systemic manifestations, especially on the skin, eyes, joints, nervous system and vascular<sup>11</sup>. In order to establish a diagnosis it is necessary to document the presence of oral ulcers. 50% of patients have joint pain or arthritis. This usually is mono or oligoarticular, non-erosive, and affects the larger joints: knees, hips, and wrists, respecting the axial skeleton. Ulcers and substitution of the superficial synovial membrane, although non-specific, characterize synovial biopsy, by granulation tissue with scarce plasma cells. Our patient did not have a history of recurrent oral ulcers and therefore Behçet's was ruled out.
- Relapsing polychondritis is an infrequent disease, characterized by recurrent inflammatory episodes that affect cartilaginous structures of the ears, nose, larynx and bronchial tree<sup>12</sup>. In addition, it is accompanied by systemic ocular, skin, internal ear and vascular manifestations. It is necessary to establish the presence of confirmed episodes of inflammation affecting the ear, nasal or laryngotracheal cartilage. Musculo-skeletal manifestations can be joint pain, tenosynovitis or oligo or polyarticular arthritis that appears acutely and has a migratory pattern. It usually is asymmetric and affects the carpus, small joints of the hands, the knees, ankles and parasternal joints. Our patient had no episodes of chondritis, ruling out the diagnosis.
- Described in 1907 by George Hoyt Whipple, Whipple's disease is caused by *Tropheryma whippelii* (from the greek trophe = feeding, and eryma = barrier), a gram positive bacilli that stain under PAS.<sup>13</sup> Its cardinal clinical manifestations are joint pain, weight loss, diarrhea and abdominal pain. Musculoskeletal manifestations are often migrating joint pain of large joints and, less frequently, chronic, non-erosive, migrating oligoarthritis or polyarthritis. The diagnosis is made through a biopsy of the small intestine, showing PAS positive material on the lamina propia. In our case, the patient had no gastrointestinal manifestations; her cyclic arthritis was not typical of Whipple's disease, making the diagnosis unlikely.
- Palindromic rheumatism (PR)<sup>1</sup> is defined as recurrent bouts of arthritis with a short duration of 24-72 h, which disappears spontaneously without complications. Bouts are usually mono or oligoarticular causing pain, swelling and great limitation. Peryarticular erythema is characteristic. Nodules similar to those of rheumatoid arthritis (RA) may appear, but disappear when the bout is resolved. Joint fluid is inflammatory and acute phase reactants (ESR and CRP) can be elevated. One third of the patients will develop chronic inflammatory arthritis after 6 years (mainly RA or systemic lupus erythematosus). Half of the patients are maintained as PR and one out of every ten patients remits spontaneously. In PR, the period between bouts is not constant as happened in our case, excluding it as a diagnosis.

- Hereditary periodic fever syndromes<sup>14-16</sup> are a group of hereditary diseases characterized by recurrent and self-limited inflammatory episodes that occur with fever, polyserositis, synovitis and skin manifestations. They are a consequence of an alteration in the mechanisms that regulate normal inflammatory processes. Of all of them we will exclude the familiar autoinflammatory syndrome induced by cold and the chronic juvenile joint, skin and neurological syndrome during the neonatal period or in children under one year of age, centering our attention on the other syndromes. Therefore we shall discuss in the differential diagnosis, familiar Mediterranean fever (FMF), the hyper-IgD syndrome and the periodic syndrome associated to the receptor for the tumor necrosis factor (TRAPS).

FMF is a hereditary disease of autosomal recessive transmission that is characterized by recurrent and brief episodes of fever, pain and swelling of one or several serosal surfaces. amyloidosis is its most important complication. The gene for FMF was found in 1992 on the short arm of chromosome 16. In 1997 this gene was characterized and named *MEFV* (*Mediterranean fever*). It encodes a protein called marenostin or pyrin, which are exclusively expressed on neutrophils. Its mutations provoke an alteration in the mechanisms of apoptosis of neutrophils, which translates in a faulty control of the normal inflammatory process in these patients, leading to sporadic episodes of fever and serositis. Clinical manifestations appear before 20 years of age in 80% of patients. The duration and frequency of the episodes vary extraordinarily, even in the same individual, but in general the bouts last from 24 to 48 hours, with no symptoms in between. Fever is present in all of the cases and other symptoms can be abdominal pain due to peritonitis or thoracic pain due to pleuritis or pericarditis. In less than one percent is arthritis the sole manifestation. Monoarthritis or asymmetric oligoarthritis appears abruptly. The chronic form is less frequent and lasts for weeks or months, with complete recovery in most of the cases. During the crisis it is common to see leukocytosis, elevation in acute phase reactants (ESR and CRP), which are normalized after the crisis.

The hyper-IgD syndrome is an autosomal recessive hereditary disease, linked to the gene for mevalonate kinase. It presents fever and abdominal pain, vomiting and diarrhea, joint pain and non-erosive arthritis of the large joints (knees and ankles). The presence of painful cervical adenopathy and the absence of serositis is characteristic. In addition, IgA and IgD are elevated.

TRAPS is inherited in an autosomal dominant manner and is due to mutations in the *TNFRSF1A* gene. It is characterized by prolonged episodes of fever (lasting over a week), accompanied by large joint pain, myalgia, conjunctivitis and reddened patches of skin, with arthritis being rare. Because our patient had no systemic signs of fever, we excluded periodic fever hereditary syndromes.

- Finally, intermittent hydrarthrosis (IH) is an entity described for the first time in 1845 by Perrin. It is characterized by episodes of joint effusion of a cyclical nature with a regular interval of time between bouts.

Its etiology is unknown. Cases associated to allergic manifestations have been described. Two types have been classically defined<sup>17</sup>: 1) *Symptomatic IH*, which progresses to RA, and 2) *Idiopathic RA*, unassociated to RA.

IH is more common in women, starting after puberty and before 45 years of age. It may appear with menarche and there are cases in which bouts coincide with menses. It may improve during periods of amenorrhea, pregnancy and lactation.<sup>16</sup>

Any joint can be affected, although it has a predilection for the knees, frequently unilateral. Its onset is abrupt, with the appearance of joint effusion without external signs of

inflammation such as a local increase in temperature or erythema. It produces little pain, usually appearing when the amount of fluid is important. Patients do not present fever or systemic manifestations during bouts. These last for 3 to 5 days, with a recurrence every 9 to 21 days. The duration of the cycle and the episodes is constant in the same individual, although they may vary over time. If more than one joint is affected, each has its own cycle. The joint is normal between episodes.<sup>17–19</sup>

It has a variable progression, with cases of spontaneous remission seen after years, although relapses may occur. Other cases persist with indefinite bouts. Laboratory testing (hemogram, biochemistry, acute phase reactants) are normal and the immunological tests are negative.<sup>20</sup> The joint fluid is of mechanical characteristics, with cell counts between 300 and 6,500 leukocytes/mm<sup>3</sup>, with lymphocyte predominance.<sup>19</sup>

With respect to imaging studies, x-rays show an increase in the density of soft tissue during episodes, without erosions.<sup>21</sup>

The anatomopathological study of the synovial fluid manifests edematous and hyperemic synovial villi with dilated vessels and thickened walls. In some cases there is a diffuse infiltrate of plasma cells and lymphocytes; in others, this infiltrate is scarce or of a perivascular localization.<sup>19</sup>

In 1956, Weiner et al<sup>19</sup> presented a series of 47 cases of IH, based on the following diagnostic criteria:

1. recurrence of joint symptoms at regular intervals;
2. absence of joint signs y symptoms between bouts;
3. absence of systemic symptoms;
4. exclusion de other etiologies.

The fact that patients with IH present periodic episodes of joint inflammation recalls the hereditary syndromes of periodic fever. In fact, cases of patients heterozygous for the MEFV gene mutation with IH have been described.<sup>22</sup> The phenotype for MFV gene heterozygosis is varied and ranges from asymptomatic patients to patients with severe autoinflammatory diseases. In this manner, IH could be considered as a more benign process, limited to the joints within the spectrum of individuals heterozygous for the MEFV gene.

### Clinical diagnosis of the discussor (Dr. García-Melchor)

Therefore, after this differential diagnosis, the most probable diagnosis in our patient with recurrent monoarthritis with constant periodicity, without fever or systemic symptoms is IH, requiring the study of the MEFV gene.

### Definitive result of the presenter (Dr. Gómez-Puerta)

We effectively were found with a case of IH in a young woman with self-limited and cyclic bouts of knee monoarthritis, with a

negative serology and normal imaging (simple x-rays and MR) studies. Synovial membrane study through arthroscopy revealed only mild, non-specific inflammatory synovitis. The cyclic pattern in our patient obliges us to make a differential diagnosis fundamentally between PR and IH. In spite of the fact that these entities share clinical characteristics, there are certain aspects of their presentation that allows the differentiation between them (Table 2).<sup>23</sup>

- In spite of the absence of systemic symptoms or fever, a genetic study of the patient was asked for. In the study of exon 2 of the MEFV gene, a substitution of guanine for cytosine occurred in the first position of the 148 triplet, giving rise to a change of glutamic acid for glutamine. Such a mutation receives the name of E148Q and in this patient it was seen in only one allele, being heterozygous for the E148Q mutation. No mutations were seen in exons 2, 3, 4, 5, and 6 of the *TNFRSF1A* gene associated to TRAPS or on exon 3 of the *CIAS-1* gene, associated to cryopyrins.

Recently, Cañete et al<sup>22</sup> analyzed the presence of mutations in the MEFV gene in 3 Spanish patients with IH. Additionally, 6 control patients with other intermittent rheumatism were included (3 with Behçet's disease, 1 with seronegative, 1 with undifferentiated arthritis and one with calcium pyrophosphate crystals). The analysis of synovial fluid during the arthritis relapses in patients with IH showed a mildly inflammatory fluid (between 1.600 and 2.500 cells with mononuclear predominance), with a moderate increase in IL-6 concentrations. Heterozygous mutations for E148Q were found in the first patient, A744S in the second patient, and in the P369S-R408Q allele complex in the third patient. None of the 6 control patients had mutations for the MEFV gene. With this, the authors suggested that IH could correspond to a limited autoinflammatory process with a good prognosis within the clinical spectrum of heterozygous carriers of the MEFV gene.

In spite of the fact that our patient is heterozygous for the E148Q mutation, related with FMF, we consider that she has an IH with a mutation associated to the MEFV gene and not a FMF, because the patient does not fit the criteria for the latter, including the criteria of arthritis as the sole manifestations of FMF as recently described by Lidar et al<sup>24</sup> (Table 3).

In a recent review by Lachmann and Hawkins<sup>25</sup> it is noted that the E148Q mutation by itself is not associated with most of the cases of FMF. In addition, they propose that the presence of such a mutation can condition the clinical presentation of diverse inflammatory processes not related with FMF.

Mutations in the MEFV gene have also been studied in patients with PR, finding negative anti-CCP antibodies in 22% of patients with RP.<sup>26</sup> These results support the hypothesis of the implication of the MEFV mutations in the pathogenesis of diverse intermittent rheumatic diseases.

Finally, it must be mentioned that our patient is currently asymptomatic and treated with low dose colchicine, without new episodes of intermittent arthritis for the past months.

**Table 2**

Differences between palindromic rheumatism and intermittent hydrarthrosis

	Palindromic rheumatism	Intermittent hydrarthrosis
Type of attack	Swelling and pain	Mild joint effusion. Mild thickening
Attacks	Generally monoarticular	Generally mono or biarticular
Localization	Any joint	Preference for knees
Duration of the attack	Preference for small joints and hands	
Interval attacks	Hours to 1 or 2 days	From 2 to 5 days
Immunologic profile	Irregular	Mathematical regularity
	30%-50% are anti-CCP and RF positive	Usually negative

Modified from J Rotes-Querol.<sup>23</sup>

Anti-CCP indicates anti citrullinated cyclic peptide antibodies; RF, rheumatoid factor.

**Table 3**  
Clinical characteristics of familiar Mediterranean fever associated to arthritis

1. Fever during arthritis episodes (>38 °C, rectal temperature)
2. Large joint affection
3. Lower limb joint affection
4. Monoarticular affection
5. Short duration (> 6 h and < 7 days)
6. Recurrence (> 3 episodes)
7. Characteristic genotype (1 or 2 alleles related to FMF)
8. Complete response to colchicine prophylaxis
9. Familiar history of FMF
10. Leg or feet pain after mild exercise such as standing or walking for 1 hour
11. Genetic ancestor from a zone where FMF is prevalent
12. Age at onset < 10 years
13. Parent consanguinity
14. Proteinuria > 0.5 g 24 h

Modified from Lidar et al.<sup>24</sup>

FMF indicates familiar Mediterranean fever.

## Disclosures

The authors have no disclosures to make.

## References

1. Tena Marsà X. Síndromes intermitentes. In: Blanco FJ, Carreira P, Martín E, Mulero J, Navarro F, Olivé A, editors. *Manual SER de las enfermedades reumáticas*. 4th ed. Madrid: Editorial Panamericana; 2004. p. 93–4.
2. Sanmarti R, Cañete JD, Salvador G. Palindromic rheumatism and other relapsing arthritis. *Best Pract Res Clin Rheumatol.* 2004;18:647–61.
3. Gómez-Puerta JA, Sanmarti R. Artropatías asociadas a enfermedades inflamatorias del intestino. In: Alarcón-Segovia D, Molina J, Molina JF, Catoggio L, Cardiel MH, Angulo JM, editors. *Tratado Hispanoamericano de Reumatología*. Bogotá, Colombia: Editorial Nomos S.A.; 2006. p. 599–605.
4. Povedano Gómez JB, García López A. Artritis reactiva. Síndrome de Reiter. In: *Manual S.E.R. de las enfermedades reumáticas*. 3rd ed. Madrid: Editorial Panamericana; 2000. p. 408–14.
5. Klemp P, Halland AM, Majoos FL, Steyn K. Musculoskeletal manifestations in hyperlipidaemia: a controlled study. *Ann Rheum Dis.* 1993;52:44–8.
6. Steere AC. Borreliosis de Lyme. In: Braunwald E, Fauci AS, Kasper DL, Hauser SL, Longo DL, Jameson JL, editors. *Harrison Principios de medicina interna*. 16th ed. Madrid: McGraw-Hill; 2005. p. 1107–11.
7. Puius YA, Kalish RA. Lyme arthritis: Pathogenesis, clinical presentation, and management. *Infect Dis Clin North Am.* 2008;22:289–300.
8. Iannuzzi MC, Rybicki BA, Teirstein AS. Sarcoidosis. *N Engl J Med.* 2007;357:2153–65.
9. Torralba KD, Quismorio FP. Sarcoidosis and the rheumatologist. *Curr Opin Rheumatol.* 2009;21:62–70.
10. Mañá J, Gómez-Vaquero C, Montero A, Salazar A, Marcoval J, Valverde J, et al. Löfgren's syndrome revisited: A study of 186 patients. *Am J Med.* 1999;107:240–54.
11. Yazici H, Fresko I, Tunç R, Melikoglu M. Behçet's syndrome: pathogenesis, clinical manifestations and treatment. In: Ball GV, Bridges SL, editors. *Vasculitis*. Oxford: Oxford University Press; 2002.
12. Piette JC, Vinceneux P. Policondritis recidivante. In: Harris ED, Budd RC, Genovese MC, Firestein GS, Sargent JS, Sledge CB, editors. *Kelley Tratado de reumatología*. 7th ed. Madrid: Editorial Elsevier; 2005.
13. Reyes R, Peris P, Feu F, Martínez-Ferrer A, Quera A, Guañabens N. Whipple's disease. Analysis of 6 cases. *Med Clin (Barc).* 2008;130:219–22.
14. Modesto C, Aróstegui JI, Yagüe J, Arnal C. ¿Qué es lo que debo saber sobre los síndromes autoinflamatorios? *Semin Fun Esp Reumatol.* 2007;8:34–44.
15. Aróstegui JI, Yagüe J. Enfermedades autoinflamatorias sistémicas hereditarias. Síndromes hereditarios de fiebre periódica. *Med Clin (Barc).* 2007;129:267–77.
16. Aróstegui JI, Yagüe J. Enfermedades autoinflamatorias sistémicas hereditarias. Parte II: síndromes periódicos asociados a criopirina, granulomatosis sistémicas pediátricas y síndrome PAPA. *Med Clin (Barc).* 2008;130:429–38.
17. Reeves JE. Intermittent hydrarthrosis; two cases. *Calif Med.* 1949;71:359–61.
18. Mattingly S. Intermittent hydrarthrosis. *Br Med J.* 1957;32:139–43.
19. Weiner AD, Ghormley RK. Periodic benign synovitis: Idiopathic intermittent hydrarthrosis. *J Bone Joint Surg Am.* 1956;38:1039–55.
20. Ehrlich GE. Intermittent and periodic arthritic symptoms. En: McCarty, editor. *Arthritis and related conditions*. 9th ed. Philadelphia: Lea and Febiger; 1979. p. 663–80.
21. Queiro-Silva R, Tinturé-Eguren T, López-Lagunas I. Successful therapy with low-dose colchicine in intermittent hydrarthrosis. *Rheumatology.* 2003;42:391–2.
22. Cañete JD, Aróstegui JI, Queiró R, Sanmarti R, Ballina J, Bosch X, et al. Association of intermittent hydrarthrosis with MEFV gene mutations. *Arthritis Rheum.* 2006;54:2334–5.
23. Rotes-Querol J, Lience E. Intermittent rheumatism. Palindromic rheumatism. Intermittent hydrarthrosis. Allergic rheumatism. *Rev Esp Reumatol.* 1959;8:8–37.
24. Lidar M, Kedem R, Levartovsky D, Langevitz P, Livneh A. Arthritis as the sole episodic manifestation of familiar Mediterranean fever. *J Rheumatol.* 2005;32:859–62.
25. Lundberg I.E., Grundtman C. Developments in the scientific and clinical understanding of autoinflammatory disorders. *Arthritis Res Ther.* 2009;11:212.
26. Cañete JD, Aróstegui JI, Queiró R, Gratacós J, Hernández MV, Larrosa M, et al. An unexpectedly high frequency of MEFV mutations in patients with anti-citrullinated protein antibody-negative palindromic rheumatism. *Arthritis Rheum.* 2007;56:2784–8.