

Original article

Primary Sjögren's syndrome: Expression of NF- κ B in minor salivary glands

Liliana Villalon,^{a,*} Marta Mamani,^b Felix E. Romanini,^b Antonio Catalan Pellet,^b and Alejandro Berra^a^aLaboratorio de Investigaciones Oculares, Departamento de Patología, Facultad de Medicina, Universidad de Buenos Aires, Buenos Aires, Argentina^bServicio de Reumatología, Hospital Bernardino Rivadavia, Buenos Aires, Argentina

ARTICLE INFO

Article history:

Received June 25, 2009

Accepted October 13, 2009

Keywords:

Primary Sjögren's syndrome

Expression of NF- κ B in minor salivary glands

ABSTRACT

Purpose: To evaluate nuclear NF- κ B translocation in minor salivary glands (mSG) of human primary Sjögren Syndrome (pSS).

Methods: Lip biopsies' mSG were done in 24 female patients with pSS from the Rheumatology Service of Rivadavia Hospital. Glands were stained with H&E and immunostained for NF- κ B. Specimens were classified according to the Chisholm and Masson score.

Results: The biopsies (H&E staining) showed lymphoplasmocytic infiltrates, forming periacini and periductal foci which number depending on the stage of the disease. In stages III and IV there was acini destruction and, in some cases, fibrosis. In the biopsies with a diagnosis of sialadenitis we observed interstitially-dispersed lymphoplasmocytic elements and also polymorphonuclear neutrophils. The lip biopsies' mSG of patients with clinical-serological diagnosis of pSS showed nuclear translocation of NF- κ B in lymphocytes of focal infiltrates and in the acini epithelium adjacent to the infiltrates. In distal acini and ductal structures from the infiltrates we did not observe nuclear translocation. However, in SSp patients with sialadenitis interstitial lymphocytes with nuclear translocation were observed but neither in the acini or the ducts. SSp patients with normal glands did not show nuclear translocation of NF- κ B factor either in the acini or in the ducts.

Conclusions: These results allow us to infer the importance of lymphocyte-epithelium interaction on the activation of NF- κ B in human pSS.

© 2009 Elsevier España, S.L. All rights reserved.

Síndrome de Sjögren primario: expresión del factor NF- κ B en glándula salival menor

RESUMEN

Palabras clave:

Síndrome de Sjögren

Autoinmunidad NF- κ B en glándulas salivales menores

Objetivo: Evaluar la translocación nuclear del factor NF- κ B en las glándulas salivales menores de pacientes con síndrome de Sjögren primario (SSp).

Métodos: Se realizaron biopsias de glándulas salivales menores en 24 pacientes mujeres con diagnóstico de SSp del Servicio de Reumatología del Hospital Rivadavia. Las glándulas fueron teñidas con H&E y la inmunohistoquímica para NF- κ B, fueron clasificados de acuerdo con la puntuación de Chisholm y Masson.

Resultados: Las biopsias de pacientes con SSp (H&E) mostraron infiltrados linfoplasmocitarios, formando focos periacinarios y periductales cuyo número depende del estadio de la enfermedad. En las fases III y IV se observa la destrucción de los acinos y, en algunos casos, fibrosis. En las biopsias con diagnóstico de sialoadenitis observamos elementos linfoplasmocitarios intersticiales dispersos y también neutrófilos polimorfonucleares. Las biopsias de labio de pacientes con diagnóstico clínico serológico de SSp mostraron la translocación nuclear de NF- κ B en los linfocitos de infiltración focal y en el epitelio de los acinos adyacentes a los infiltrados. En acinos y en las estructuras ductales alejadas de los infiltrados, no observamos translocación nuclear. Sin embargo, en pacientes con sialoadenitis se observaron linfocitos intersticiales con translocación nuclear pero no en acinos y ductos. Los pacientes con SSp con glándula normal no mostraron translocación nuclear del factor NF- κ B, ni en acinos ni en el conducto.

Conclusiones: Estos resultados nos permiten inferir la importancia de la interacción linfocitosepitelio y la activación del factor NF- κ B en pacientes con diagnóstico de SSp.

© 2009 Elsevier España, S.L. Todos los derechos reservados.

* Corresponding author.

E-mail address: lvillalon@hotmail.com (L. Villalon).

Introduction

Sjögren's syndrome (SS) is a chronic systemic autoimmune disease characterised by keratoconjunctivitis sicca, xerostomia, and extraglandular manifestations (arthritis, Raynaud's syndrome, vasculitis, and so on).^{1,2} Primary Sjögren's syndrome (pSS) must be distinguished from Secondary Sjögren's syndrome (sSS), which is associated with other autoimmune diseases such as systemic lupus erythematosus, rheumatoid arthritis, and systemic sclerosis, and also from other causes associated with "sicca syndrome" such as medications or infections.^{3,4} It is most frequent in women (10:1) 45–62 years of age.⁵

Histologically, it is characterised by lymphoid hyperplasia with plasmatic cells and histiocytes present in salivary and lacrimal glands and progressive loss of acinar structures and fibrosis in late stages—changes that result in the disorders of glandular function.⁶ The lymphoid infiltrates primarily consist of CD4 T lymphocytes and a lesser number of B lymphocytes.⁷ Patients with pSS and sSS have serum autoantibodies (anti-SS-A/Ro and anti-SS-B/La) as well as, in CD4 T lymphocytes, the expression of various activation markers (histocompatibility complex [MHC] HLA-DR, adhesion molecules, IL-2, and IFN- γ).⁸ Others have been described, such as the anti-muscarinic receptor autoantibodies⁹ and the anti-alpha-fodrin autoantibodies.¹⁰

Nuclear factor kappa B (NF- κ B) is a transcription factor belonging to a family of inducible transcription factors that participate in the immune response and in inflammation.¹¹ NF- κ B is normally found in the cytoplasm of immune system cells and in other types of cells such as some epithelial cells in inactive form, forming a complex with a protein called NF- κ B inhibitor (I- κ B). This results in a steric hindrance that checks the translocation of NF- κ B to the nucleus, thereby blocking stimuli for the transcription of various genes.

Various stimuli such as infections, lipopolysaccharides, UV radiation, and the cytokines IL-1 and TNF- α activate a number of enzymes. These, ultimately, trigger the activation and release of NF- κ B, which may be translocated to the nucleus and begin the transcription of a wide range of genes with elements that are responsive to NF- κ B. Among these are the genes that produce proinflammatory cytokines (TNF- α , IL-6, IL-8), adhesion molecules, cytokine receptors, and histocompatibility molecules.¹¹

Our working hypothesis on the aetiopathogenesis in the accessory salivary glands of patients with pSS is that the lymphocytes infiltrating the gland secrete proinflammatory cytokines, including TNF- α , IL-1, and IL-6, that would activate specific receptors for these cytokines in epithelial cells of the acini and ducts. Activation of these receptors would trigger activation of the NF- κ B signalling pathway. This transcription factor would translocate to the nucleus, activating proinflammatory genes that would trigger proinflammatory cytokine secretion into the interstitium, and the inflammatory response would become self-perpetuating.

This hypothesis is based on the fact that the participation of NF- κ B has been described in the development of other autoimmune diseases such as Type 1 diabetes, systemic lupus erythematosus and rheumatoid arthritis.¹²

The glandular epithelial cells would also play an active role in inducing and perpetuating the inflammatory process⁸ through the expression of proinflammatory cytokines, IL-1 and IL-6, TNF- α , the class II MHC HLA-DR, the proto-oncogene *c-myc* and autoantigens.¹³

The purpose of this study was to evaluate the nuclear translocation of factor NF- κ B in the acinar and ductal epithelium and in the inflammatory foci in the minor salivary glands of patients with pSS.

Patients, materials, and methods

Patients

The patients studied were 24 females, 39–58 years of age, originating from the Rheumatology Service at Bernardino Rivadavia

Hospital, with a diagnosis of pSS according to the European-American diagnostic criteria for pSS.¹⁴

The patients were diagnosed with pSS because they presented with dry eye signs and symptoms, dry mouth symptoms, and serology positive for anti-Ro (SS-A) and/or anti-La (SS-B) antibodies with no other associated disease.¹⁴

The minor salivary glands of these patients were biopsied via a horizontal incision in the vestibular mucosa of the lower lip. One or two minor salivary glands were dissected. All biopsies were fixed in 10% buffered formalin.

Patients were assigned to 3 groups, according to the histopathology findings: Group A: salivary gland had focal periacinar and periductal lymphoplasmacytic infiltrate; Group B: presence of mononuclear leukocytes and polymorphonuclear neutrophils dispersed in the interstitium (non-specific sialadenitis); and Group C: salivary gland had no changes in morphology.

The study was approved by the Ethics Committee of the University of Buenos Aires Faculty of Medicine.

Hematoxylin and eosin (H&E) staining

All the human minor salivary glands fixed in 10% buffered formalin were embedded in paraffin; 5- μ m sections were cut using the Jung sliding microtome (Germany) and stained with Harris hematoxylin and aqueous eosin (Biopure, Argentina), as described above.¹⁵

The minor salivary glands were classified by the scoring method of Chisholm et al, which groups them into 4 stages according to the number of foci (0=normal gland, I=non-specific sialadenitis, II=presence of one focus, III=presence of 2 or more foci, and IV=stage III plus the presence of fibrosis and broad sectors of acinar destruction); each focus must be made up of at least 50 cells per 4 mm².¹⁵

Immunohistochemistry

The immunohistochemistry (IHC) technique was applied to paraffin sections. The sections were deparaffinized and rehydrated with subsequent washing in phosphate buffer. Microwaving in citrate buffer was used for antigen retrieval. Endogenous peroxidase was inhibited using 30% H₂O₂. It was incubated with NF- κ B primary antibody (cell signalling) at 37 °C overnight in a moist chamber. It was washed in phosphate buffer and transferred to a detection system that uses a biotinylated secondary antibody (Vectastain Universal ABC kit PK-G200, Vector Labs) 20'. It was then washed in phosphate buffer and transferred to the DAB developing system (Peroxidase Substrate kit SK 4100, Vector Labs) controlling the microscope. Nuclear contrast was obtained with hematoxylin, it was dehydrated and clarified and the preparations were mounted on positively charged silanized slides.

All patients enrolled in the study had received sufficient information and had given their informed consent in writing to participate in the study.

Results

In this study, biopsies of minor salivary glands from 24 patients with a diagnosis of pSS were evaluated. Lymphoplasmacytic infiltrate forming periacinar and periductal foci was seen in 12/24 salivary glands, constituting Group A of our study: 2/12 had only one lymphoplasmacytic focus, 9/12 showed 2 or more lymphoplasmacytic foci, and 1/12 had 2 or more foci plus broad sectors of acinar destruction, consistent with the stage II, III, and IV classification of Chisholm et al,¹⁵ respectively. (Figure 1A).

Of the remaining 12 patients, 7 showed a scant number of interstitially dispersed lymphoplasmacytic infiltrates and polymorphonuclear neutrophils; these were diagnosed with non-

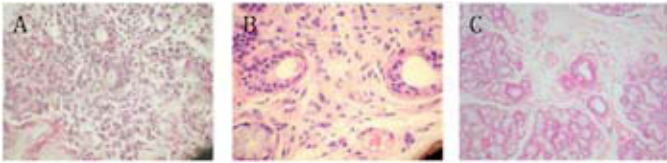


Figure 1. Representative microphotographs of minor salivary glands in patients with Sjögren's syndrome (pSS). A) Group A patient, in which focal lymphoplasmacytic infiltrate and acinar atrophy are seen. B) Group B patient, with sialadenitis: interstitially dispersed lymphoplasmacytic infiltrates with polymorphonuclear neutrophils present. C) Group C patient, showing a gland with normal features, no lymphoplasmacytic foci and no interstitial infiltrate. HE-40X.

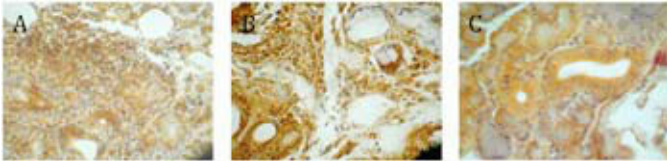


Figure 2. Immunohistochemistry for factor NF- κ B in minor salivary glands. A) Group A patient: nuclear translocation is observed in acinar epithelium and in lymphoplasmacytic cells that form the confluent inflammatory foci. B) Group B patient, with sialadenitis: nuclear translocation in interstitial inflammatory component and in the cytoplasm of acinar and ductal epithelium. C) Group C patient: cytoplasmic positivity in acinar and ductal epithelium. (40 \times increase).

specific sialadenitis and constituted Group B (Figure 1B). The other 5 patients showed glandular structure of normal characteristics and constituted Group C.

The immunohistochemistry study to evaluate factor NF- κ B showed nuclear positivity in the Group A patients in the lymphoplasmacytic infiltrates and in the acinar and ductal epithelial cells adjacent to the infiltrates (Figure 2A). No nuclear translocation was observed in the acini or ducts distant from the infiltrates, and the positive indicator turned out to be in the cytoplasm only.

In the patients with non-specific sialadenitis (Group B), nuclear translocation was observed only in the interstitial mononuclear leukocytes and not in the acini or ducts, where the positivity was seen in the cytoplasm (Figure 2B).

Those patients with normal glandular structure (Group C) presented no nuclear translocation, showing positivity in the cytoplasm only (Figure 2C).

Discussion

In this study, we have demonstrated that the minor salivary glands of Group A patients show nuclear translocation of factor NF- κ B in lymphocytes found in the inflammatory foci and in epithelial cells of the acini and ducts adjacent to these foci, the translocation being expressed more in the acini than in the ducts. In this group, no nuclear translocation of factor NF- κ B was observed in the acini and ducts distant from the inflammatory foci.

The patients who had the same symptomatology but, histologically, were consistent with non-specific sialadenitis showed nuclear translocation of factor NF- κ B only in lymphocytes found in the interstitium.

None of the patients with a diagnosis of pSS but histologically normal glands showed nuclear translocation of factor NF- κ B.

These findings describe the cellular and tissular topographic distribution of NF- κ B in the salivary glands of patients with pSS, giving evidence of the importance of the lymphocyte-epithelial cell interaction in terms of the production of lymphocytic cytokines

and the activation of epithelial receptors that lead to activation and nuclear translocation of NF- κ B. In contrast, the acini and ducts distant from the inflammatory infiltrate evidenced no nuclear translocation of factor NF- κ B.

In pSS, the mechanism or mechanisms that bring about the progressive destruction of the acini without destruction of the ducts are still unknown.

In response to the activation of surface receptors (TNF- α , IL-1 β , toll-like), numerous signals are activated in B and T lymphocytes that initiate the phosphorylation and degradation of I- κ B,¹⁶ triggering the cytoplasmic release of NF- κ B and subsequent translocation of this factor to the nucleus, where it binds to different DNA sites activating transcription genes. Among these are those triggering the synthesis of cytokines (TNF- α , IL-1 β , IL-6, and IL-8), as well as adhesion molecules, nitric oxide, COX-2, and metalloproteinases (MMP).^{17,18}

The expression of TNF- α and IL-1 β receptors observed in the acini and ducts and in cells found in the inflammatory infiltrates in human minor salivary glands was significantly greater in patients with pSS than in the normal controls.¹⁹

Significant extracellular expression was shown by TNF- α , IL-1 β , and high-mobility chromosomal protein 1 (HMGB-1) in connection with mononuclear infiltrates in human minor salivary glands of patients with pSS.¹⁹ Expression of these proinflammatory cytokines is mediated by the activation of NF- κ B.^{12,20}

The production of proinflammatory cytokines by lymphocytes present in the glands of patients with pSS would suggest that these cytokines act upon the epithelial cells of the adjacent acini and ducts, inducing the nuclear translocation of NF- κ B.

However, other factors or cytokines would intervene in the nuclear translocation of NF- κ B in the acini and ducts of patients with pSS, because it was impossible to find nuclear translocation of NF- κ B in the adjacent acini and ducts in the patients with sialadenitis, where we observed nuclear translocation of NF- κ B in the infiltrates. We hypothesized that the lymphocytes found in the minor salivary glands of patients with pSS could be autoreactive, while those found in sialadenitis would not be autoreactive. In the glands studied, we found that the expression of nuclear translocation of NF- κ B was greater in the acini than in the ducts. These results are consistent with the findings in humans of other authors, who observe a greater reduction of I κ B- α and a greater nuclear translocation of factor NF- κ B in the acini than in the ducts.²¹

These authors also demonstrate a connection between the production of MMP and the nuclear translocation of factor NF- κ B in the acini induced by TNF- α and IL-1 β .²¹ Expression of MMP and its inhibitor TIMP takes place by action of the acini, intervening in the destruction of the extracellular matrix through their proteolytic activity. The expression and activity of MMP-9 and MMP-3 in the extracellular matrix is increased in patients with pSS; there is an imbalance noted between their activity and their inhibitor (TIMP). There is more extensive damage to the acini when the MMP/TIMP ratio is high, regardless of the number of inflammatory foci.²¹

Factor NF- κ B activates genes associated with apoptosis such as Fas ligand and p53.^{8,22} Apoptosis would play a significant role, as well, through the expression of apoptosis-regulating proteins. The co-expression of suppressor gene p53 and its transcription factor p21 in the ductal epithelium is noteworthy, for these would act as defence mechanisms in the ductal cells adjacent to lymphocytic infiltrates, preventing their apoptosis. The fact that they are not expressed in acinar cells would favour damage to these cells.

We suggest that the nuclear translocation of factor NF- κ B in lymphocytes found in the inflammatory infiltrates characteristic of the minor salivary glands in patients with pSS would induce transcription of the genes for proinflammatory cytokines such as TNF- α and IL-1 β and their resultant secretion into the extracellular space. These cytokines would act upon cell membrane receptors in the acini and ducts adjacent to the infiltrates, inducing the nuclear

translocation of NF- κ B in these cells. These proinflammatory cytokines would not activate the cells of acini and ducts distant from the inflammatory focus.

With regard to the acinar and ductal cells adjacent to inflammatory foci, we also suggest that acinar destruction in the absence of ductal destruction could be explained by the greater production of MMP in acinar cells in comparison with ductal cells and the activation of Fas-Fas ligand in acinar cells; both these actions are mediated by the translocation of factor NF- κ B, which would account for the progressive destruction of acinar cells. On the other hand, co-expression of suppressor gene p53 and its transcription factor p21, both anti-apoptotic, would protect the integrity of ductal structures.

Funding

Universidad de Buenos Aires. UBA CyT 403.

Conflict of interest

The authors declare that they have no conflicts of interest.

Acknowledgements

Graciela Zaccagnini for technical assistance.

References

1. Talal N. Sjogren's syndrome. *Curr Opin Immunol.* 1989;2:622-4.
2. Fox RI. Sjogren's syndrome. *Curr Opin Rheumatol.* 1995;7:409-16.
3. Vitali C, Bombardieri S, Moutsopoulos HM, Coll J, Gerli R, Hatron PY, et al. Assessment of the European classification criteria for Sjogren's syndrome in a series of clinically defined cases: results of a prospective multicentre study. The European Study Group on Diagnostic Criteria for Sjogren's Syndrome. *Ann Rheum Dis.* 1996;55:116-21.
4. Brun JG, Madland TM, Gjesdal CB, Bertelsen LT. Sjogren's syndrome in an out-patient clinic: classification of patients according to the preliminary European criteria and the proposed modified European criteria. *Rheumatology (Oxford).* 2002;41:301-4.
5. Bloch KJ, Buchanan WW, Wohl MJ, Bunim JJ. Sjogren's syndrome. A Clinical, pathological, and serological study of sixty-two cases. *Medicine (Baltimore).* 1965;44:187-231.
6. Daniels TE. Salivary histopathology in diagnosis of Sjogren's syndrome. *Scand J Rheumatol Suppl.* 1986;61:36-43.
7. Fox RI. Sjogren's syndrome. *Lancet.* 2005;366:321-31.
8. Hansen A, Lipsky PE, Dörner T. New concepts in the pathogenesis of Sjogren syndrome: many questions, fewer answers. *Curr Opin Rheumatol.* 2003;15:563-70.
9. Bacman S, Berra A, Sterin-Borda L, Borda E. Muscarinic acetylcholine receptor antibodies as a new marker of dry eye Sjogren syndrome. *Invest Ophthalmol Vis Sci.* 2001;42:321-7.
10. Watanabe T, Tsuchida T, Kanda N, Mori K, Hayashi Y, Tamaki K. Anti-alpha-fodrin antibodies in Sjogren syndrome and lupus erythematosus. *Arch Dermatol.* 1999;135:535-9.
11. Sarkar FH, Li Y, Wang Z, Kong D. NF-kappaB signaling pathway and its therapeutic implications in human diseases. *Int Rev Immunol.* 2008;27:293-319.
12. Brown KD, Claudio E, Siebenlist U. The roles of the classical and alternative nuclear factor-kappaB pathways: potential implications for autoimmunity and rheumatoid arthritis. *Arthritis Res Ther.* 2008;10:212.
13. Manoussakis MN, Dimitriou ID, Kapsogeorgou EK. Expression of B7 costimulatory molecules by salivary gland epithelial cells in patients with Sjogren's syndrome. *Arthritis Rheum.* 1999;42:229-39.
14. Vitali C, Bombardieri S, Jonsson R, Moutsopoulos HM, Alexander EL, Carsons SE, et al. Classification criteria for Sjogren's syndrome: a revised version of the European criteria proposed by the American-European Consensus Group. *Ann Rheum Dis.* 2002;61:554-8.
15. Chisholm DM, Mason DK. Labial salivary gland biopsy in Sjogren's disease. *J Clin Pathol.* 1968;21:656-60.
16. Hayden MS, Ghosh S. Signaling to NF-kappaB. *Genes Dev.* 2004;18:2195-224.
17. Perez P, Kwon YJ, Alliende C, Leyton L, Aguilera S, Molina C, et al. Increased acinar damage of salivary glands of patients with Sjogren's syndrome is paralleled by simultaneous imbalance of matrix metalloproteinase 3/tissue inhibitor of metalloproteinases 1 and matrix metalloproteinase 9/tissue inhibitor of metalloproteinases 1 ratios. *Arthritis Rheum.* 2005;52:2751-60.
18. Lucas PC, McAllister-Lucas LM, Nunez G. NF-kappaB signaling in lymphocytes: a new cast of characters. *J Cell Sci.* 2004;117:31-9.
19. Ek M, Popovic K, Harris HE, Nacler CS, Wahren-Herlenius M. Increased extracellular levels of the novel proinflammatory cytokine high mobility group box chromosomal protein 1 in minor salivary glands of patients with Sjogren's syndrome. *Arthritis Rheum.* 2006;54:2289-94.
20. Pullerits R, Jonsson IM, Verdrengh M, Bokarewa M, Andersson U, Erlandsson-Harris H, et al. High mobility group box chromosomal protein 1, a DNA binding cytokine, induces arthritis. *Arthritis Rheum.* 2003;48:1693-700.
21. Azuma M, Motegi K, Aota K, Hayashi Y, Sato M. Role of cytokines in the destruction of acinar structure in Sjogren's syndrome salivary glands. *Lab Invest.* 1997;77:269-80.
22. Martindale JL, Holbrook NJ. Cellular response to oxidative stress: signaling for suicide and survival. *J Cell Physiol.* 2002;192:1-15.