

Letters to the Editor

Strontium Ranelate Improves Osteointegration of a Hip Prosthesis[☆]

El ranelato de estroncio mejora la osteointegración de una prótesis de cadera

Dear Editor,

The aseptic displacement of a prosthesis is one of the most common complications of orthopedic surgery; sometimes patients require reintervention.

We report the case of an 83 year old woman with a history of postmenopausal osteoporosis with weekly bisphosphonate treatment and daily intake of calcium and vitamin D and a hip fracture right at 64, treated with a cemented prosthesis. She attended the clinic due to mechanical right hip pain with claudication, progressing in months. On examination we found limitation and pain on right hip rotation. We performed a hip X-ray (Fig. 1) and, suspecting aseptic displacement of the prosthesis, bone scintigraphy was performed in 3 phases showing uptake in the distal third (Fig. 2a), confirming the diagnosis. We started treatment with strontium ranelate plus calcium and vitamin D. After 2 months, the patient improved significantly and her claudication disappeared. At 6 months, the bone scan was repeated, which showed a reduction to close to normal of the increased uptake seen at baseline (Fig. 2b).

Due to the aging of the population, there is an increase of patients undergoing joint replacement surgery. Stable and lasting fixation of the prosthesis depends, among other factors, on the surgical technique used, the characteristics of the implant surface which contacts the bone and bone quantity and quality in the patient. One of the most common complications is the displacement of the prosthesis, especially in patients with osteoporosis. It is therefore expected that therapies directed at improving bone microarchitecture and increase bone mass facilitate osteointegration of the prosthesis.¹

Strontium ranelate, used to prevent osteoporotic fractures,² has been shown effective in improving prosthesis osteointegration in animals.^{3,4} However, to date there are no studies assessing its effects in humans for this same purpose. Thus, the case presented here provides data suggesting that strontium ranelate can be beneficial for osteointegration of a hip prosthesis. The substantial improvement in symptoms just 2 months after treatment onset with normalization of bone scan at 6 months are promising and suggest its potential application in orthopedic surgery.

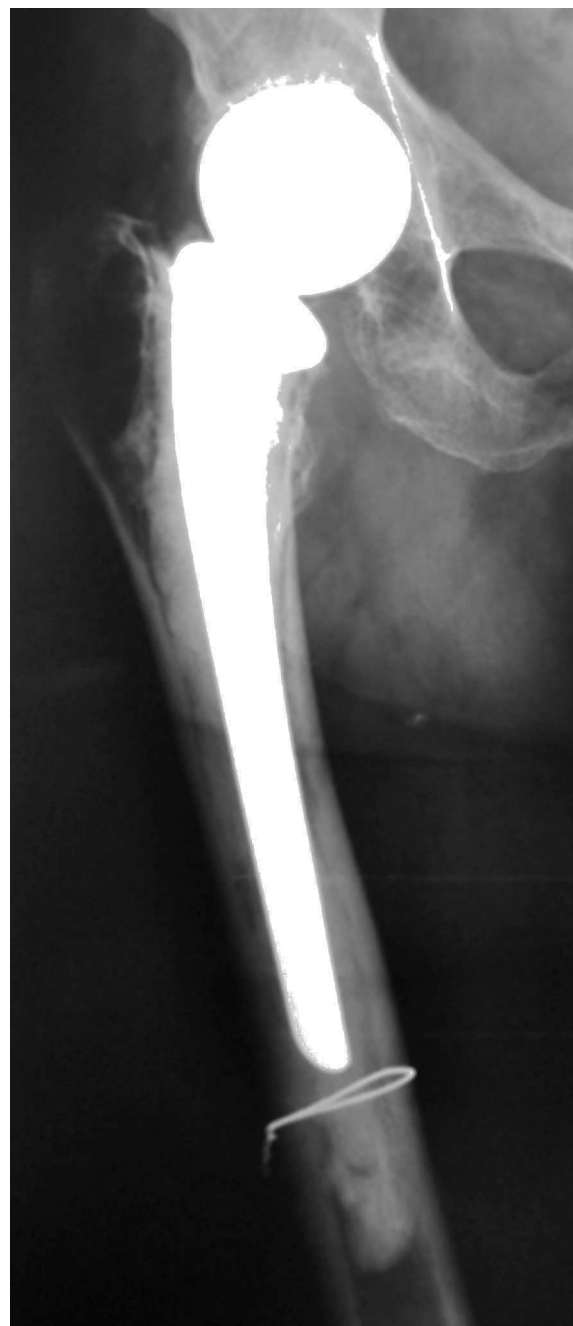

Fig. 1. X-ray of hip prosthesis.

[☆] Please cite this article as: León Rubio P, Baturone Castillo M. El ranelato de estroncio mejora la osteointegración de una prótesis de cadera. Reumatol Clin. 2013;9:326–327.

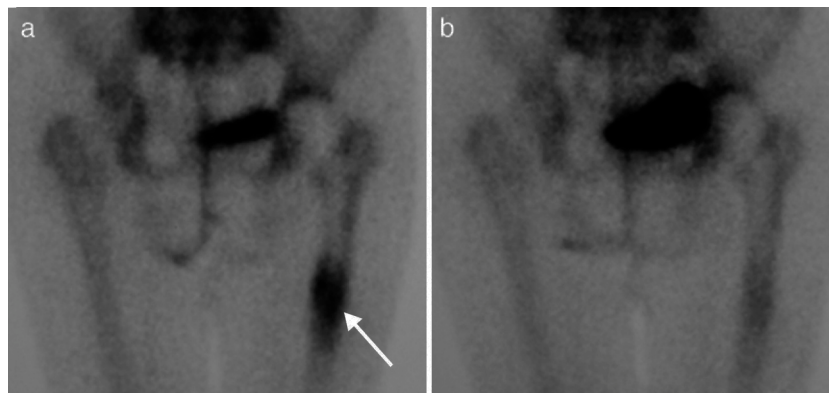


Fig. 2. (a) Bone scan showing displacement of the prosthesis at the femoral shaft level (arrow). (b) Same patient after 6 months of treatment with strontium ranelate.

Conflict of interest

The authors have no conflict of interest to declare.

References

1. Albrektsson T, Johansson C. Osteoinduction, osteoconduction and osseointegration. *Eur Spine J.* 2001;10 Suppl. 2:S96–101.
2. Reginster JY, Seeman E, De Vernejoul MC, Adami S, Compston J, Phenekos C, et al. Strontium Ranelate reduces the risk of nonvertebral fractures in postmenopausal women with osteoporosis Treatment Of Peripheral Osteoporosis (TROPOS) study. *J Clin Endocrinol Metab.* 2005;90:2816–22.
3. Maïmoun L, Brennan TC, Badoud I, Dubois-Ferriere V, Rizzoli R, Ammann P. Strontium ranelate improves implant osteointegration. *Bone.* 2010;46:1436–41.
4. Li Y, Feng G, Gao Y, Luo E, Liu X, Hu J. Strontium ranelate treatment enhances hydroxyapatitecoated titanium screws fixation in osteoporotic rats. *J Orthop Res.* 2010;28:578–82.

Piedad León Rubio,* Manuel Baturone Castillo

Centro de Enfermedades del Aparato Locomotor, Sevilla, Spain

* Corresponding author.

E-mail address: piedad.leonrubio@gmail.com (P. León Rubio).

Idiopathic Hypophosphatemic Osteomalacia[☆]

Osteomalacia hipofosfatémica idiopática

Dear Editor,

Osteomalacia is a rare metabolic bone disorder which can be caused by various diseases associated with a deficiency of calcium, phosphorus or an inhibition of the mineralization process.¹ We report the case of a 62-year patient presenting hypophosphatemic osteomalacia diagnosed through laboratory data, with no clear etiology, classified as idiopathic.

The patient exhibited bilateral hip fractures of a non traumatic origin and had received a prosthesis which had undergone mobilization. He presented muscle and bone pain lasting 3 years that limited movement. She reported no dentition or audiological changes, no prior medication or family history of kidney or bone disease.

Laboratory analysis showed: normal CBC and venous blood gases, renal and hepatic profiles were normal except for elevated alkaline phosphatase (443 IU/L for $n < 136$), normocalcemia and hypophosphatemia 0.60 mmol/L ($n = 0.7–1.60$) and elevated iPTH (79.8 ng/L for $n < 67$) with normal values of 1.25 OHD and 25(OH)₂D. The 24-h urine had normal calcium and phosphate, with no other useful information. Hydroxyprolinuria of 41.4 mg/L ($< 17/24$ h/m²).

Suspecting hypophosphatemic osteomalacia we obtained the following test results in search of its etiology: normal serum protein on electrophoresis with absence of Bences Jones protein in the urine, normal tumor markers (carcinoembryonic antigen

CEA, 15.3, 19.9, 125, alphaglycoprotein); we studied the patient for possible digestive malabsorption syndrome (endoscopic, X-ray study, histological and celiac antibodies) but results were negative; parathyroid study (neck ultrasound and sestamibi scintigraphy) was normal as were chest X-rays and abdominal ultrasound; a bone scan with Tc⁹⁹ showed multiple uptake areas in the ribs, heel, and periprosthetically in both hips and peripheral joints (Fig. 1). Suspecting a possible oncogenic cause we performed an 11 in.-octreotide scintigraphy for the detection of somatostatin receptors which resulted negative. Bone mineral density (BMD) of the lumbar spine (L2–L4) was 0.596 g/m² with a T score of –4.74. We did not study the levels of fibroblast growth factor (FGF-23).

We started treatment with calcitriol (0.75 mcg/24 h) and sodium phosphate (Phosphate-Sandoz[®], 2 g/24 h) achieving normalization of blood phosphorus levels, iPTH and FA, with subsequent hyperphosphaturia in urine 24 h (2538 mg/L) which had not previously been observed. After this parameter normalized we added strontium ranelate treatment for the treatment of osteoporosis. The patient's symptoms gradually improved. Three years after the diagnosis, after initiating treatment, the patient can walk, mineral metabolism analytical controls are normal as well as the Tc⁹⁹ bone scintigraphy. The latest lumbar spine densitometry (L2–L4) shows 0.744 g/m², with a T score of –2.93 and a –0.82 Z score.

The parameters studied suggest that this case corresponds to osteomalacia characterized by insufficient mineralization of the osteoid formation in new bone metabolism points. Different diseases can lead to osteomalacia through mechanisms that cause hypocalcemia, hypophosphatemia or defects in the mineralization process.¹ In this case, the slight decrease in phosphoremia suggests that it is hypophosphatemic osteomalacia. Interestingly, phosphoremia was initially accompanied with normality of phosphaturia probably due to a severe depletion of phosphate reserves, responsible in turn of the evolved osteomalacia process with atraumatic fractures and crippling myopathy.

[☆] Please, cite this article as: León Rubio P, Baturone Castillo M. Osteomalacia hipofosfatémica idiopática. *Reumatol Clin.* 2013;9:327–328.