

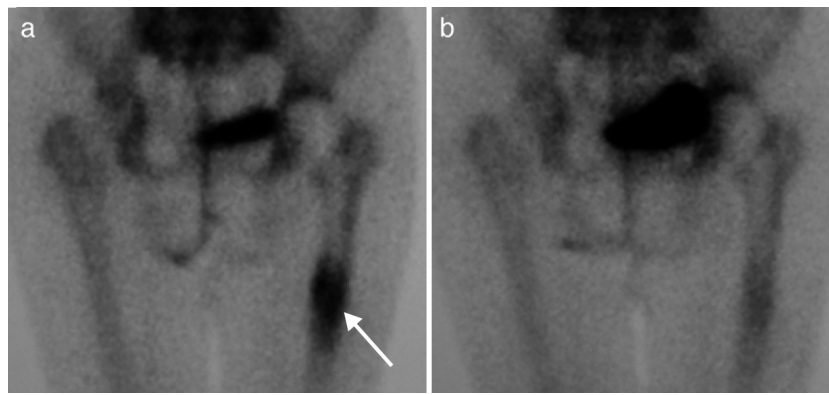Fig. 2. (a) Bone scan showing displacement of the prosthesis at the femoral shaft level (arrow). (b) Same patient after 6 months of treatment with strontium ranelate.

Conflict of interest

The authors have no conflict of interest to declare.

References

- Albrektsson T, Johansson C. Osteoinduction, osteoconduction and osseointegration. *Eur Spine J.* 2001;10 Suppl. 2:S96–101.
- Reginster JY, Seeman E, De Vernejoul MC, Adami S, Compston J, Phenekos C, et al. Strontium Ranelate reduces the risk of nonvertebral fractures in postmenopausal women with osteoporosis Treatment Of Peripheral Osteoporosis (TROPOS) study. *J Clin Endocrinol Metab.* 2005;90:2816–22.
- Maïmoun L, Brennan TC, Badoud I, Dubois-Ferriere V, Rizzoli R, Ammann P. Strontium ranelate improves implant osteointegration. *Bone.* 2010;46:1436–41.
- Li Y, Feng G, Gao Y, Luo E, Liu X, Hu J. Strontium ranelate treatment enhances hydroxyapatite-coated titanium screws fixation in osteoporotic rats. *J Orthop Res.* 2010;28:578–82.

Piedad León Rubio,* Manuel Baturone Castillo

Centro de Enfermedades del Aparato Locomotor, Sevilla, Spain

* Corresponding author.

E-mail address: piedad.leonrubio@gmail.com (P. León Rubio).

Idiopathic Hypophosphatemic Osteomalacia[☆]

Osteomalacia hipofosfatémica idiopática

Dear Editor,

Osteomalacia is a rare metabolic bone disorder which can be caused by various diseases associated with a deficiency of calcium, phosphorus or an inhibition of the mineralization process.¹ We report the case of a 62-year patient presenting hypophosphatemic osteomalacia diagnosed through laboratory data, with no clear etiology, classified as idiopathic.

The patient exhibited bilateral hip fractures of a non traumatic origin and had received a prosthesis which had undergone mobilization. He presented muscle and bone pain lasting 3 years that limited movement. She reported no dentition or audiological changes, no prior medication or family history of kidney or bone disease.

Laboratory analysis showed: normal CBC and venous blood gases, renal and hepatic profiles were normal except for elevated alkaline phosphatase (443 IU/L for $n < 136$), normocalcemia and hypophosphatemia 0.60 mmol/L ($n = 0.7–1.60$) and elevated iPTH (79.8 ng/L for $n < 67$) with normal values of 1.25 OHD and 25(OH)₂D. The 24-h urine had normal calcium and phosphate, with no other useful information. Hydroxyprolinuria of 41.4 mg/L ($< 17/24$ h/m²).

Suspecting hypophosphatemic osteomalacia we obtained the following test results in search of its etiology: normal serum protein on electrophoresis with absence of Bence Jones protein in the urine, normal tumor markers (carcinoembryonic antigen

CEA, 15.3, 19.9, 125, alphaglycoprotein); we studied the patient for possible digestive malabsorption syndrome (endoscopic, X-ray study, histological and celiac antibodies) but results were negative; parathyroid study (neck ultrasound and sestamibi scintigraphy) was normal as were chest X-rays and abdominal ultrasound; a bone scan with Tc⁹⁹ showed multiple uptake areas in the ribs, heel, and periprosthetically in both hips and peripheral joints (Fig. 1). Suspecting a possible oncogenic cause we performed an 11 in.-octreotide scintigraphy for the detection of somatostatin receptors which resulted negative. Bone mineral density (BMD) of the lumbar spine (L2–L4) was 0.596 g/m² with a T score of –4.74. We did not study the levels of fibroblast growth factor (FGF-23).

We started treatment with calcitriol (0.75 mcg/24 h) and sodium phosphate (Phosphate-Sandoz[®], 2 g/24 h) achieving normalization of blood phosphorus levels, iPTH and FA, with subsequent hyperphosphaturia in urine 24 h (2538 mg/L) which had not previously been observed. After this parameter normalized we added strontium ranelate treatment for the treatment of osteoporosis. The patient's symptoms gradually improved. Three years after the diagnosis, after initiating treatment, the patient can walk, mineral metabolism analytical controls are normal as well as the Tc⁹⁹ bone scintigraphy. The latest lumbar spine densitometry (L2–L4) shows 0.744 g/m², with a T score of –2.93 and a –0.82 Z score.

The parameters studied suggest that this case corresponds to osteomalacia characterized by insufficient mineralization of the osteoid formation in new bone metabolism points. Different diseases can lead to osteomalacia through mechanisms that cause hypocalcemia, hypophosphatemia or defects in the mineralization process.¹ In this case, the slight decrease in phosphoremia suggests that it is hypophosphatemic osteomalacia. Interestingly, phosphoremia was initially accompanied with normality of phosphaturia probably due to a severe depletion of phosphate reserves, responsible in turn of the evolved osteomalacia process with atraumatic fractures and crippling myopathy.

[☆] Please, cite this article as: León Rubio P, Baturone Castillo M. Osteomalacia hipofosfatémica idiopática. *Reumatol Clin.* 2013;9:327–328.

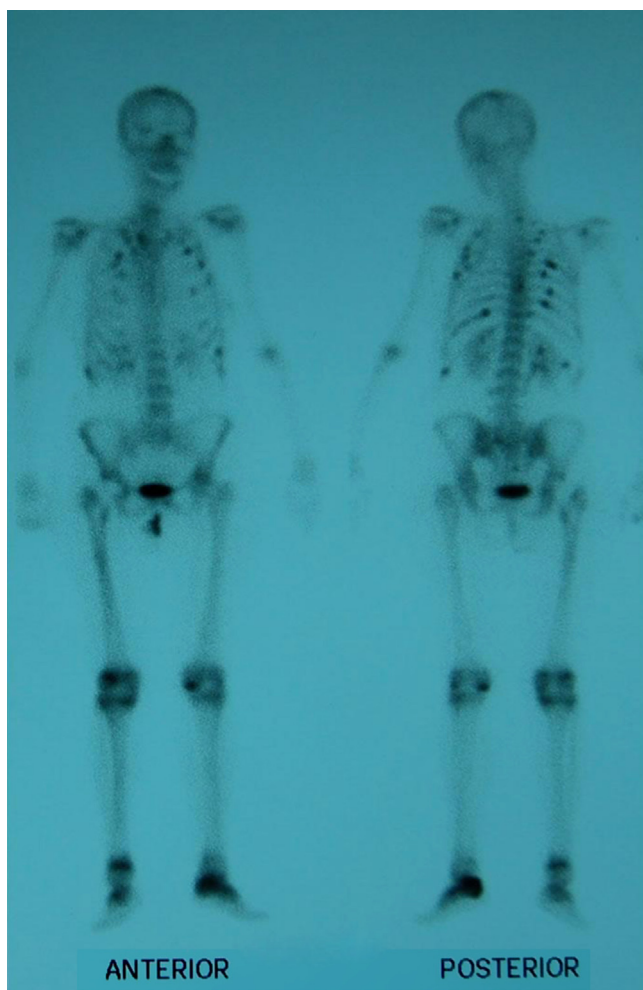


Fig. 1. Scintiscan Uptake in Multiple Ribs, Fractured Left Hip, Left Calcaneus and Peripheral Joints.

The case of the patient under study is remarkable because it was not associated with any of the causes described in hypophosphatemic osteomalacia^{1–4}: (i) no family history or other evidence of heredity (e.g. abnormal dentition), (ii) no deficit of phosphate

in the diet, (iii) or an association with any drug, (iv) no abnormalities were found that made us suspect a parathyroid endocrine origin; (v) no digestive malabsorption disorders or (vi) kidney problems; (vii) finally, the normality of 11 in.-octreotide scintigraphy, tumor markers, Bences Jones proteins in the urine, and abdominal ultrasonography Chest X-rays suggest an unlikely oncogenic source.

We could not, to date, find the mechanism that caused the disturbance, which require us to classify it as idiopathic and keep looking for new possible causes of this disease. Known cases of idiopathic hypophosphatemic osteomalacia are rare.^{5,6} However, treatment based on phosphate supplementation has been effective in stabilizing blood phosphorus levels, but leads to a mild phosphaturia, to be expected based on the contribution.

Conflict of Interest

The authors have no disclosures to make.

References

1. Lips P, van Schoor NM, Bravenboer N. Vitamin D-related disorders. In: Rosen CJ, editor. Primer on the metabolic bone diseases and disorders of mineral metabolism, seventh ed. Washington, DC: American Society of Bone and Mineral Research; 2008. p. 329.
2. Gifre L, Peris P, Monegal A, Martinez de Osaba MJ, Alvarez L, Guañabens N. Osteomalacia revisited: a report on 28 cases. Clin Rheumatol. 2011;30: 639–45.
3. Bhan A, Rao AD, Rao DS. Osteomalacia as a result of vitamin D deficiency. Endocrinol Metab Clin North Am. 2010;39:321–31.
4. Basha B, Rao DS, Han ZH, Parfitt AM. Osteomalacia due to vitamin D depletion: a neglected consequence of intestinal malabsorption. Am J Med. 2000;108:296–300.
5. Dent CE, Friedman M. Hypophosphatemic osteomalacia with complete recovery. Br Med J. 1964;1:1676–9.
6. Paterson CR, Naismith KI, Young JA. Severe unexplained hypophosphatemia. Clin Chem. 1992;38:104–7.

Piedad León Rubio,* Manuel Baturone Castillo

Servicio de Reumatología, Centro de Enfermedades del Aparato Locomotor, Sevilla, Spain

* Corresponding author.

E-mail address: piedad.leonrubio@gmail.com (P. León Rubio).

Agomelatine Adjunctive Therapy for Fibromyalgia[☆]

Uso de agomelatina como tratamiento coadyuvante en la fibromialgia

Dear Editor:

Fibromyalgia is a chronic disease that can affect the patient from a biological, psychological and social point of view.¹ It includes symptoms such as extreme fatigue, persistent pain, stiffness of muscles, tendons and soft tissue, trouble sleeping, memory disturbances, depression and anxiety, among others.²

The antidepressant agomelatine is an agonist of MT1 and MT2 melatonergic receptors³ and antagonist of postsynaptic

serotonin receptors (5-HT_{2C}), with the ability to “resynchronize” the biological clock.^{4,5}

Based on empirical observation of several rheumatologists of San Cristóbal (Venezuela) on the apparent efficacy of agomelatine in fibromyalgia resistant to conventional treatment, we present a case of a 43 year old female patient, diagnosed with fibromyalgia 3 years prior, and treated with L-arginine base, pregabalin, amitriptyline, tryptophan, meloxicam and B vitamin complex. Since no therapy had proven effective pharmacotherapy we indicated agomelatine 25 mg at bedtime as adjuvant treatment and an amitriptyline substitute. The case was followed for 16 weeks and assessed with the following instruments: Fibromyalgia Impact Questionnaire (FIQ), LANSS pain scale, Pittsburgh sleep quality index and the widespread pain index.

Initially, the patient was impaired with physical appearance, sleeplessness, muscle aches and fatigue. In week 2 appreciate a clear improvement in the aforementioned parameters. At six weeks the improvement in sleep disturbance was clinically significant and sleep latency was reduced from 15 to 5 min and increased night-

[☆] Please cite this article as: Medina Ortiz O, et al. Uso de agomelatina como tratamiento coadyuvante en la fibromialgia. Reumatol Clin. 2013;9:328–329.