

Original article

## Central Nervous System Infection by *Listeria monocytogenes* in Patients With Systemic Lupus Erythematosus: Analysis of 26 Cases, Including the Report of a New Case<sup>☆</sup>

Gabriel Horta-Baas,<sup>a,\*</sup> Omar Guerrero-Soto,<sup>b</sup> Leonor Barile-Fabris<sup>b</sup><sup>a</sup> Servicio de Reumatología, Hospital General Regional 220, Instituto Mexicano del Seguro Social, Toluca de Lerdo, Estado de México, Mexico<sup>b</sup> Servicio de Reumatología, Hospital de Especialidades, Centro Médico Nacional Siglo XXI, Instituto Mexicano del Seguro Social, Mexico City, Mexico

## ARTICLE INFO

## Article history:

Received 27 January 2013

Accepted 17 April 2013

Available online 25 October 2013

## Keywords:

Systemic lupus erythematosus

Meningitis

Brain abscess

*Listeria monocytogenes*

## ABSTRACT

**Introduction:** Infections in patients with systemic lupus erythematosus cause significant morbidity. Infection due to *Listeria monocytogenes* is considered an opportunistic disease, and has been published on rare occasions in patients with SLE.

**Objective:** To review the presentation of listeria infections in the central nervous system (CNS) in SLE patients.

**Methodology:** We conducted a literature review, selecting cases with central nervous system infection and confirmation of LM infection through culture.

**Results:** Twenty six cases are described. The most common presentation was meningitis, with meningoen- cephalitis and brain abscesses being less frequent. The predisposing factors are: use of glucocorticoids, immunosuppressants, renal replacement therapy and the activity flares.

**Conclusion:** CNS infection by listeria is rare and sometimes fatal. The atypical presentation may lead to a delay in diagnosis and appropriate treatment. *L. monocytogenes* should be included in the differential diagnosis of patients with SLE with neurological manifestations.

© 2013 Elsevier España, S.L. All rights reserved.

### Infección del sistema nervioso central por *Listeria monocytogenes* en pacientes con lupus eritematoso sistémico: análisis de 26 casos, incluyendo el reporte de un caso nuevo

## RESUMEN

**Introducción:** Las infecciones en pacientes con lupus eritematoso sistémico (LES) causan morbilidad significativa. La infección por *Listeria monocytogenes* (*L. monocytogenes*) se considera una enfermedad oportunista y ha sido publicada en raras ocasiones en pacientes con LES.

**Objetivo:** Revisar la forma de presentación de las infecciones por *Listeria* a nivel del sistema nervioso central (SNC) en pacientes con LES.

**Metodología:** Se realizó una revisión bibliográfica, seleccionando los casos con cuadro de afección al sistema nervioso y confirmación de infección por *L. monocytogenes* en el cultivo.

**Resultados:** Veintiséis casos son descritos. La forma de presentación más común fue la meningitis, siendo la meningoencefalitis y los abscesos cerebrales menos frecuentes. Los factores predisponentes son: empleo glucocorticoides, inmunosupresores, terapia de sustitución renal y el brote de actividad.

**Conclusión:** La infección del SNC por *Listeria* es poco común y, en ocasiones, fatal. La presentación atípica puede conducir a un retraso en el diagnóstico y el tratamiento adecuado. *L. monocytogenes* debe incluirse en el diagnóstico diferencial del paciente con LES y manifestaciones neurológicas.

© 2013 Elsevier España, S.L. Todos los derechos reservados.

## Palabras clave:

Lupus eritematoso sistémico

Meningitis

Absceso cerebral

*Listeria monocytogenes*

<sup>☆</sup> Please cite this article as: Horta-Baas G, Guerrero-Soto O, Barile-Fabris L. Infección del sistema nervioso central por *Listeria monocytogenes* en pacientes con lupus eritematoso sistémico: análisis de 26 casos, incluyendo el reporte de un caso nuevo. Reumatol Clin. 2013;9:340–347.

\* Corresponding author.

E-mail address: [gabho@hotmail.com](mailto:gabho@hotmail.com) (G. Horta-Baas).

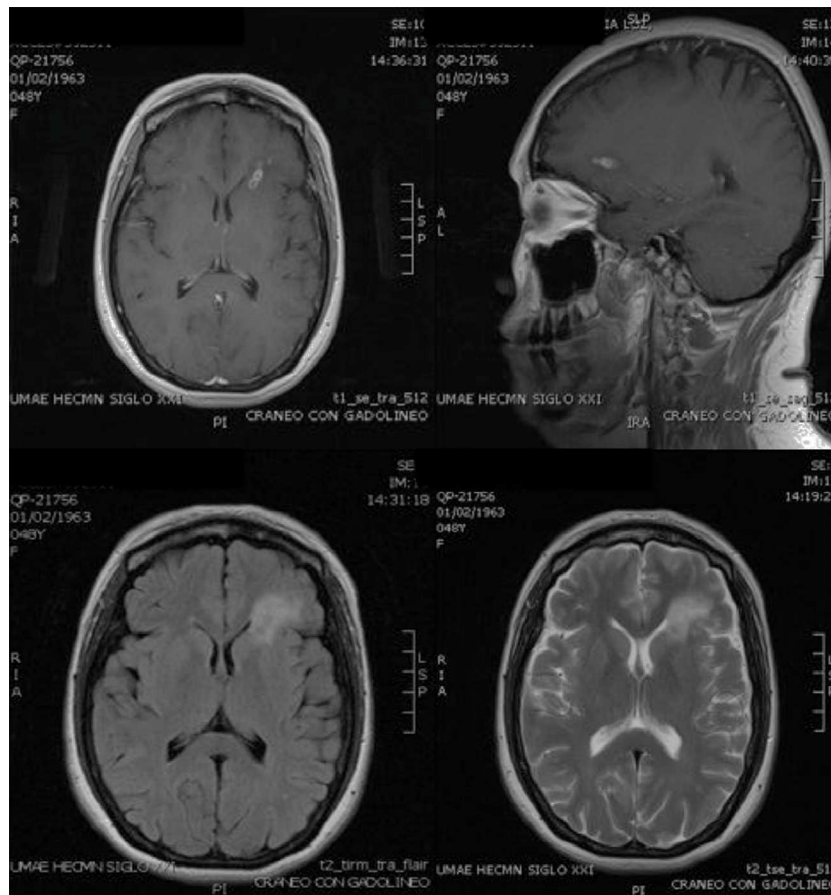
## Introduction

*Listeria monocytogenes* (LM) is a Gram-positive rod widely found in nature. Human listeriosis is a rare disease with a global annual incidence of 0.2 to 7.4 million.<sup>1</sup> In healthy populations, the highest rates of infection are seen in children aged one month and in adults over 60 years. Infections occurring outside the perinatal period happen in patients with hematologic malignancies, HIV infection or transplant patients or those treated with glucocorticoids (GC).<sup>2</sup> The ingestion of contaminated food is the most common cause.<sup>3–5</sup> In immunocompetent persons, infection produces self-limited diarrhea or flu, while in immunocompromised patients it may start as febrile gastroenteritis with bacteremia and subsequent seeding of bacilli to other organs. It shows tropism for the central nervous system (CNS), meningitis being the most common form of expression, although thromboencephalitis may be characteristic.<sup>4</sup> CNS infection by LM has been published on rare occasions in patients with systemic lupus erythematosus (SLE)<sup>6–14</sup> considered as of interest to the reader because it is included among the variety of differential diagnoses that should be considered in patients with SLE and neurological manifestations, as well as because its significant mortality. Given the rarity of this condition, we present a case diagnosed in our hospital as well as a review of the pathogenesis, clinical spectrum, diagnostic aids and treatment available, related to the topic.

## Case Report

The patient was a 47-year-old woman diagnosed with SLE 10 years ago, with an outbreak of renal activity one year prior to

admission that required treatment with mycophenolate mofetil (MMF) 3 g daily, prednisone 1 mg/kg with reduction to 0.5 mg/kg/day, achieving disease activity remission. She was admitted with sudden onset headache, with an intensity of 9/10 on the visual analog scale, exacerbated with movement and no improvement with analgesics, accompanied by fever and nausea. Upon physical examination, she had no alterations in consciousness, impairment of higher mental functions or focal neurological data and presented negative meningeal signs. Study of the cerebrospinal fluid (CSF) showed leukocytes  $27 \text{ mm}^{-3}$  (80% mononuclear), RBC  $45 \text{ mm}^{-3}$ , protein levels, normal CSF glucose, other tests and Gram stain were negative, IgM and IgG antibodies to cytomegalovirus and herpes virus were negative. Laboratory studies showed leukocytosis  $13\,000 \text{ cel./Mm}^3$  with neutrophilia and monocytosis, low C3 levels with normal C4, elevated titers of anti-DNA, urinalysis with proteinuria, microhematuria and negative cylinders. The initial diagnosis was neuroinfection vs neuropsychiatric SLE activity; we began empirical treatment with ceftriaxone 2 g every 12 h, vancomycin 1 g every 12 h, acyclovir 600 mg every 8 h, dexamethasone 8 mg every 8 h. Magnetic resonance imaging (MRI) of the brain showed, on the frontal lobe, an injury consistent with a brain abscess (Fig. 1). At 48 h the CSF was reported colorless, no leukocytes, erythrocytes 15, protein 39 mg/dl and normal CSF glucose, PCR for *M. tuberculosis* was negative. After 4 days, LM growth was reported in the CSF, negative blood cultures, leading to a change in treatment ampicillin 2 g intravenously every 4 h for 6 weeks, with complete resolution without sequelae. A cerebral MRI after one month showed a nodular impregnation



**Fig. 1.** MRI on admission: CSF spaces, cerebellum, medulla, pons, midbrain, corpus callosum and right hemisphere are normal. In the left hemisphere, at the level of the deep white matter of the frontal lobe, there is an area of hypo-hyperintense signal in T1 and T2, respectively, with an “edematous” bilobed appearance measuring approximately  $17 \times 6 \text{ mm}$ , surrounded by vasogenic edema and that intensely permeates annularly after application of intravenous contrast. Changes are compatible with neuroinfection. Bilobed left frontal abscess.

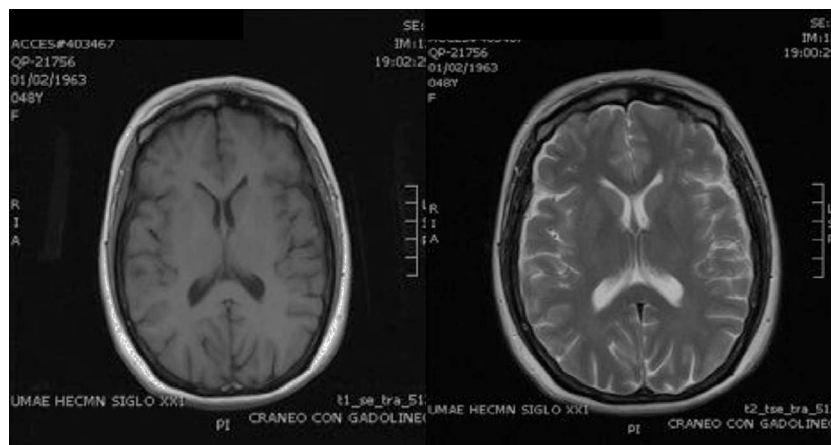


Fig. 2. Gadolinium-enhanced brain MRI at 4 months since initiation of treatment with resolution of the lesions with no evidence of neuroinfection.

area 3 mm diameter situated frontally with minimal adjacent edema. At 4 months there was evidence of the infectious process (Fig. 2).

### Methodology

A literature review was performed in Medline via Pubmed, with the following information as search terms: meningitis, brain abscess, lysteriosis, SLE, CNS infections. It was limited to articles published in English and Spanish. We selected all cases with CNS clinical symptoms and microbiological confirmation of infection with LM in the culture, and which possessed a case description.

### Results

We found 26 described cases, of which 22 resulted in meningitis (85%), 2 in meningoencephalitis (8%) and 5 in cerebral abscess (19%) without any rhomboencephalitis case (Table 1). The most common presentations in patients with meningitis/meningoencephalitis were fever (90%), headache (78%), alteration of consciousness (70%), nausea (60%), vomiting (64%), meningeal signs (53%), diarrhea (50%) and focal neurological signs (41.6%). Patients with brain abscess had fever (100%), headache (100%), meningeal signs (33%), altered mental status (33%), nausea (100%), focal neurological signs (50%) and vomiting (33%) and in no case a history of diarrhea was reported (Table 2).

Pleocytosis was found in the CSF in 100% of the 12 cases where this information was available, ranging from 27 to 3664 cel./Mm<sup>3</sup>. In 5 of 8 cases we predominantly found polymorphonuclear cells and mononuclear cells showed predominance in 3. 4 cases reported erythrocyte counts and all reported increased thereof. Protein levels were available in 7 cases, with elevated protein in 100% 116–399 mg/dl and in 4 of 6 low CSF glucose levels. Gram staining was available in 5 cases, all negative. In 21 of 25 patients (84%) *Listeria* growth was reported in CSF culture and in 14 of 23 (61%) it was found in blood samples (Table 3). Three patients had meningitis not associated to the use of GC or immunosuppressants; one case was a patient with newly diagnosed SLE and the other 2 were on hemodialysis, without evidence of SLE activity. Information on treatment for meningitis/meningoencephalitis was available in 21 cases and in 3 of 5 cases of brain abscess. In patients with meningitis/meningoencephalitis, 18 were treated with GC and 8 with cytotoxic drugs; in patients with brain abscess, 100% were treated with immunosuppressive medication, with a single patient requiring the use of prednisone, and 2 patients combining prednisone with MMF (Table 1).

Ampicillin, alone or in combination with an aminoglycoside, was the most widely used treatment (Table 3). The most common complication was hydrocephalus (n = 3), 5 cases reported the presence of focal neurological signs, including 2 patients who died and another 2 who persisted with sequelae. One patient reported the cure of the infectious process without apparent sequelae, but died after 4 months with symptoms of acute hepatitis. A patient with meningitis persisted with diplopia and facial weakness; another patient progressed to meningitis and multiple brain abscesses presented and, as a complication, presented right facial hemiparesis and hypoalgesia of the right side of the body. The mortality rate was 27%.

### Discussion

Infections remain a major cause of morbidity and mortality in patients with lupus because of the susceptibility to opportunistic infections due to immune dysfunction related to the disease or its treatment. CNS infections are not common in these patients, with an estimated prevalence of 0.53%–2.25%,<sup>15–18</sup> with *M. tuberculosis*, *C. neoformans* and LM constituting the most common pathogens. Presenting symptoms may resemble a neuropsychiatric lupus flare, which makes diagnosis difficult. Wong et al. reported that 50% of episodes of neuropsychiatric SLE symptoms were caused by a systemic infection of the CNS.<sup>19</sup>

The association of *Listeria* and SLE has rarely been published in<sup>20,21</sup> patients without steroid treatment and/or immunosuppressive drugs.<sup>7,11,15</sup> Mook et al. reported a relative risk of *Listeria* meningitis in patients with systemic connective tissue diseases of 18.3 (12.6 to 26.6).<sup>22</sup> Harisdangkul et al. reported that lysteriosis is uncommon in SLE and the most common form is bacteremia, found mainly in patients with renal failure and pregnancy, the latter constituting predisposing factors for lysteriosis in June.

The intracellular life cycle may explain the predilection for immunocompromised hosts. LM virulence allows it not only to penetrate into various cell types, but to avoid bactericidal mechanisms and survive in the cytoplasm of cells.<sup>23</sup> It also has the ability to spread from cell to cell through pseudopodia formation within the infected cell, thus avoiding binding by antibodies. Resistance to infection is predominantly mediated by cellular immunity; their elimination requires T lymphocytes mediated cytotoxicity.

Controversy exists over whether SLE outbreaks may increase the risk of infection or not.<sup>18</sup> In this review we found that 11 of the 26 cases had active SLE; in 12 cases the activity was not reported and only 3 patients had inactive SLE, all were on renal replacement therapy, suggesting that the number and function of T cells are

**Table 1**  
Demographic Data of 26 Patients With SLE and CNS Infection by *Listeria monocytogenes*.

Author and reference	Case number	Year of publication	Gender	Age	Treatment	Diagnostics	Infection type
Schulze et al. <sup>20</sup>	1	1953	F	19	No steroids or immunosuppressive drugs	SLE	Meningitis Bacteremia
Rosengarten and Bourn <sup>32</sup>	2.	1959	F	48	Steroids	SLE	Meningitis Bacteremia
Harisdangkul et al. <sup>6</sup>	3.	1992	M	31	P Nitrogen Mustard	Active SLE. CRF in PD	Meningitis
Kraus et al. <sup>7</sup>	4.	1994	F	25	P (50 mg/day)	Active SLE	Meningitis
	5.	1994	F	29	P (100 mg/d)	Active SLE. Fisher-Evans syndrome	Meningitis Bacteremia
	6.	1994	F	20	No steroids or immunosuppressive drugs	Inactive SLE CRF in HD	Meningitis
	7.	1994	F	28	No steroids or immunosuppressive drugs	Inactive SLE CRF in HD	Meningitis
	8.	1994	F	60	P (7.5 mg/day)	Inactive SLE	Meningitis Bacteremia
	9.	1994	M	27	P (200 mg/day)	Active SLE	Meningitis
Soga et al. <sup>10</sup>	10	1994	F	29	NA	LESSLE	Meningitis
Mylonakis et al. <sup>30</sup>	11	1998	F	16	Steroids, azathioprine and methotrexate	SLE	Meningitis
Eckburg et al. <sup>12</sup>	12	2001	F	34	“Standard Immunosuppression”	SLE Renal Transplantation	Brain abscess Bacteremia
Lopez-Montes et al. <sup>28</sup>	13	2005	F	54	CYC (750 mg 2 doses). P (60 mg/day)	SLE	Meningo-encephalitis Bacteremia
Hung et al. <sup>15</sup>	14	2005	F	29	CYC+PL	Active SLE	Meningitis
	15	2005	F	24	PL	Active SLE	Meningitis
	16	2005	F	22	PL+HCQ	Active SLE	Meningitis Bacteremia
Hernandez-Belmonte et al. <sup>13</sup>	17	2005	M	22	PL+HCQ	Active SLE	Meningitis
	18	2008	F	60	P (30 mg/day) MMF (750 mg/day)	Active SLE (hematologic)	Meningitis, brain abscess
Cone et al. <sup>14</sup>	19	2008	F	56	P	SLE	Brain abscess Bacteremia
Baizabal et al. <sup>18</sup>	20	2009	F	38	NA	SLE	Meningitis, multiple brain abscesses
Tobon et al. <sup>11</sup>	21	2010	F	18	P+AZA	SLE	Meningitis Bacteremia
	22	2010	F	27	P+MMF	SLE. CRF in HD	Meningitis Bacteremia
	23	2010	F	18	P+MMF	LES	Meningitis Bacteremia
Lee et al. <sup>8</sup>	24	2011	F	32	HCQ+MP+MMF	Active SLE	Meningitis Bacteremia
McCaffrey et al. <sup>9</sup>	25	2012	M	57	P (20 mg/d)	LESSLE	Meningoencephalitis Bacteremia
Case report	26	2012	F	47	P+MMF	Active SLE	Meningitis Frontal brain abscess

AZA, azathioprine; CRF, chronic renal failure; CYC, cyclophosphamide; HCQ, hydroxychloroquine; HD, hemodialysis; IPD, Intermittent peritoneal dialysis; MMF, mycophenolate mofetil; NA, not available; P, prednisone; PL, prednisolone; SLE, systemic lupus erythematosus.

affected especially during acute exacerbations of the disease, and may predispose to this infection, which is consistent with previous reports that have indicated that increased activity is associated to lymphopenia and increase the risk of infection.<sup>7,17,24</sup>

The tendency to intensive immunosuppressive therapy may increase cellular immune dysfunction, with an increased risk of infection<sup>18</sup> GC were common predisposing factors in all cases (20 of 23 patients), leading to an alteration of cellular and humoral immunity. In animal models it has been shown that glucocorticoids increase susceptibility to infection with *Listeria* and cases of CNS infection with concomitant GC therapy in humans<sup>25</sup> carry a poor prognosis. 10 of 23 cases (43%) used concomitant immunosuppressive medication. The role of cytotoxic drugs as a risk factor is less clear than the use of GC. In a cohort of 174 patients, the most important risk factors were treatment with steroids and

immunosuppressants, cytopenias and renal affection.<sup>11</sup> Furthermore, the use of cytotoxic therapy was not a risk factor in other studies.<sup>6,17</sup>

Among the clinical manifestations, fever is the most common sign (90%–100%), regardless of immune status; headache is a non-specific symptom and the presence of meningeal signs is variable and appears to be related to the degree of immunosuppression.<sup>26</sup> In the series by Skoberg et al., neck stiffness was present in 26% of patients on immunosuppressive therapy, 47% of people with underlying disease without immunosuppressive therapy and in 54% of previously healthy subjects,<sup>27</sup> which shows that *Listeria* meningitis cannot be excluded on the basis of the absence of meningeal signs.<sup>26</sup> The presence of fever and headache is the rule in patients with brain abscess. Most had bacteremia, with the most common form of infection being hematogenous spread, which is rare in brain

**Table 2**  
Clinical Features in 26 Patients With CNS Infection by *Listeria monocytogenes*.

Case Number	Fever	Headache	Meningeal signs	Altered mental status	Diarrhea	Sickness	Vomiting	Focal neurological signs	Other manifestations
1	+	–	+	–	+	–	+	+	
2	+	+	+	+	+	–	+	+	Weakness, facial paralysis
3	ND	ND	ND	ND	ND	ND	ND	ND	
4	+	–	–	+	ND	ND	ND	ND	Petechiae
5	+	+	–	+	ND	ND	ND	ND	
6	–	+	+	+	ND	ND	ND	ND	
7	–	+	+	+	ND	ND	ND	ND	
8	+	+	–	+	ND	ND	ND	ND	
9	+	–	+	+	ND	ND	ND	ND	
10	+	+	+	ND	ND	ND	+	ND	
11	+	+	–	ND	ND	ND	ND	+	General discomfort for 14 days, difficulty walking, diplopia. Bilateral nystagmus. VII palsy. Weakness of the right arm. Parietal lobe brain abscess
12	+	ND	ND	ND	ND	ND	ND	+	Bradypsychia
13	+	ND	+	+	ND	ND	ND	ND	
14	ND	ND	ND	ND	ND	ND	ND	ND	
15	ND	ND	ND	ND	ND	ND	ND	ND	
16	ND	ND	ND	ND	ND	ND	ND	ND	
17	ND	ND	ND	ND	ND	ND	ND	ND	
18	+	+	–	+	–	+	+	–	Right temporal abscess
19	ND	ND	ND	ND	ND	ND	ND	ND	Frontal and occipital brain abscess
20	+	+	+	–	–	+	–	+	Dysarthria, facial palsy, hemiparesis and hyperalgesia (Millard-Gubler syndrome)
21	+	+	–	–	–	–	+	–	Malaise
22	+	+	–	–	+	+	+	–	Myalgia, seizures
23	+	+	+	+	–	+	–	–	General malaise, joint pain, abdominal pain, photophobia, phonophobia, hydrocephalus
24	+	–	–	+	+	–	–	–	General malaise, nonproductive cough Acute renal failure requiring dialysis
25	+	+	+	+	+	+	+	–	Hydrocephalus Malar erythema Hydrocephalus
26	+	+	–	–	–	+	–	–	

(+), present; (–), absent; ND, not determined.

abscesses caused by other processes that usually occur by direct extension from infected adjacent tissues. 60% was associated with meningitis and positive CSF cultures were present in 80%.

Because the clinical picture is nonspecific in patients with lupus and neurological, the study protocol should include an imaging study of the brain parenchyma and CSF study. Computed tomography (CT) and MRI add little to the diagnosis of meningitis, but they help exclude other causes of CNS. The most common feature of *Listeria meningitis* is a normal CT or hydrocephalus without focal lesions. MRI is superior to CT to demonstrate the involvement of the cerebral parenchyma.<sup>5</sup>

CSF findings in cases of meningitis are variable with a preponderance of polymorphonuclear leukocytes in almost 3/4 of the cases; the protein level is generally moderately elevated and glucose can be normal or low.<sup>23,26,28–30</sup> In this review pleocytosis was found in 12 cases where the information was available, 63% with polymorphonuclear predominance. In the presence of lymphocytosis, CSF can simulate a viral meningitis and their presence does not exclude bacterial meningitis; antibiotic therapy should be given until culture results are available. *Listeria encephalitis* can mimic the herpes simplex virus encephalitis, particularly because both are one of the few causes of encephalitis associated with erythrocytes in CSF without CNS hemorrhage or traumatic spinal tap.<sup>5</sup> In this series, 4 cases reported that erythrocytes in CSF were elevated. Gram staining shows a low diagnostic yield; no case was positive, and this was lower than what is reported in other conditions that show a 24%–50% positivity.<sup>23,31</sup> The diagnosis requires isolation of LM. Cultures have a good diagnostic yield, and in 21 of 25 patients (84%) growth in the CSF is reported and in 14 of

23 (61%) the blood culture shows development, which is similar to other conditions with a reported positivity in CSF of 80%–95% and 60%–80% in<sup>9,26</sup> blood cultures. However, early diagnosis cannot be performed due to the relatively slow growth of the microorganism, which takes approximately 3–4 days.<sup>9,32</sup> Recently, it has been reported that lactic acid levels in CSF provide a key diagnostic test for early differentiation of acute bacterial meningitis (MBA) of non-bacterial meningitis, with an inexpensive test available. MBA patients present lactic acid levels  $\geq 6$  mmol/L, whereas those with a viral or aseptic meningitis lactic acid level are  $<3$  mmol/L.<sup>33–41</sup> Another test for a rapid detection is the realization of real-time PCR-Hly, but this test is not available in clinical practice.<sup>42</sup> The diagnostic difficulty resides in the distinction between a CNS infection and exacerbations of neuropsychiatric SLE disease activity, which is a diagnostic and therapeutic challenge, since both can coexist.<sup>43</sup> McCaffrey et al. reported early diagnosis of *Listeria meningoencephalitis* in a patient with lupus by demonstrating a high level of lactic acid in CSF, days before the CSF culture and blood cultures were positive.<sup>9</sup>

Penicillin and ampicillin<sup>44</sup> constitute the initial treatment. It is considered that the antibiotic of choice in bacteremia or meningitis is ampicillin at a meningeal dose (2 g every 4 h), since it crosses the brain barrier better than penicillin. Since its bactericidal activity is slow, we recommend the coadministration with an aminoglycoside. Penicillins with gentamicin act synergistically against *Listeria* both in vitro and in vivo, and therefore it has become the standard of care. However, the advantages of combination therapy have never been shown in prospective clinical trials. In a retrospective study, combination therapy was not superior to monotherapy

**Table 3**  
Studies of Diagnosis and Treatment in 26 Patients With CNS Infection by *Listeria monocytogenes*.

	Study of cerebrospinal fluid							Others	Treatment	Outcome
	Cells	Dif	Gluc, mg/dl	Prot, mg/dl	Gram	Cul	Hem			
1	L: 1430	85% PMN	13 mg	ND	ND	+	+	Leukocyte (18 000 cel./Mm <sup>3</sup> ) with neutrophilia	Streptomycin 500 mg IM every 4 h	Died
2.	L: 548 E: 29	ND	ND	ND	-	+	+		2,000,000 U penicillin + streptomycin 2 g/day. Prednisone 7.5 mg/day Sulfadiazine Chloramphenicol	Died
3.	ND	ND	ND	ND	ND	ND	ND	Normal CT	Resistant to cephalosporins Ampicillin	Healed
4.	ND	ND	ND	ND	ND	+	-		Ampicillin + Amikacin	Died
5.	ND	ND	ND	ND	ND	+	+		Ampicillin	Healed
6.	ND	ND	ND	ND	ND	+	-		Ampicillin + Amikacin	Died
7.	ND	ND	ND	ND	ND	+	-		Ampicillin ceftriaxone + amikacin	Healed
8.	L: 534	79% PMN	ND	ND	ND	+	+		Ceftriaxone	Healed
9	ND	ND	ND	ND	ND	+	-		Ampicillin + Amikacin	Healed
10	L: 3664	ND	ND	123	ND	+	-		ND	Healed
11	L: 1000	90% PMN	<25	365	-	+	ND		Penicillin for 14 days	Survived with sequelae: diplopia, facial paresis
12	L: 30	Predominance of PMN	ND	ND	ND	-	+		Penicillin for 4 weeks	Healed. Died at 4 months of acute hepatitis
13	L: 196	95% MN	30	160	ND	+	+		Right temporal lobe encephalitis	Ampicillin 2 g every 4 h for 6 weeks + gentamicin 200 mg/day for 2 weeks
14	ND	ND	ND	ND	ND	+	-	CT hypodense lesion in the right temporal lobe	ND	Healed
15	ND	ND	ND	ND	ND	+	-		ND	Died
16	ND	ND	ND	ND	ND	+	+		ND	Died
17	ND	ND	ND	ND	ND	+	-		ND	Healed
18	L: 196 E: 125	95% MN	30	116	ND	+	+		Ampicillin 2 g every 4 h for 6 weeks + gentamicin 200 mg/day for 2 weeks	Improved without sequelae
19	ND	ND	ND	ND	ND	+	+	MR multiple abscesses	ND	Healed
20	ND	ND	ND	ND	ND	+	ND		Gentamicin for 2 weeks. TMP-SMX for 5 weeks Ampicillin for 12 weeks	Survived with sequelae: right facial hemiparesis, hypoalgesia in right hemisphere
21	ND	ND	ND	ND	ND	-	+	Elevated acute phase reactants	Ampicillin	Healed
22	ND	ND	ND	ND	ND	-	+	CSF supporting meningitis	Ampicillin	Healed
23	L: 600	ND	ND	ND	ND	-	+	Elevated ESR and CRP Hypocomplementemia	Ampicillin	Healed
24	L: 391	ND	301	552	-	+	+	Elevated CRP	Ceftriaxone initially. Cultivation (+) at day 7 change to: ampicillin 2 g every 8 h plus gentamicin 100 mg/day	Died
25	L: 3230 E: 780	93% PMN	2	399	-	+	+	Elevation ESR Lactic acid 24.7 mmol/mL	Ampicillin 2 g IV every 4 h + ceftriaxone 2 g IV every 12 h	Healed
26	L: 27 E: 45	80% MN	61	396	-	+	-		Ceftriaxone with vancomycin initially. Ampicillin 2 g IV every 4 h for 6 weeks	Improved without sequelae

with penicillin.<sup>23</sup> Combination therapy with gentamicin is recommended in the treatment of CNS *Listeria* infections, endocarditis, and infections in immunocompromised patients, such as patients with SLE.<sup>28</sup> In patients allergic to penicillin or in whom a second line treatment is recommended cotrimoxazole is an option, being bactericidal against this organism, with its 2 components having excellent CNS penetration and allowing to be administered orally in doses of 320/1600 mg every 8–12 h.<sup>4,26</sup> The isolates are generally susceptible to vancomycin in vitro and clinical success with vancomycin have been reported, including our case. However, a case of *Listeria meningitis* has been described developed during<sup>45</sup> vancomycin therapy. In general, there is insufficient information on the clinical use of vancomycin for listeriosis. In a series of patients with severe *Listeria* meningoenzephalitis, the combination of ampicillin and cotrimoxazole gave better results in terms of relapses and neurological sequelae than ampicillin with gentamicin and found no difference in mortality between patients treated with ampicillin or penicillin monotherapy and those receiving combined treatment with beta-lactam plus aminoglycoside (73% vs 70%,  $P>0.05$ ).<sup>23</sup> In cases of brain abscess, surgical intervention may not be necessary. Numerous case reports describe successful treatment with antimicrobial therapy alone.<sup>5</sup> There are no randomized trials to determine whether there is a superior treatment regimen, but clinical experience dictates that ampicillin should remain the drug of choice.<sup>46</sup> The optimal duration of treatment is unknown; with relapses reported in patients with meningitis treated for less than 2 weeks. We suggest extending treatment for meningitis in immunocompromised patients for at least 4–8 weeks, with no less than 5–6 weeks of ampicillin and gentamicin for 2–4 weeks.<sup>5,8,26</sup> Patients with brain abscess, encephalitis or rhomboenzephalitis should be treated for at least 6 weeks, followed by brain imaging studies. Mylonakis et al. recommend that the total duration of treatment should be individualized according to clinical response and clinical and radiological monitoring is essential before deciding on the end of treatment.<sup>4,30</sup>

Mortality remains high despite antibiotics and studies consistently report rates of 20%–50% among those who received therapy, especially those with underlying diseases, old age, immunosuppression associated to severe sepsis and 1.15 CNS infection.<sup>1,15,23,47,48</sup> It is considered that the incidence will increase due to the increased life expectancy of immunosuppressed patients. The prognosis apparently depends not only on listeriosis itself, but also on the type and stage of the underlying disease; there is a variation in mortality rates with different diseases, 48% in patients with cancer, 29% in patients with iatrogenic diseases and less than 20% in previously healthy patients.<sup>26,29,49</sup>

Clinical suspicion, along with early diagnosis and correct treatment in the early hours of symptoms would be measures that may prevent high mortality.<sup>15</sup> Aronin et al. reported better results in patients with early treatment.<sup>26</sup> In this series there were no relapses in patients who survived the infection and the onset of focal neurologic signs worsened the prognosis.

## Conclusions

CNS infection by *Listeria* in patients with SLE is rare and sometimes fatal; an atypical presentation may lead to a delay in diagnosis and initiation of appropriate treatment. Therefore, it is suggested that an imaging study, a blood culture and CSF examination, including lactic acid levels and cultures of bacteria, mycobacteria and fungi be undertaken. The use of GC, immunosuppressants, renal replacement therapy and the outbreak of activity are factors that predispose to the development of CNS listeriosis in patients with lupus. LM should be included in the differential diagnosis of these patients, having to consider initiating empiric treatment with

ampicillin due to the high resistance to cephalosporins, considered as the treatment of choice in patients with CNS infection.

## Ethical Responsibilities

**Protection of people and animals.** The authors declare that experiments have not been performed on humans or animals.

**Data confidentiality.** The authors state that no patient data appear in this article.

**Right to privacy and informed consent.** The authors have obtained the informed consent of patients and/or subjects referred to in the article. This document is in the possession of the corresponding author.

## Conflict of Interest

The authors declare no conflict of interest.

## References

- Calder JA. *Listeria meningitis* in adults. *Lancet*. 1997;350:307–8.
- Overturf GD. Indications for the immunological evaluation of patients with meningitis. *Clin Infect Dis*. 2003;36:189–94.
- Noriega Ricalde LM. *Listeria monocytogenes*: old bug, permanent challenge. *Rev Chilena Infectol*. 2008;25:326–7.
- Moregas M, Martínez-Yélamos S, Murillo O, Fernández-Viladrich P. Absceso cerebral del adulto por *Listeria monocytogenes*: presentación de 6 casos y revisión de la literatura médica. *Enferm Infecc Microbiol Clin*. 2010;28:87–94.
- Clauss HE, Lorber B. Central nervous system infection with *Listeria monocytogenes*. *Curr Infect Dis Rep*. 2008;10:300–6.
- Harisdangkul V, Songcharoen S, Lin AC. Listerial infections in patients with systemic lupus erythematosus. *South Med J*. 1992;85:957–60.
- Kraus A, Cabral AR, Sifuentes-Osorio J, Alarcon-Segovia D. Listeriosis in patients with connective tissue diseases. *J Rheumatol*. 1994;21:635–8.
- Lee MC, Wu YK, Chen CH, Wu TW, Lee CH. *Listeria monocytogenes* meningitis in a young woman with systemic lupus erythematosus. *Rheumatol Int*. 2011;31:555–7.
- McCaffrey LM, Petelin A, Cunha BA. Systemic lupus erythematosus (SLE) cerebritis versus *Listeria monocytogenes* meningoencephalitis in a patient with systemic lupus erythematosus on chronic corticosteroid therapy: the diagnostic importance of cerebrospinal fluid (CSF) of lactic acid levels. *Heart Lung*. 2012;41:394–7.
- Soga T, Shirai A, Igarashi T, Kato K, Ishigatsubo Y, Okubo T. A case of *Listeria meningitis* associated with systemic lupus erythematosus. *Kansenshogaku Zasshi*. 1994;68:411–5.
- Tobon GJ, Serna MJ, Canas CA. *Listeria monocytogenes* infection in patients with systemic lupus erythematosus. *Clin Rheumatol*. 2010.
- Eckburg PB, Montoya JG, Vosti KL. Brain abscess due to *Listeria monocytogenes*: five cases and a review of the literature. *Medicine (Baltimore)*. 2001;80:223–35.
- Hernández-Belmonte A, Mateos-Rodríguez F, Andrés-Mompeán E, Palomar-Pérez J. Bacteremia, absceso cerebral y meningitis por *Listeria monocytogenes*. *Enferm Infecc Microbiol Clin*. 2008;26:318–9.
- Cone LA, Somero MS, Qureshi FJ, Kerker S, Byrd RG, Hirschberg JM, et al. Unusual infections due to *Listeria monocytogenes* in the Southern California Desert. *Int J Infect Dis*. 2008;12:578–81.
- Hung JJ, Ou LS, Lee WI, Huang JL. Central nervous system infections in patients with systemic lupus erythematosus. *J Rheumatol*. 2005;32:40–3.
- Vargas PJ, King G, Navarra SV. Central nervous system infections in Filipino patients with systemic lupus erythematosus. *Int J Rheum Dis*. 2009;12:234–8.
- Yang CD, Wang XD, Ye S, Gu YY, Bao CD, Wang Y, et al. Clinical features, prognostic and risk factors of central nervous system infections in patients with systemic lupus erythematosus. *Clin Rheumatol*. 2007;26:895–901.
- Baizabal-Carvalho JF, Delgadillo-Marquez G, Estanol B, Garcia-Ramos G. Clinical characteristics and outcomes of the meningitides in systemic lupus erythematosus. *Eur Neurol*. 2009;61:143–8.
- Greenberg SB. Infections in the immunocompromised rheumatologic patient. *Crit Care Clin*. 2002;18:931–56.
- Schulze ML, Wahle Jr GH, White JB. Meningitis due to *Listeria monocytogenes* in a case of disseminated lupus erythematosus. *Am J Clin Pathol*. 1953;23:1028–30.
- Takano M, Aoki K. A case of untreated systemic lupus erythematosus presenting with listerial meningitis. *Rinsho Shinkeigaku*. 2001;41:588–91.
- Mook P, O'Brien SJ, Gillespie IA. Concurrent conditions and human listeriosis, England, 1999–2009. *Emerg Infect Dis*. 2011;17:38–43.
- Julián A, Jiménez A, De Górgolas M, Fernández R, Fernández M. Infecciones por *Listeria monocytogenes* en el adulto. Aspectos clínicos y microbiológicos de una enfermedad cambiante. *Enferm Infecc Microbiol Clin*. 2001;19:297–303.

24. Ng WL, Chu CM, Wu AK, Cheng VC, Yuen KY. Lymphopenia at presentation is associated with increased risk of infections in patients with systemic lupus erythematosus. *QJM*. 2006;99:37–47.
25. Johnson ML, Colley EW. *Listeria monocytogenes* encephalitis associated with corticosteroid therapy. *J Clin Pathol*. 1969;22:465–9.
26. Bartt R. *Listeria* and atypical presentations of *Listeria* in the central nervous system. *Semin Neurol*. 2000;20:361–73.
27. Skogberg K, Syrjänen J, Jähkölä M, Renkonen OV, Paavonen J, Ahonen J, et al. Clinical presentation and outcome of listeriosis in patients with and without immunosuppressive therapy. *Clin Infect Dis*. 1992;14:815–21.
28. López-Montes A, Mompeán E, Martínez-Villaescusa M, Hernández-Belmonte A, Mateos-Rodríguez F, Abad Ortiz L, et al. Meningoencefalitis por *Listeria* en el lupus. *An Med Interna (Madrid)*. 2005;22:379–82.
29. McLauchlin J. Human listeriosis in Britain, 1967–85, a summary of 722 cases. 2. Listeriosis in non-pregnant individuals, a changing pattern of infection and seasonal incidence. *Epidemiol Infect*. 1990;104:191–201.
30. Mylonakis E, Hohmann EL, Calderwood SB. Central nervous system infection with *Listeria monocytogenes*. 33 years' experience at a general hospital and review of 776 episodes from the literature. *Medicine (Baltimore)*. 1998;77:313–36.
31. Brouwer MC, van de Beek D, Heckenberg SG, Spanjaard L, de Gans J. Community-acquired *Listeria monocytogenes* meningitis in adults. *Clin Infect Dis*. 2006;43:1233–8.
32. Rosengarten R, Bourn JM. *Listeria* septicemia and meningitis in a case of lupus erythematosus. *Neurology*. 1959;9:704–6.
33. Cunha BA. Cerebrospinal fluid (CSF) lactic acid levels: a rapid and reliable way to differentiate viral from bacterial meningitis or concurrent viral/bacterial meningitis. *J Clin Microbiol*. 2012;50:211.
34. Cunha BA. Distinguishing bacterial from viral meningitis: the critical importance of the CSF lactic acid levels. *Intensive Care Med*. 2006;32:1272–3 [author reply 4].
35. Cunha BA. The diagnostic usefulness of cerebrospinal fluid lactic acid levels in central nervous system infections. *Clin Infect Dis*. 2004;39:1260–1.
36. Bailey EM, Domenico P, Cunha BA. Bacterial or viral meningitis? Measuring lactate in CSF can help you know quickly. *Postgrad Med*. 1990;88:217–9.
37. Cunha BA, Fatehpuria R, Eisenstein LE. *Listeria monocytogenes* encephalitis mimicking Herpes Simplex virus encephalitis: the differential diagnostic importance of cerebrospinal fluid lactic acid levels. *Heart Lung*. 2007;36:226–31.
38. Sakushima K, Hayashino Y, Kawaguchi T, Jackson JL, Fukuhara S. Diagnostic accuracy of cerebrospinal fluid lactate for differentiating bacterial meningitis from aseptic meningitis: a meta-analysis. *J Infect*. 2011;62:255–62.
39. De Almeida SM, Boritza K, Cogo LL, Pessa L, Franca J, Rota I, et al. Quantification of cerebrospinal fluid lactic acid in the differential diagnosis between HIV chronic meningitis and opportunistic meningitis. *Clin Chem Lab Med*. 2011;49:891–6.
40. Abro AH, Abdou AS, Ustadi AM, Saleh AA, Younis NJ, Doleh WF. CSF lactate level: a useful diagnostic tool to differentiate acute bacterial and viral meningitis. *J Pak Med Assoc*. 2009;59:508–11.
41. Huy NT, Thao NT, Diep DT, Kikuchi M, Zamora J, Hirayama K. Cerebrospinal fluid lactate concentration to distinguish bacterial from aseptic meningitis: a systemic review and meta-analysis. *Crit Care*. 2010;14:R240.
42. Le Monnier A, Abachin E, Beretti JL, Berche P, Kayal S. Diagnosis of *Listeria monocytogenes* meningoencephalitis by real-time PCR for the hly gene. *J Clin Microbiol*. 2011;49:3917–23.
43. Enberg GM, Kahn ChM, Goity FC, Villalon SM, Zamorano RJ, Figueroa EF. Infections in patients with systemic lupus erythematosus. *Rev Med Chil*. 2009;137:1367–74.
44. Huang SL, Chou YT, Hsieh YC, Huang YC, Lin TY, Chiu CH. Epidemiology and clinical characteristics of *Listeria monocytogenes* bacteremia in a Taiwanese medical center. *J Microbiol Immunol Infect*. 2010;43:485–90.
45. Baldassarre JS, Ingerman MJ, Nansteel J, Santoro J. Development of *Listeria* meningitis during vancomycin therapy: a case report. *J Infect Dis*. 1991;164:221–2.
46. Tuazon CU, Shamsuddin D, Miller H. Antibiotic susceptibility and synergy of clinical isolates of *Listeria monocytogenes*. *Antimicrob Agents Chemother*. 1982;21:525–7.
47. Barriga-Angulo G, Arumir-Escorza C, Mercado-González N, Ramírez-Ortíz R, López-Orduña E. Características clínicas y epidemiológicas de 3.183 casos de meningitis confirmados bacteriológicamente (1980/2007). *Enf Inf Microbiol*. 2009;29:99–106.
48. Arias-Miranda I, Nuño-Mateo F, Noval-Menendez J, Fonseca-Aizpuru E, Menéndez-Calderón M. Listeriosis en el adulto. Revisión de 10 casos. *An Med Interna (Madrid)*. 2004;21:75–8.
49. Samra Y, Hertz M, Altmann G. Adult listeriosis—a review of 18 cases. *Postgrad Med J*. 1984;60:267–9.