

Images in Clinical Rheumatology

Madelung's Deformity[☆]

Deformidad de Madelung

Domingo Ly-Pen,^a José Luis Andreu^{b,*}

^a Servicio de Urgencias, Hospital Universitario Ramón y Cajal, Madrid, Spain

^b Servicio de Reumatología, Hospital Universitario Puerta de Hierro, Majadahonda, Madrid, Spain

ARTICLE INFO

Article history:

Received 2 February 2013

Accepted 15 May 2013

Clinical Case

The patient is a 39-year-old woman who presented nocturnal paresthesia lasting for 6 months on both hands, but predominantly right (dominant hand). She presented mechanical pain of both wrists, with a visual analog score (VAS) of 90/100. Upon examination, there was a solid tumor on the posterior side of both wrists (Fig. 1), painful limitation of extension of the wrist and supination, mainly on the left side. The hemogram and blood chemistry were normal, as well as the neurophysiological study of the median and ulnar nerves. A karyotype demonstrated mosaicism (86% XX, 5% XXX, 9% X).

The posteroanterior wrist X-rays (Fig. 2) showed typical Madelung deformity changes on the right wrist¹: shortening of the radius compared to the ulna, dorsally and radially curved radius, dorsal and radial convexity, an angle similar to the distal radial joint surface, a mismatch of the distal radioulnar joint and carpal dislocation. The lateral projection (Fig. 3) demonstrated anterior arching of the radius and dorsal dislocation on the ulnar head; the carpus was also dislocated on the ulnar side and anteriorly in the distal radioulnar joint, in a way that made the wrist bones appear to follow the arch of the radius.² The patient was diagnosed with a carpal tunnel syndrome due to Madelung's deformity and was programmed for an evaluation by the orthopedics department but, due to a delay, medical treatment with local steroid infiltrations was carried out. 1 ml of triamcinolone was injected into the right wrist using a standard technique.³ The pain improved in the next 2 days (VAS: 50/100), disappearing completely after one week (VAS: 0/100).

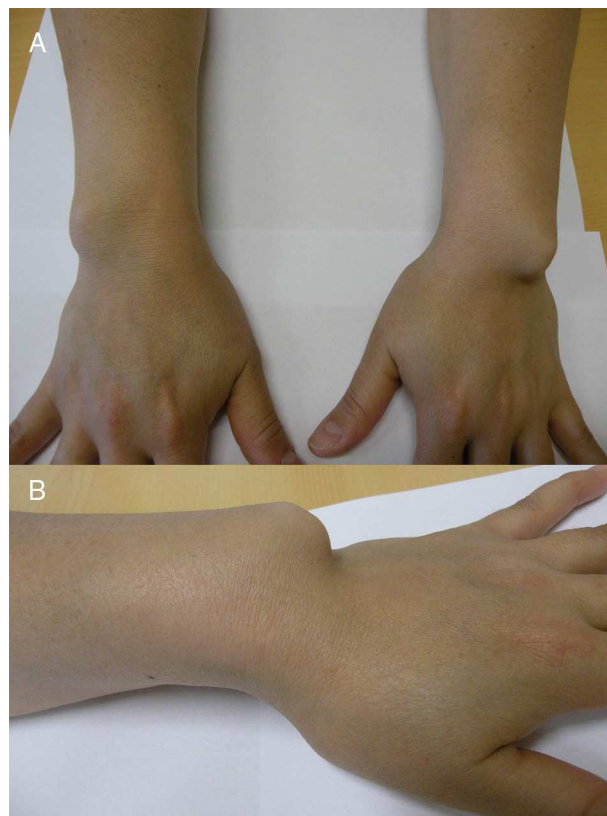


Fig. 1. Panel A shows the ulnar aspect of both wrists, with a prominence that corresponds to the ulnar head, better seen on the left wrist. Panel B shows a lateral view of the left wrist.

[☆] Please cite this article as: Ly-Pen, D, Andreu JL. Deformidad de Madelung. Reumatol Clin. 2014;10:125–126.

* Corresponding author.

E-mail addresses: jlandreu@arrakis.es, jlandreu@gmail.com (J.L. Andreu).

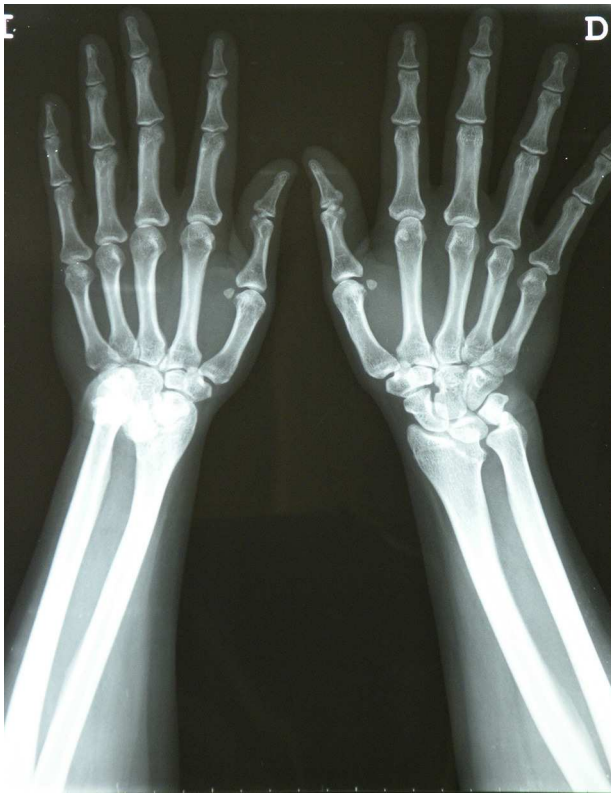

Fig. 2. Posteroanterior X-ray of both wrists.

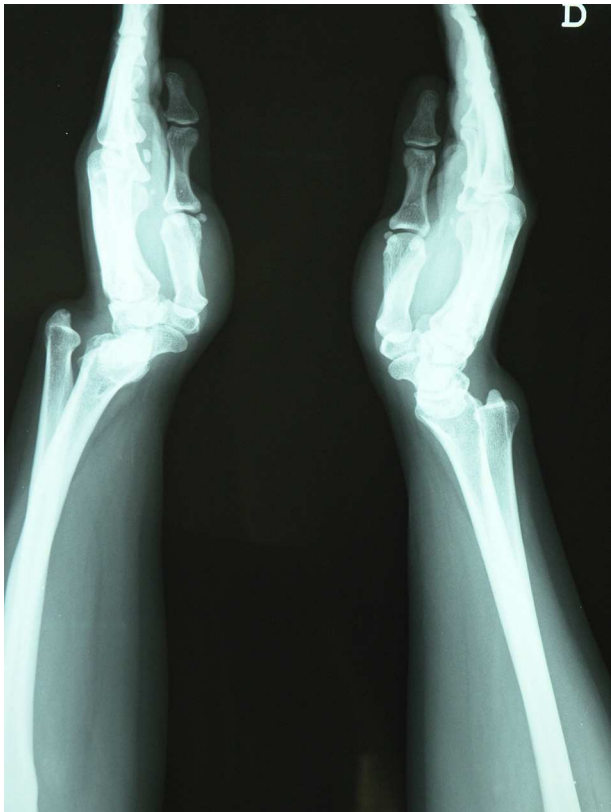

Fig. 3. Lateral X-ray of both wrists.

Comments

Otto Wilhelm Madelung described the deformity carrying his name for the first time in 1878.¹ Madelung's deformity is much more common in adolescent women, with the appearance of a slow growing tumor on the dorsal ulnar side of the wrists, local pain and a reduction in motility. Our patient presented slowly increasing pain, becoming intense at 6 months. In fact, the main symptoms were nocturnal paresthesia, motivated by an entrapment of the median nerve in the carpal tunnel. These symptoms, associated to Madelung's deformity, have been previously described by other authors.^{2,4}

Madelung deformity is the consequence of the disorganized growth of the radial epiphysis, leading to arching of the radius, a premature fusion of the epiphysis and a delay in the development of the ulnar part and the anterior part of the distal radial epiphysis. These alterations cause an inclined radial distal joint surface to the anterior and ulnar area, which leads to an anterior translation of the hand and the wrist, and a dorsal dislocation of the ulna in its distal posterior part.¹

Initial medical treatment consists normally of analgesics, non-steroidal anti-inflammatory drugs and muscle relaxants, which are not very effective. Splints may be employed to avoid excessive joint mobilization.¹

In cases such as ours, in which the most bothersome symptoms are derived from a median nerve compression in the carpal tunnel, a local infiltration of steroid may significantly alleviate nocturnal paresthesia in a few days.³

Surgical treatment must be considered based on 4 factors¹: (a) patient age and the possibility of distal ulnar growth; (b) severity of deformity; (c) severity of symptoms, and (d) clinical and radiographic findings. The objectives of surgical treatment are: alleviation of pain, esthetic correction of the deformity and improvement of joint motion, the latter being the most difficult to attain.

Ethical Responsibilities

Protection of people and animals. The authors state that no experiments were performed on persons or animals for this study.

Data confidentiality. The authors state that they have followed their workplace protocols regarding the publication of patient data and all patients included in the study have received enough information and have given their written informed consent to participate in the study.

Right to privacy and informed consent. The authors state that they have obtained informed consent from patients and/or subjects referred to in this article. This document is in the possession of the corresponding author.

Conflict of Interest

The authors have no conflicts of interest.

References

1. Lamberti PM. Madelung deformity. Medscape Reference [updated 12.07.12; accessed 3 ago 2012]. Available in: <http://emedicine.medscape.com/article/1260002-overview#a0102>
2. Sekiya JK, Jebson PJ, Louis DS. Hereditary disorders with maladies of the wrist and elbow. *Iowa Orthop J.* 1997;17:147–50.
3. Ly-Pen D, Andreu JL. Tratamiento del síndrome del túnel carpiano. *Med Clin (Barc).* 2005;125:585–9.
4. Luchetti R, Mingione A, Monteleone M, Cristiani G. Carpal tunnel syndrome in Madelung's deformity. *J Hand Surg Br.* 1988;13:19–22.