

complete PSS by positive lower lip biopsy that had MSG focus score >1, using the American-European criteria 2002<sup>5</sup>). 110/160 patients (68.75%) were mainly due to xerogenic medications. Severe obstructive sleep apnea syndrome (OSAS) was diagnosed in 6/160 patients (3.75%) (according to the American Academy of Sleep Medicine, Chicago Criteria 1999) by polysomnographic analysis. Thirty-eight (23.75%) patients were sero-positive for thyroperoxidase antibody (TPO-Ab) and/or thyroglobulin antibody (Tg-Ab) (of these patients 33/160 (20.6%) were diagnosed as having AIHT), 15 (10.2%) had a positive antinuclear antibody (ANA) assay (titer count >1:160), and 5 (3.5%) had a positive parietal cell antibody (titer count >1:160). All were sero-negative for anti-Ro/SS-A and anti-La/SS-B. In previous studies mucosal sicca symptoms were described as one of the common clinical manifestations of CFS<sup>6,7</sup> as seen in our serie. Nishikai et al. and Sirois et al. had found sicca symptoms in 73% and 52% of their series respectively.<sup>6,7</sup> As possible causes in our study, we determined that the prevalence of sicca symptoms (especially xerostomia) induced by psychotropic medications with anticholinergic side effects (amitriptyline, clonazepam, etc.) was high as described in several studies. Drugs with anticholinergic actions decrease salivary gland secretion by neurochemical blockade. It is usually dose related and reversible when medication is discontinued.<sup>7</sup> We also found a group of CFS patients with sicca symptoms that may be attributed to AIHT and OSAS. This suggests that these two disorders share common pathophysiological features with CFS. Interestingly, in patients with OSAS, CFS symptoms were improved by using continuous nasal positive airway pressure (CPAP). Any potential relationship between CFS and PSS is complicated by the lack of a sensitive test or agreement regarding the diagnostic criteria for PSS. Nishikai et al. examined a group of 75 seronegative patients diagnosed with CFS and found that 22 (29%) met the European criteria 1993 for PSS.<sup>6</sup> Sirois et al. also examined 25 patients diagnosed with CFS and found that 32% met diagnostic criteria for PSS according to the European criteria 1993.<sup>7</sup> These results were not similar to ours in the study we present (11 patients if we included patients with incomplete PSS) as we described previously (Table 1). In searching of causes of this poor association, several considerations have to be taken into account in our study. 1st, in our study we used the 2002 criteria that require mandatory: (1) a positive salivary gland biopsy (only done in 5 patients), or (2) the presence of antibodies to SSA/Ro and/or to SS-B/La (negative in all patients). The serological item was also met in the 1993 criteria (used by Nishikai et al. and Sirois et al.,<sup>6,7</sup>) but only if a test for rheumatoid factor or ANA was positive. This condition has probably increased the prevalence of PSS in their studies. 2nd, symptoms or signs of PSS do not always begin at the same time and that patients with incomplete SS may be will met the diagnostic criteria 2002 at some point in the future. In summary, in our study about 70% of CFS patients with sicca syndrome

**Table 1**

Causes of sicca symptoms in chronic fatigue syndrome' patients.

Causes of sicca symptoms in chronic fatigue syndrome' patients	N°. patients (%): 160 (80.4)
Xerogenic medications	110 (68.75)
Autoimmune hypothyroidism	33 (20.6)
Primary Sjögren syndrome (incomplete/complete)	11 (6.8) (9/2 patients)
Obstructive sleep apnea syndrome	6 (3.75)

are related to be drug-induced. Therefore, xerogenic medications, as possible cause, must be excluded. However, we recommend that patients who have been diagnosed with CFS and manifest mucosal sicca symptoms should be also screened for SS, AIHT and/or OSAS; and should be regarded as a comorbidity of CFS, not a diagnostic exclusion criterion.

### Conflict of interest

The authors declare no conflict of interest.

### References

- Carruthers BM, Van de Sande MI, De Meirleir KL, Klimas NG, Broderick G, Mitchell T, et al. Myalgic encephalomyelitis: International Consensus Criteria. *J Intern Med.* 2011;270:327–38.
- Ruiz E, Alegre J, Garcia Quintana AM, Aliste L, blazquez A, Fernandez de Sevilla T. Chronic fatigue syndrome: study of a consecutive series of 824 cases assessed in two specialized units. *Rev Clin Esp.* 2011;211:385–90.
- Steinberg P, Pheley A, Peterson PK. Influence of immediate hypersensitivity skin reactions on delayed reactions in patients with chronic fatigue syndrome. *J Allergy Clin Immunol.* 1996;98:1126–8.
- Barendregt PJ, Visser MRM, Smets EMA, Tulen JHM, Van den Meiracker AH, Boomsma F, et al. Fatigue in primary Sjögren's syndrome. *Ann Rheum Dis.* 1998;57:291–5.
- Vitali C, Bombardieri S, Jonsson R, Moutsopoulos HM, Alexander EL, Carsons SE, et al. Classification criteria for Sjögren's syndrome: a revised version of the European criteria proposed by the American-European Consensus Group. *Ann Rheum Dis.* 2002;61:554–8.
- Nishikai M, Akiya K, Tojo T, Onoda N, Tani M, Shimizu K. Seronegative Sjögren's syndrome manifested as a subset of chronic fatigue syndrome. *Br J Rheumatol.* 1996;35:471–4.
- Sirois DA, Natelson B. Clinicopathological findings consistent with primary Sjögren' syndrome in a subset of patients diagnosed with chronic fatigue syndrome: preliminary observations. *J Rheumatol.* 2001;28:126–31.

Rami Qanneta<sup>a,\*</sup> Ramon Fontova<sup>b</sup> Anna Pàmies<sup>b</sup>

<sup>a</sup> *Chronic Fatigue Unit, Department of Rheumatology, Hospital Universitari Joan XXIII, Tarragona, Spain*

<sup>b</sup> *Department of Rheumatology, Hospital Universitari Joan XXIII, Tarragona, Spain*

Corresponding author.

E-mail address: [rami.kanita229@hotmail.com](mailto:rami.kanita229@hotmail.com) (R. Qanneta).

### Pigmented villonodular synovitis diagnostic delay due to coexistence with ankylosing spondylitis

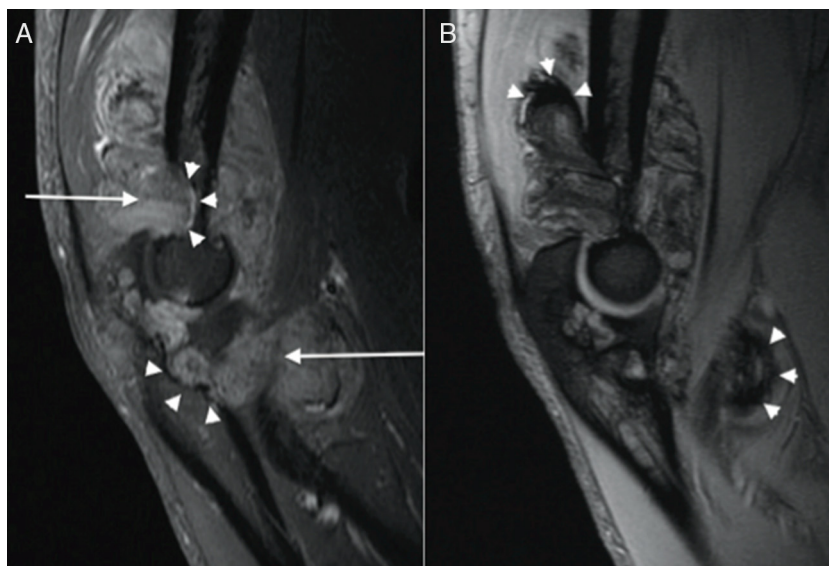


### Retraso en el diagnóstico de sinovitis villonodular pigmentada por coexistencia con espondilitis anquilosante

Dear Editor,

A 57-year-old man with longstanding ankylosing spondylitis (AS) was treated successfully with etanercept since January 2006,

except for persistent left elbow swelling. Three local corticosteroid injections and radiosynovectomy with 3 mCi 186-Rhenium proved to be useless. Elbow involvement is sporadically seen in AS,<sup>1</sup> and the persistence despite the intra-articular treatment made us consider the possibility of a coexistent arthropathy, such as an opportunistic infections (mycobacteria, fungi), synovial sarcoma, joint metastasis or lipoma arborescens. A first magnetic resonance imaging (MRI) was ordered, showing an unspecific synovial hypertrophy. Joint aspiration revealed an inflammatory non-hemorrhagic fluid with repeatedly negative cultures, and an open biopsy resulted in non-specific synovitis, ruling out infections and malignancies.



**Fig. 1.** (A) Sagittal T1 Fat-saturated image of the left elbow after intravenous gadolinium administration, showing an enhancing soft-tissue mass (arrows) associated to bone erosions (arrowheads). (B) Sagittal T2\* weighted image, showing areas of marked low signal intensity (arrowheads) suggestive of hemosiderin deposits.

In June 2010, an X-ray highlighted the development of bone erosions. A new MRI (Fig. 1) demonstrated at this time an enhancing soft-tissue mass with magnetic susceptibility effect of hemosiderin on T2\*-weighted imaging, associated with subchondral bone cysts and extrinsic erosions. Surgical synovectomy was requested, and histopathologic examination noted villonodular hyperplasia and multiple multinucleated macrophages laden with hemosiderin, characteristic features of pigmented villonodular synovitis (PVNS).

PVNS is a rare neoplastic-like pathological entity of unknown etiology affecting the synovium of the joint, tendon or bursa.<sup>2</sup> It is usually a monoarticular process carrying with pain, swelling – often mild and intermittent – and progressive decreased range of motion. It affects in decreasing order of frequency the knee, hip, ankle, and shoulder, while elbows are rarely involved.<sup>3</sup> MRI findings are highly suggestive of the diagnosis, as the characteristic low signal intensity on T2\*-weighted sequences relates to the hemosiderin-laden macrophagic infiltrate seen on histological specimens,<sup>4</sup> which is an important aid to the clinician to make differential diagnosis with other entities showing identical clinical picture, such as synovial or fibrous tumors, amyloid deposits and proliferative processes. Nonetheless, similar MRI features could be found in other hemorrhagic and chronic hyperplastic synovial disorders (as in rheumatoid arthritis, arthropathy secondary to hemorrhagic diathesis, chronic articular traumatism, haemangioma, synovial sarcoma), making the histological confirmation unavoidable.<sup>5</sup>

In our case, the coexistence with a known cause of inflammatory arthritis, as well as the negative results of the previous techniques, delayed the final diagnosis. Although it has been published improvement of PVNS with TNF $\alpha$  blockade,<sup>6</sup> our patient did not experience any benefit during etanercept treatment prescribed for his ankylosing spondylitis.

For the realization of this work has not received any funding.

#### References

- Gladman DD. Clinical aspects of the spondyloarthropathies. *Am J Med Sci.* 1998;316:234–8.
- Ottaviani S, Ayrál X, Dougados M, Gossec L. Pigmented villonodular synovitis: a retrospective single-center study of 122 cases and review of the literature. *Semin Arthritis Rheum.* 2011;40:539–46.
- DiCaprio MR, Damron TA, Stadnick M, Fuller C. Pigmented villonodular synovitis of the elbow: a case report and literature review. *J Hand Surg [Am].* 1999;24:386–91.
- Hughes TH, Sartoris DJ, Schweitzer ME, Resnick DL. Pigmented villonodular synovitis: MRI characteristics. *Skeletal Radiol.* 1995;24:7–12.
- Barile A, Sabatini M, Iannesi F, Di Cesare E, Splendiani A, Calvisi V, et al. Pigmented villonodular synovitis (PVNS) of the knee joint: magnetic resonance imaging (MRI) using standard and dynamic paramagnetic contrast media. Report of 52 cases surgically and histologically controlled. *Radiol Med.* 2004;107:356–66.
- Kroot EJA, Kraan MC, Smeets TJM, Maas M, Tak PP, Wouters JM. Tumour necrosis factor a blockade in treatment resistant pigmented villonodular synovitis. *Ann Rheum Dis.* 2005;64:497–9.

Paloma Vela<sup>a,\*</sup> Mariano Andrés<sup>b</sup> Eloisa Feliu<sup>c</sup> Vega Jovani<sup>d</sup>

<sup>a</sup> Sección de Reumatología, Hospital General Universitario de Alicante, Alicante, Spain

<sup>b</sup> Reumatólogo, Hospital General Universitario de Elda, Alicante, Spain

<sup>c</sup> Unidad de Resonancia Magnética, Erescanner Salud UTE, Alicante, Spain

<sup>d</sup> Sección de Reumatología, Hospital General Universitario de Alicante, Alicante 03010, Spain

Corresponding author.

E-mail address: palomavela62@gmail.com (P. Vela).