

Images in Clinical Rheumatology

Polyostotic fibrous displasia: A case report[☆]



Displasia fibrosa poliostótica: presentación de un caso

Carlos Francisco Meneses,* Antonio Egües, Miren Uriarte, Joaquín Belzunegui

Sección de Reumatología, Hospital Universitario Donostia, San Sebastián, Guipúzcoa, Spain

ARTICLE INFO

Article history:

Available online 23 September 2014

A 37-year-old woman with a fibrous polyostotic dysplasia (FPD) of the left femur, tibia and foot was diagnosed at 11 years of age. At the onset she presented mechanical pain of the left hip and later a stress fracture of the femur for which she was treated with surgery, pamidronate and zoledronate. Pathology confirmed the diagnosis. Phosphocalcic metabolism was normal.

X-rays (Fig. 1) showed a left femur with a «shepherd's staff» deformity, a thin bone cortex and expansive radiolucent lesions. The left tibia (Fig. 2) was curved and had a thin cortex. Feet (Fig. 3) were thickened at the first right metatarsal and phalange with radiolucent and sclerotic areas. A computed tomography of the tibia (Fig. 4) observed a ground glass matrix, with heterogeneous intramarrow images.

FPD is a rare anomaly of skeletal development. A mutation in the *GNAS1* gene has been detected,¹ producing alterations in osteoplastic maturation and abnormal fibrous tissue deposit.² There are two variants: monostotic and polyostotic.³ Lesions are localized on the epiphysis, metaphysis or diaphysis.

The monostotic variant is more prevalent, diagnosed during the patient's youth and less symptomatic. It affects the ribs, femur, tibia, jawbone and humerus.⁴

The polyostotic form is observed in 30% of cases. It is usually diagnosed during the patients' infancy. It affects the cranium, face, pelvis, spine and shoulder. It is associated to the McCune-Albright syndrome in 2% of cases (FPD, skin pigmentation and early puberty).² It leads to dysmetria, gait abnormalities, mechanical pain and stress fractures.⁵ FPD diagnosis is radiological, rarely requiring a bone biopsy. The prognosis depends on the extension and degree of bone affection, age at

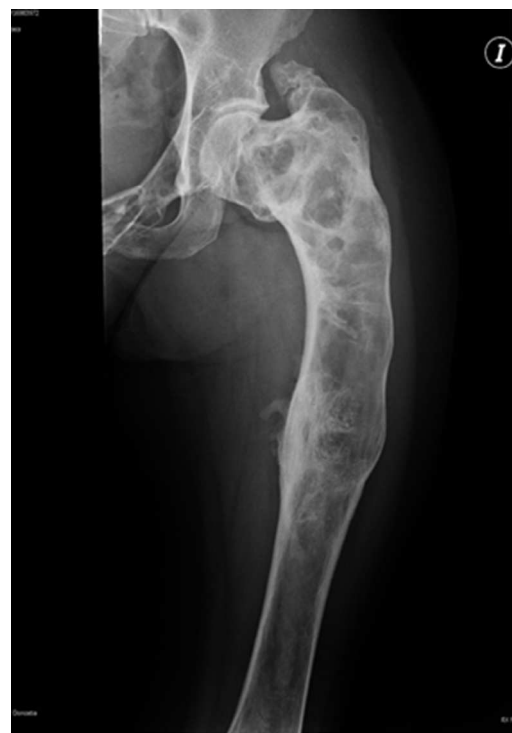

Fig. 1. Anteroposterior X-ray of the left femur with a «shepherd's staff» deformity, a thin cortex and expansive radiolucent images.

[☆] Please cite this article as: Meneses CF, Egües A, Uriarte M, Belzunegui J. Displasia fibrosa poliostótica: presentación de un caso. Reumatol Clin. 2014;10: 413–415.

* Corresponding author.

E-mail address: carlosfrancisco.menesesvillalba@osakidetza.net (C.F. Meneses).

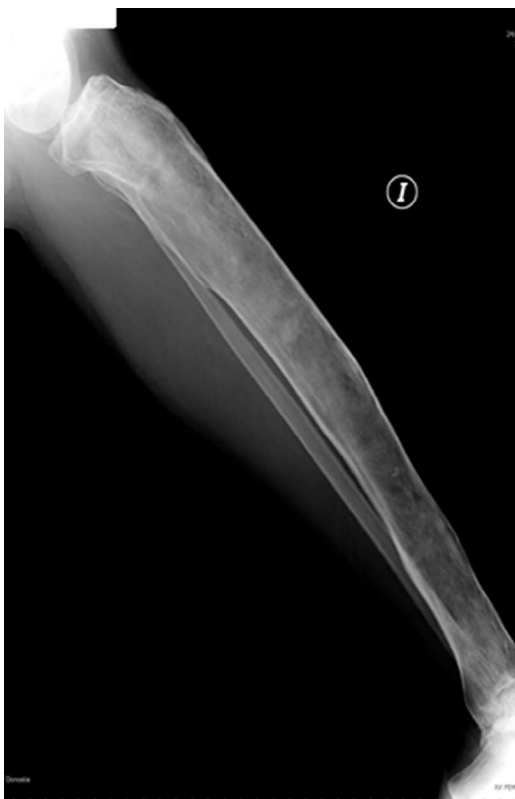

Fig. 2. Lateral X-ray of the left tibia, which is curved and has a thin cortex.

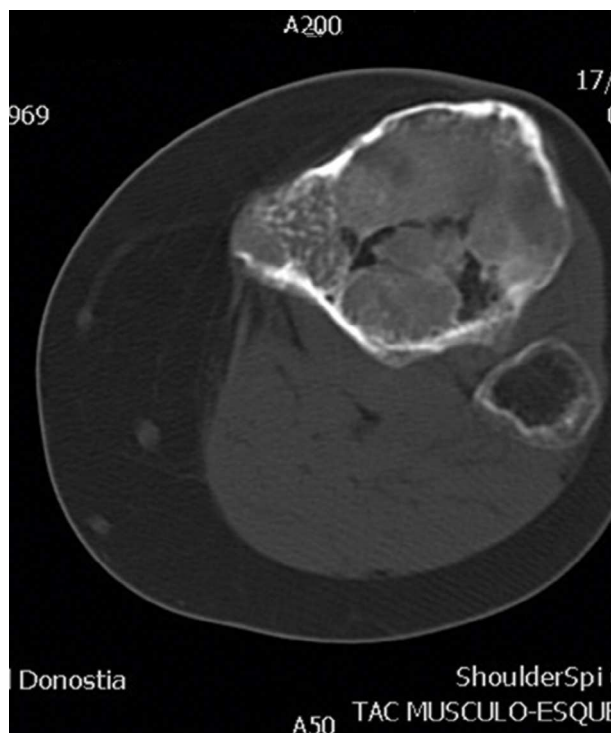


Fig. 4. Computerized tomography of the tibia with axial images of the proximal end.

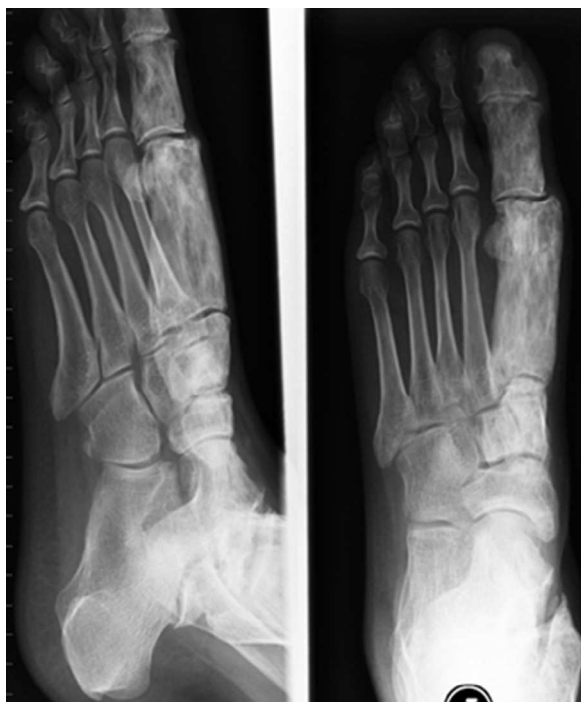

Fig. 3. Lateral and anteroposterior X-ray of the left foot with thickening of the metatarsal and phalange of the first right toe.

onset and extraskeletal manifestations.² The malignancy rate is rare.⁶

In case of pain, deformity or fracture, treatment with bisphosphonate is recommended.⁷ Curettage or bone implants might be necessary.

Didactic Message

In young patients with bone deformity, PFD must be considered as a diagnosis. Simple X-rays might be enough for diagnosis.

Ethical Responsibilities

Protection of People and Animals. The authors state that no experiments were performed on people or animals for this study.

Confidentiality of Data. The authors state that the protocols of their center regarding the publication of patient data have been followed.

Right to Privacy and Informed Consent. The authors have obtained informed consent from the patients and/or subjects referred to in the article. This document is in the possession of the corresponding author.

References

1. Tis J. Overview of benign bone tumors in children and adolescents. UpToDate. 2013. Available from: http://www.uptodate.com/contents/benign-bone-tumors-in-children-and-adolescents-an-overview?source=search_result&search=Overview+of+benign+bone+tumors+in+children+and+adolescents.&selectedTitle=1~150 (accessed 03.03.13).
2. Resnick D. Diagnosis of bone and joint disorders, 5 Volume Set, 4th ed. Philadelphia, PA: WB Saunders Co., Ltd.; 2002.
3. Siegal GP, Bianco P, Dal Cin P. Fibrous dysplasia. In: Fletcher CDM, Bridge JA, Hogendoorn PCW, Mertens F, editors. WHO classification of tumours of soft tissue and bone. 4th ed. Lyons: International Agency for Research on Cancer; 2013. p. 352.

4. Biermann JS. Common benign lesions of bone in children and adolescents. *J Pediatr Orthop.* 2002;**22**:268–73.
5. Copley L, Dormans JP. Benign pediatric bone tumors. Evaluation and treatment. *Pediatr Clin North Am.* 1996;**43**:949–66.
6. Riddell DM. Malignant change in fibrous dysplasia. *J Bone Joint Surg Br.* 1964;**46**:251–5.
7. Lane JM, Khan SN, O'Connor WJ, Nydick M, Hommen JP, Schneider R, et al. Bisphosphonate therapy in fibrous dysplasia. *Clin Orthop Relat Res.* 2001:6–12.