



Brief Report

Pseudotumoral Behçet's Disease[☆]



Sara Alonso,^a Anne Riveros-Frutos,^{b,*} Melania Martínez-Morillo,^b Laia Grau-Ferrer,^c Cristina Carrato,^d Alejandro Olivé^b

^a Sección de Reumatología, Hospital Universitario Central de Asturias, Oviedo, Spain

^b Servicio de Reumatología, Hospital Universitario Germans Trias i Pujol, Badalona, Spain

^c Servicio de Neurología, Hospital Universitario Germans Trias i Pujol, Badalona, Spain

^d Servicio de Anatomía patológica, Hospital Universitario Germans Trias i Pujol, Badalona, Spain

ARTICLE INFO

Article history:

Received 7 January 2015

Accepted 13 March 2015

Available online 15 February 2016

Keywords:

Behçets disease

Neuro-Behçets disease

Pseudotumoral brain lesions

Palabras clave:

Enfermedad de Behçet

Neuro-Behçet

Lesiones cerebrales pseudotumorales

ABSTRACT

Behçet's disease is a systemic vasculitis characterized by the presence of oral and genital ulcers. Neurological involvement or neuro-Behçet is an uncommon manifestation. Its manifestation has predominance in the male gender appearing 2–4 years after the first clinical manifestation.

However, neuro-Behçet disease sometimes occurs with pseudotumoral brain lesions. Herein, we present the cases of two patients diagnosed with neuro-Behçet after detection of pseudotumoral brain lesions. A review of the literature is performed.

© 2015 Elsevier España, S.L.U. and Sociedad Española de Reumatología y Colegio Mexicano de Reumatología. All rights reserved.

Enfermedad de Behçet pseudotumoral

R E S U M E N

La enfermedad de Behçet es una vasculitis caracterizada por úlceras bucales y genitales. La afectación neurológica o neuro-Behçet es una manifestación infrecuente, de predominio en el género masculino y que aparece de 2 a 4 años después de la primera manifestación clínica.

El neuro-Behçet cursa ocasionalmente lesiones cerebrales pseudotumorales. Presentamos 2 casos de pacientes diagnosticados de neuro-Behçet tras la detección de lesiones cerebrales pseudotumorales y se realiza una revisión de la literatura.

© 2015 Elsevier España, S.L.U. and Sociedad Española de Reumatología y Colegio Mexicano de Reumatología. Todos los derechos reservados.

Introduction

Behçet's disease (BD) is a recurrent systemic vasculitis that is diagnosed on the basis of clinical criteria.¹ Neurological involvement, although uncommon, is among the causes of higher morbidity and mortality rates, and is included in the differential diagnosis of inflammatory and demyelinating diseases of the central nervous system.² The prevalence of neuro-BD (NBD) ranges between 1% and 59%, according to different series,^{1–5} and it is more

common among men. Neurological involvement frequently develops 5 years after the diagnosis of BD,² but may be a form of onset, which masks the diagnosis because of its atypical presentation.^{1,3} Parenchymal or extraparenchymal involvement can be observed and, in rare cases, it has been reported to present in the form of a pseudotumor.^{2,4,6–14}

We present the cases of 2 patients who were diagnosed with NBD when pseudotumors of the brain were detected.

Case reports

Case no. 1

The patient was a 63-year-old man who presented with a 1-month history of behavioral changes in the form of irritability, aggressiveness and emotional lability, as well as difficulty in

[☆] Please cite this article as: Alonso S, Riveros-Frutos A, Martínez-Morillo M, Grau-Ferrer L, Carrato C, Olivé A. Enfermedad de Behçet pseudotumoral. Reumatol Clin. 2016;12:85–90.

* Corresponding author.

E-mail address: anne.riveros@gmail.com (A. Riveros-Frutos).

Table 1
Clinical Characteristics of the Cases Reported in the Literature.

Author	Age (years) Sex	History of Behçet's disease (years)	Lesion site	Lumbar puncture	Pathological findings	Outcome	Treatment
Litvan ¹⁴ 1987	51 M	30	Left parieto-occipital region	Increased proteins in cerebrospinal fluid with negative cultures	–	Partial improvement	Glucocorticoids
Neudorfer ¹⁴ 1993	27 M	No history prior to diagnosis	Right lentiform nucleus	–	–	Improvement	Glucocorticoids
Geny ²⁶ 1993	–	–	Thalamocapsular region	–	Nonspecific. No evidence of tumor.	Improvement	Glucocorticoids
Dupin ¹⁴ 1996	20 M	No history prior to diagnosis	Cerebellum	–	–	Improvement	Glucocorticoids, colchicine, azathioprine
Visaga ²⁷ 1996	16 F	2	From bulbomedullary junction to cerebral peduncle	No	No	Improvement	Glucocorticoids, chlorambucil
Yoshimura ²⁸ 2001	41 F	Several	Left thalamolenticular region	Pleocytosis	Nonspecific. No evidence of tumor.	Improvement	Glucocorticoids
Ben Taarit ³¹ 2002	26 F	–	Protuberance and right cerebral peduncle	–	No	Improvement	Glucocorticoids
Imoto ⁸ 2002	50 M	No history prior to diagnosis	Basal ganglia, brainstem and white matter	No	Inflammatory cells and perivascular infiltrate	Reduced size	3 glucocorticoid boluses
Park ¹¹ 2002	52 F	No history prior to diagnosis	Right cerebellar hemisphere extending to 3rd ventricle	Lymphocytes 25/ μ L, proteins 300 mg/dL, glucose normal. No oligoclonal bands. Anti-CMV and herpes simplex negative	Lymphocytic vasculitis	Initial disappearance. Three episodes of recurrence. Death	Glucocorticoids, azathioprine
Tuzgen ⁶ 2003	59 F	No history prior to diagnosis	Right frontotemporal region	No	Gliosis, panvasculitis, thrombosis, extensive infarction and vascular proliferation	Radiological improvement. Persistent left hemiparesis	Surgical excision
	45 F	3 months	Left diencephalic-mesencephalic junction	No	No	Improvement	Glucocorticoids
Bennett ⁷ 2004	23 M	–	Left temporal lobe, invading peduncle, thalamus, internal capsule, basal ganglia and posterior corona radiata	No	Perivascular inflammatory infiltrate	Clinical and radiological improvement	Glucocorticoids, azathioprine
Matsuo ¹² 2005	33 M	7	Basal ganglia	Pleocytosis 26 mm ³ (mononuclear), normal glucose and protein levels. No oligoclonal bands	Reactive gliosis with inflammatory infiltrate	Improvement	3 glucocorticoid boluses
Schmolck ³⁰ 2005	39 M	5	Left thalamus	No	No	Radiological improvement	Dexamethasone, monthly cyclophosphamide boluses

Table 1 (Continued)

Author	Age (years) Sex	History of Behçet's disease (years)	Lesion site	Lumbar puncture	Pathological findings	Outcome	Treatment
Darmoul ¹⁰ 2006	38 M	–	Left thalamus	–	No	Radiological improvement	Glucocorticoids, immunosuppressive agents
Appenzeller ⁴ 2006	43 F	20	Right thalamus, lentiform nucleus, subthalamic area and peduncle	No	Gliosis with gemistocytic astrocyte	Disappearance of the mass	Dexamethasone 4 mg/day IV, methylprednisolone 1 g/3 days IV, oral prednisone 60 mg/day, cyclophosphamide
Kösters ¹³ 2006	30 M	No history prior to diagnosis	Frontoparietal region	Normal cell counts, glucose levels and protein levels. No malignant cells	Lymphocytic vasculitis of small vessels	Improvement	Dexamethasone, azathioprine
Heo ⁹ 2008	47 M	10	Multiple masses in left pons region and left parietal cortex	No	Perivascular lymphocytic infiltrate, focal necrosis, gliosis, foamy histiocytes	Reduced mass size	High-dose glucocorticoids
Varoglu ²⁹ 2010	38 M	–	Mesencephalon, bilateral basal ganglia, posterior limb of internal capsule and centrum semiovale	No	Nontumoral lesions	Reduced lesion size	–
Bouomrani ³² 2010	45 M	17	Brainstem	–	No	Improvement	Cyclosporine, prednisone, cyclophosphamide
Noel ¹⁴ 2012	57 F	11	Lenticulocapsular	Aseptic meningitis	–	Improvement	Methylprednisolone, cyclophosphamide
	47 M	3	Peduncles, basal ganglia	–	–	Death	Glucocorticoids, azathioprine, cyclophosphamide
	48 M	10	Lenticulocapsular	Aseptic meningitis		Improvement	Methylprednisolone, cyclophosphamide
	34 M	No history prior to diagnosis	Thalamocapsular		Necrosis with inflammatory infiltrate, and infiltration by neutrophils, lymphocytes and macrophages compatible with vasculitis	Improvement	Methylprednisolone, cyclophosphamide
	30 M	3	Lenticulocapsular	Aseptic meningitis	–	Improvement	Prednisone, cyclophosphamide
Shapiro ²⁵ 2012	30 M	10	Cerebral peduncle	Pleocytosis with negative cultures		Good response	Glucocorticoids, infliximab and subsequent tocilizumab with good response
Martínez-Estupiñan ²⁴ 2014	23 M	4	Cerebellum	Aseptic meningitis	Reactive changes	Poor response	Glucocorticoids, azathioprine, adalimumab; subsequent tocilizumab, cyclophosphamide, rituximab and plasmapheresis

–: unknown; F: female; IV: intravenous; M: male.

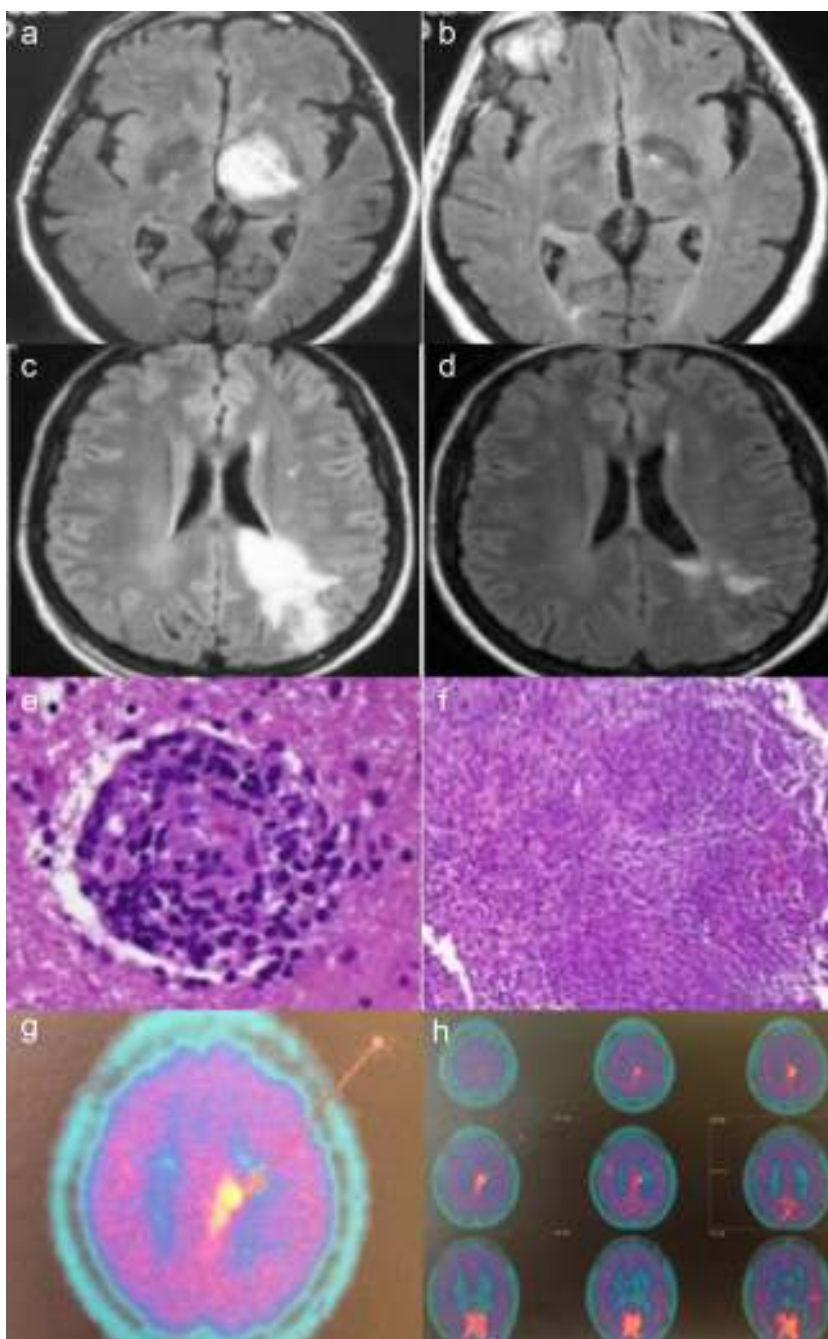


Fig. 1a-h. Case no. 1: Axial fluid-attenuated inversion recovery (FLAIR) magnetic resonance image (MRI) shows a hyperintense lesion in left thalamus (a). In an image acquired 2 months later, complete resolution of the lesion is observed (b). Case no. 2: Axial FLAIR MRI shows a hyperintense lesion in white matter of the left frontoparietal region, extending to the cortex and corpus callosum, in a gadolinium-enhanced image (c). MRI performed after 20 days of corticosteroid therapy shows a significant reduction in the hyperintense area (d). Histopathological findings in brain biopsy show a perivascular lymphocytic infiltrate with blood vessel involvement (hematoxylin-eosin) (e). Granulomatous inflammatory infiltrate (hematoxylin-eosin) (f). Brain ^{11}C -methionine positron emission tomography (PET) images showing parasagittal deposition of ^{11}C -methionine suggestive of possible lymphoma (g and h).

walking and agraphia. He mentioned a 35-year history of recurrent oral ulcers, and that sores had appeared on his genitals over the preceding 6 months, accompanied by folliculitis in the genital region and lower extremities. In the physical examination, he was found to have temporospatial disorientation; bradypsychia; right facial, brachial and femoral paresis (4/5); and tendency to list or veer toward the right when walking; together with oral and genital ulcers. The most noteworthy laboratory findings were elevated acute phase reactant levels, negative results in serological tests for *Brucella*, syphilis, hepatitis B virus, hepatitis C virus and human immunodeficiency virus, and negative findings

in an autoimmunity study. He tested positive for HLA B51. Brain magnetic resonance imaging (MRI) revealed the presence of a space-occupying lesion in left thalamus (Fig. 1.1). An angiographic study of the supra-aortic trunks revealed small-vessel disease and atheromatous lesions in the carotid bifurcations, as well as saccular aneurysms and infundibula, with images of vascular nidi in the left carotid territory suggestive of vasculitis. Thoracoabdominal computed tomography was normal. Lumbar puncture yielded clear cerebrospinal fluid, with an unremarkable protein content, without oligoclonal bands. As NBD was suspected, treatment was initiated with methylprednisolone pulse therapy, followed

by oral prednisone (1 mg/kg body weight [bw]/day), colchicine (1 mg/12 h) and oral azathioprine (2 mg/kg bw/day). The patient's clinical status improved, his genital ulcers disappeared and there was no evidence of the neurological manifestations. After 3 months of treatment, he underwent follow-up brain MRI which revealed the complete resolution of the lesion (Fig. 1.2). After 15 years of follow-up, the patient has no clinical neurological symptoms and is receiving absolutely no treatment. However, he has had sporadic oral aphthae, which have responded well to colchicine.

Case no. 2

The second patient was a 35-year-old woman who had generalized seizures and a 2-month history of paresthesia in the right malar region. The results of the physical examination were normal. Laboratory analyses showed elevated acute phase reactant levels, negative results in serological tests for human immunodeficiency virus, hepatitis B virus and hepatitis C virus, and a negative autoimmunity study. Brain MRI revealed the presence of an intraparenchymal infiltrative lesion affecting left frontoparietal region, with enhanced images following gadolinium administration (Fig. 1.3), which was diagnosed as a brain tumor. Lumbar puncture yielded clear, acellular fluid with slightly elevated protein content and no oligoclonal bands. Treatment was begun with intravenous dexamethasone (12 mg/day), which was subsequently tapered. Twenty days later, brain MRI showed a significant reduction in the size of the lesion (Fig. 1.4). ¹¹C-methionine positron emission tomography (PET) of the brain suggested the presence of cerebral lymphoma (Figs. 1.7 and 1.8). The brain mass was biopsied, and the histological study revealed the presence of a focal necrotizing granulomatous infiltrate with lymphocytic vasculitis (Figs. 1.5 and 1.6). Ziehl-Neelsen, periodic acid Schiff (PAS) and silver stains were negative. The results of thoracoabdominal computed tomography, ⁶⁷Gallium scintigraphy and a transbronchial biopsy ruled out sarcoidosis. Three months later, the patient developed oral and genital ulcers. She tested positive for HLA B51. With findings indicative of NBD, treatment was begun with monthly cyclophosphamide pulses (1 g/month) plus tapering glucocorticoid doses. After 5 months with this treatment, she had another seizure, and brain MRI performed at that time showed that the lesion had increased in size. As cyclophosphamide was considered to be ineffective, it was replaced by oral azathioprine (2 mg/kg bw/day) and the prednisone dose was increased to 30 mg/day, after which it was tapered. Four months later, there was no evidence of improvement in the lesion on brain MRI, and the decision was made to start treatment with intravenous infliximab (3 mg/kg bw every 8 weeks). After 8 doses of infliximab, there was a significant reduction in the size of the mass, but the patient developed diffuse joint pain and refused to continue the treatment. It was replaced by adalimumab, which she tolerated well. At the time of this writing, 5 years later, she continues to receive subcutaneous adalimumab (40 mg/15 days) as single-drug therapy. Her tolerance is well and the brain lesion has not progressed. Over the course of the disease, she has had episodes of oral ulcers that responded to symptomatic treatment.

Discussion

The clinical presentation and course of NBD complicate the diagnosis of this condition.⁵ It can present either in the acute form, which responds well to treatment with glucocorticoids and immunosuppressive agents, or in the progressive or chronic form (in which high interleukin 6 [IL-6] concentrations have been reported in cerebrospinal fluid), which is normally resistant to glucocorticoid, cyclophosphamide and azathioprine therapy. These patients have been found to have a better response to methotrexate

and/or infliximab.^{15–17} The presence of lesions compatible with pseudotumors on brain MRI is very rare in NBD, especially as the form of onset of the disease.^{2,4} The neurological manifestations of BD usually appear from 2 to 4 years after the first clinical sign. However, cases of NBD in which the neurological manifestations preceded other signs of the disease have been reported in the scientific literature.^{18,19} For this reason, when there is a single brain lesion in the absence of other signs, such as oral and genital ulcers, the diagnosis of BD proves to be complicated.

The differential diagnosis of NBD includes multiple sclerosis, infections, vascular disease and tumors. While both computed tomography and MRI of the brain are sensitive imaging techniques for the diagnosis of lesions, the sensitivity of the latter is greater.¹⁹ In brain MRI, the finding is described as a hyperintense signal on T2-weighted images, located predominantly at the diencephalic mesencephalic junction and in the basal ganglia,^{3,20–22} although the lesion is sometimes found in the periventricular white matter. This makes it difficult to differentiate between NBD and multiple sclerosis. However, multiple locations are reported in the scientific literature (Table 1), and its presentation has even been described as a hypointense mass on T2-weighted images.⁶ To differentiate it from a tumor in the definitive diagnosis, it is sometimes necessary to perform a brain biopsy, as in the second case reported here.

The histological study of biopsies of brain pseudotumors in NBD reveals a perivascular inflammatory infiltrate, gliosis, necrosis or neuronal loss.^{7,8,11,23}

Treatment with glucocorticoids, as well as the use of other immunosuppressive agents (cyclophosphamide or azathioprine), is accompanied by a rapid response, with a reduction in size or even the disappearance of the lesion.

To date, 27 cases of pseudotumors developing in the course of NBD have been reported in the scientific literature (PubMed: 1987–2014; search terms: neuro-Behçet, pseudotumoral). The Table shows the clinical characteristics of these lesions. The reported cases suggest that pseudotumors develop more often in men (n = 18, 66.7%) than in women, with a mean age at presentation of 38 years (range, 16–59 years); the most common site was the thalamus and basal ganglia. All the patients described were initially treated with high-dose oral or intravenous glucocorticoids. Other immunosuppressive agents, such as azathioprine, cyclophosphamide, methotrexate and chlorambucil, were added.

The patient in our first case responded rapidly to treatment with glucocorticoids and azathioprine, whereas the second patient required biological therapy with anti-tumor necrosis factor- α and infliximab at first and, subsequently, adalimumab. This is one of the few cases of the use of biological therapy for the management of these patients reported in the literature.^{24,25}

A pseudotumor in NBD should be considered in the differential diagnosis of brain masses, especially when a good clinical response is achieved after treatment with glucocorticoids. Biopsy may sometimes be necessary to confirm the diagnosis.

Ethical Disclosures

Protection of human and animal subjects. The authors declare that no experiments were performed on humans or animals for this study.

Confidentiality of data. The authors declare that they have followed the protocols of their work center on the publication of patient data.

Right to privacy and informed consent. The authors declare that no patient data appear in this article.

Conflicts of Interest

The authors declare they have no conflicts of interest.

References

- Akman-Demir G, Serdaroglu P, Taşçı B. Clinical patterns of neurological involvement in Behçet's disease: evaluation of 200 patients. The Neuro-Behçet study Group. *Brain*. 1999;122:2171–82.
- Al-Araji A, Kidd DP. Neuro-Behçet's disease: epidemiology, clinical characteristics, and management. *Lancet Neurol*. 2009;8:192–204.
- Simizu T, Ehrlich GE, Inaba G, Hayashi K. Behçet disease [Behçet syndrome]. *Semin Arthritis Rheum*. 1979;8:223–60.
- Appenzeller S, de Castro R, Queiroz LS, Madegan L, Soledade C, Zanardi VA, et al. Brain tumor-like lesion in Behçet disease. *Rheumatol Int*. 2006;26:577–80.
- Farah S, Al-Shubaili A, Montaser A, Hussein JM, Malaviya AN, Mukhtar M, et al. Behçet syndrome: a report of 41 patients with emphasis on neurological manifestations. *J Neurol Neurosurg Psychiatry*. 1998;64:382–4.
- Tuzgen S, Kaya AH, Erdinçler D, Oguzoglu SA, Ulu O, Saip S. Two cases of neuro-Behçet's disease mimicking cerebral tumor. *Neurol India*. 2003;51:376–8.
- Bennett DL, McCabe DJ, Stevens JM, Misfud V, Kitchen ND, Giovannoni G. Tumor-like neuro-Behçet disease. *Neurology*. 2004;24:709.
- Imoto H, Nishizaki T, Nogami K, Sakamoto K, Nomura S, Akimura T, et al. Neuro-Behçet's disease manifesting as a neoplasm-like lesion case report. *Neurol Med Chir*. 2002;42:406–9.
- Heo JH, Lee ST, Chu K, Kim M. Neuro-Behçet's disease mimicking multiple brain tumors: diffusion-weighted MR study and literature review. *J Neurol Sci*. 2008;264:177–81.
- Darmoul M, Habib Bouhaouala M, Smida H, Hedi Dougui M. Pseudo-tumoral neuro-Behçet disease. *Rev Neurol*. 2006;162:643–7.
- Park JH, Jung MK, Bang CO, Park HK, Sung KB, Ahn MY, et al. Neuro-Behçet's disease mimicking a cerebral tumor: a case report. *J Korean Med Sci*. 2002;17:718–22.
- Matsuo K, Yamada K, Nakajima K, Nakagawa M. Neuro-Behçet disease mimicking brain tumor. *Am J Neuroradiol*. 2005;26:650–3.
- Kösters K, Boss MM, Wesseling P, Smeets SM, van der Ven AJ, Bredie SJ. An unusual cause of a cerebral tumour in a young patient. *Neth J Med*. 2006;64:152–63.
- Noel N, Hutié M, Wechsler B, Vignes S, Le Thi Huong-Boutin D, Amoura Z, et al. Pseudotumoral presentation of neuro-Behçet's disease: case series and review of literature. *Rheumatology (Oxford)*. 2012;51:1216–25.
- Kikuchi H, Aramaki K, Hirohata S. Effect of infliximab in progressive Neuro-Behçet's syndrome. *J Neurol Sci*. 2008;272:99–105.
- Pipitone N, Olivieri I, Padula A, D'Angelo S, Nigro A, Zuccoli G, et al. Infliximab for the treatment of Neuro-Behçet disease: a case series and review of the literature. *Arthritis Rheum*. 2008;59:285–90.
- Borhani Haghighi A, Safari A. Proposing an algorithm for treatment of different manifestations of neuro-Behçet's disease. *Clin Rheumatol*. 2010;29:683–6.
- Kocer N, Islak C, Siva A, Saip S, Akman C, Kantarci O, et al. CNS involvement in neuro-Behçet syndrome: an MRI study. *Am J Neuroradiol*. 1999;20:1015–24.
- Tali ET, Atilla S, Keski T, Simonson T, Isik S, Yuh WTC. MRI in neuro-Behçet's disease. *Neuroradiology*. 1997;39:2–6.
- Duran J, Jurado M, Jacobelli S, Eymen G, Castiglione E, Valenzuela R, et al. Pseudotumor cerebri secondary to Behçet disease. Report of one case. *Rev Med Chil*. 2010;138:334–7.
- Kidd D, Steuer A, Denman AM, Rudge P. Neurological complications in Behçet's syndrome. *Brain*. 1999;122:2183–94.
- Khaled Bouden A, Cherif O, Boussama F, Rokbani L, Daghfous MH. Diagnostic imaging in neuro-Behçet's disease. Report of 5 cases. *Tunis Med*. 1999;77:562–71.
- Hirohata S. Histopathology of central nervous system lesions in Behçet's disease. *J Neurol Sci*. 2008;267:41–7.
- Martinez-Estupiñan L, López Longo FJ, Monteagudo I, Carreño Pérez L. Síndrome neurológico pseudotumoral de la enfermedad de Behçet en un paciente tratado con bloqueadores del factor de necrosis tumoral. *Med Clin (Barc)*. 2015;144:235–6.
- Shapiro LS, Farrell J, Borhani Haghighi A. Tocilizumab treatment for neuro-Behçet's disease, the first report. *Clin Neurol Neurosurg*. 2012;114:297–8.
- Geny C, Cesaro P, Heran F, Nguyen JP, Poirier J, Degos JD. Pseudotumoral neuro-Behçet's disease. *Surg Neurol*. 1993;39:374–6.
- Visaga M, Campos P, Bancalari E, Romero F, Hernández H, Berrocal A, et al. Neurobehçet pediátrico. Presentación de un caso y revisión de la literatura. *Rev Med Hered*. 1996;7:178–81.
- Yoshimura J, Toyama M, Sekihara Y, Tamatani S, Nagai H, Fujita S, et al. Neuro-Behçet disease mimicking a thalamic tumor. *No Shinkei Geka*. 2001;29:527–31.
- Varoglu AO. A case of Neuro-Behçet disease mimicking gliomatosis cerebri. *Am J Neuroradiol*. 2010;31:E1.
- Schmolck H. Large thalamic mass due to neuro-Behçet disease. *Neurology*. 2005;65:436.
- Ben Taarit C, Turki S, Ben Maïz H. Pseudotumoral neurobehçet: a case report. *J Mal Vasc*. 2002;27:93–5.
- Bouomrani S, Hammami S, Braham R, Mahjoub S. Ciclosporin-associated cerebral tumor-like location of Behçet's disease. *Rev Neurol*. 2010;166:849–54.