



Images in Clinical Rheumatology

Hyperkeratotic Lesions and Pruritus in an Immunosuppressed Patient[☆]



Lesiones hiperqueratósicas y prurito en paciente inmunodeprimida

Ana Varela-Veiga,^{*} Alejandro Vilas-Sueiro, Benigno Monteagudo, Beatriz Fernández-Jorge

Servicio de Dermatología, Complejo Hospitalario Universitario de Ferrol, Área Sanitaria de Ferrol, SERGAS, Ferrol, A Coruña, Spain

ARTICLE INFO

Article history:

Received 22 January 2015

Accepted 8 May 2015

Available online 28 February 2016

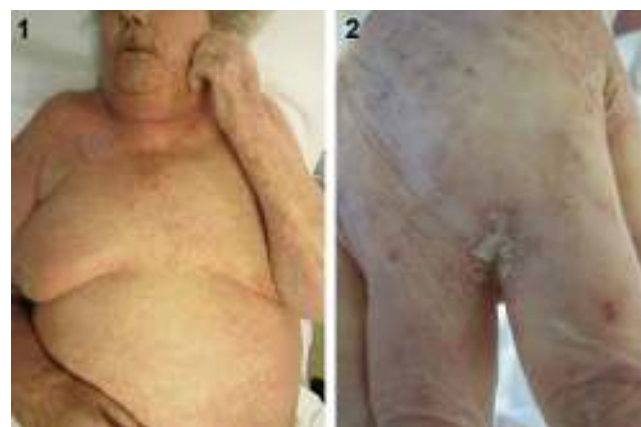Scabies is a parasitosis caused by *Sarcoptes scabiei* var. *hominis*; Norwegian scabies is a rare, highly contagious subtype that is common in immunosuppressed patients.

Case Report

The patient was an 82-year-old woman with a history of hypertension, insulin-dependent diabetes mellitus and polymyalgia rheumatica, being treated with oral corticosteroids. She was referred to the dermatology department with a 9-month history of generalized pruritus, accompanied by hyperkeratotic plaques and numerous lesions in the form of linear burrows, predominantly on her scalp and breasts and in the interdigital spaces of both hands.¹ She had applied topical corticosteroids, which had had a negative effect on her clinical status.² It was also interesting to know that individuals with whom she lived were also affected (Figs. 1 and 2).

The suspected diagnosis was reached on the basis of the clinical signs and the results of dermatoscopic examination. The microscopic study of skin scales disclosed the presence of mites and their feces and eggs, and the diagnosis was confirmed. It is important to include diseases such as ichthyosis and psoriasis in the differential diagnosis (Figs. 3–5).

Treatment is based on oral ivermectin, 5% salicylate vaseline in hyperkeratotic lesions and, in certain lesions, surgical debridement to facilitate the penetration of the topical treatment.



Figs. 1 and 2. (1) Hyperkeratotic plaques and numerous linear burrow tracks distributed on the patient's trunk, predominantly in the facial area and on her breasts. (2) Hyperkeratotic plaques and linear burrows on the back of the hands, predominantly in the interdigital spaces.

As a result of her comorbidities, the patient died of a respiratory tract infection before treatment for scabies could be initiated.

Discussion

When a patient receiving immunosuppressive therapy has generalized pruritus—predominantly at night—with crusted lesions,³ and the individuals with whom the patient lives are affected, it is essential to perform a differential diagnosis that includes Norwegian scabies, which occurs relatively frequently in these individuals. Moreover, the incidence is rising as a consequence of the increasingly widespread use of immunosuppressive agents.

[☆] Please cite this article as: Varela-Veiga A, Vilas-Sueiro A, Monteagudo B, Fernández-Jorge B. Lesiones hiperqueratósicas y prurito en paciente inmunodeprimida. *Reumatol Clin.* 2016;12:107–108.

^{*} Corresponding author.

E-mail address: ana.varela.veiga@sergas.es (A. Varela-Veiga).

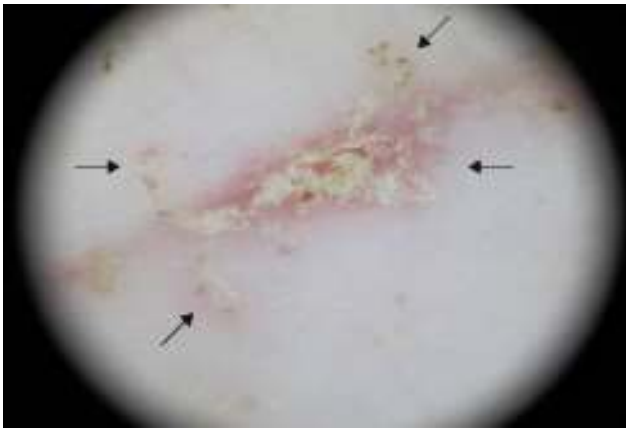
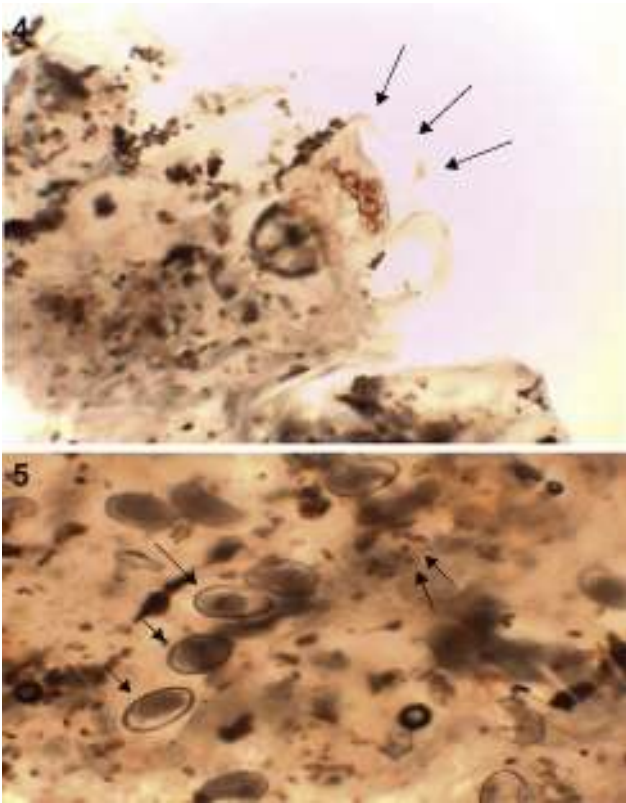


Fig. 3. Dermatoscopic image showing brownish structures, in the form of a "hang glider" at the end of the burrows (arrows).



Figs. 4 and 5. (4) Image from the histological study under direct vision (at 400×) showing a mite (arrows) and feces. (5) Histological study under direct vision (at 400×) showing eggs (arrows) and feces.

Ethical Disclosures

Protection of human and animal subjects. The authors declare that no experiments were performed on humans or animals for this study.

Confidentiality of data. The authors declare that they have followed the protocols of their work center on the publication of patient data.

Right to privacy and informed consent. The authors declare that no patient data appear in this article.

Conflicts of Interest

The authors declare they have no conflicts of interest.

Acknowledgments

The authors thank Juan Carlos Álvarez of the Pathology Department of Complejo Hospitalario Universitario de Ferrol, Ferrol Health Area, SERGAS, Ferrol, A Coruña, Spain.

References

1. Chan LY, Tang WY, Ho HH, Lo KK. Crusted scabies in two old-age home residents. *Hong Kong Med J.* 2000;6:428–30.
2. Binic I, Jankovic A, Jovanovic D, Liubenovic M. Crusted (Norwegian) scabies following systemic and topical corticosteroid therapy. *J Korean Med Sci.* 2010;25:188–91.
3. Maghrabi MM, Lum S, Joba AT, Meier MJ, Holmbeck RJ, Kennedy K. Norwegian crusted scabies: an unusual case presentation. *J Foot Ankle Surg.* 2014;53:62–6.