

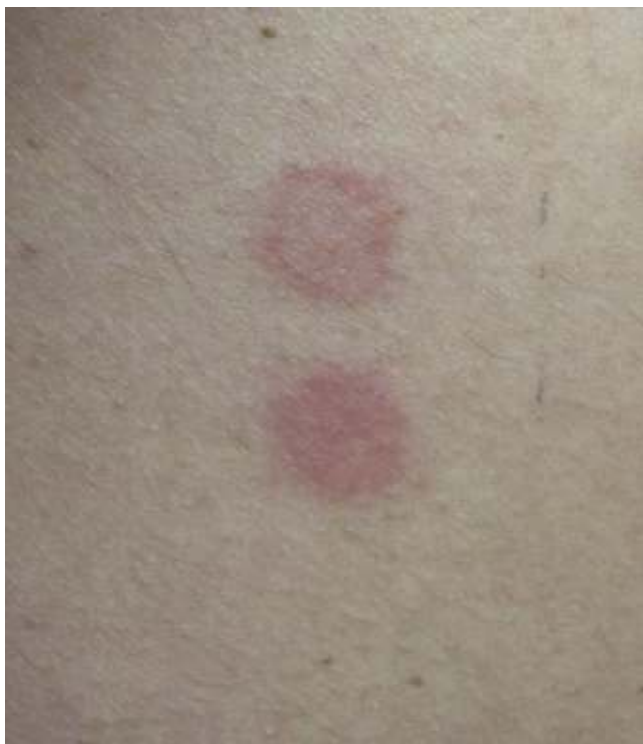

Fig. 2. Positive patch tests 72 h after exposure to methylisothiazolinone (top) and ultrasound gel (bottom).

References

1. Leiva-Salinas M, Francés L, Silvestre JF. Actualización en la dermatitis de contacto alérgica por metilcloroisotiazolinona/metilisotiazolinona y metilisotiazolinona. *Actas Dermosifiliogr.* 2014;105:840–6.
2. Verdelli A, Francalanci S, Palleschi GM. Contact allergic dermatitis due to Kathon CG contained in ultrasound gel. *Dermatitis.* 2014;25:35–6.
3. Eguino P, Sánchez A, Agesta N, Lasa O, Ratón JA, Díaz-Pérez JL. Allergic contact dermatitis due to propylene glycol and parabens in an ultrasonic gel. *Contact Dermatitis.* 2003;48:290.
4. Schwensen JF, Menné T, Andersen KE, Sommerlund M, Johanssen JD. Occupations at risk of developing contact allergy to isothiazolinones in Danish contact dermatitis patients: results from a Danish multicentre study (2009–2012). *Contact Dermatitis.* 2014;71:295–302.
5. Madsen JT, Broesby-Olsen S, Andersen KE. Undisclosed methylisothiazolinone in an ultrasound gel causing occupational allergic contact dermatitis. *Contact Dermatitis.* 2014;71:312–3.

Javier Garcia-Miguel,^{a,*} Nuria Lamas-Doménech,^b
Pere Barceló-Garcia^a

^a Servicio de Reumatología, Hospital Universitari Sagrat Cor-Quirón Salud, Barcelona, Spain

^b Servicio de Dermatología, Hospital Universitari Sagrat Cor-Quirón Salud, Barcelona, Spain

* Corresponding author.

E-mail address: 35778jgm@gmail.com (J. Garcia-Miguel).

Pulmonary Cyst Associated With Primary Sjögren's Syndrome[☆]



Quistes pulmonares asociados a síndrome de Sjögren primario

To the Editor,

More than 50% of the patients with primary Sjögren's syndrome (pSS) have extraglandular manifestations, and pulmonary manifestations are observed in 10% of this patient population.¹ In 50% of the patients, the involvement is subclinical; however, symptomatic lung disease occurs in 10%. Interstitial lung disease is the most common disorder.^{2–4} Cystic lung disease is reported much less frequently. This complication is characterized by foci of reduced lung density that have well-defined, thin walls (wall thickness less than 4 mm) and a diameter at their largest point of 1 cm.⁵ We report the cases of 3 patients with cystic lung disease associated with pSS. All of them met the 2002 American-European classification criteria for the diagnosis of Sjögren's syndrome (SS).⁶

The 3 pSS patients were diagnosed, by means of high-resolution computed tomography (HRCT) of the thorax, as having associated cystic lung disease, together with centrilobular pulmonary emphysema, predominantly in the upper lobes in 2 of the 3 patients. There was no evidence of association with other lung diseases. We did not perform a histological examination, a study that had been described in other reports published up to that time.

Patient no. 1

The first patient was a 74-year-old woman with an 18-year history of pSS. She presented with extraglandular manifestations, such as the vasculitis, polyarteritis nodosa. The most notable laboratory findings were hypergammaglobulinemia and anti-Ro and anti-La antibodies. She was being treated with oral azathioprine at a dose of 50 mg/day. During follow-up she developed functional dyspnea grade II. The results of respiratory function tests were normal, and HRCT of the thorax revealed centrilobular pulmonary emphysema, predominantly in upper lobes, and images of thin-walled cysts predominantly in lower lobes (Fig. 1a). The same treatment was maintained, and there were no changes in the pulmonary lesions in subsequent visits.

Patient no. 2

This patient was a 46-year-old woman with a 20-year history of pSS and diagnosed with IgA kappa myeloma. Her extraglandular manifestations were anemia and leukocytoclastic vasculitis, as well as polyarteritis and parotid gland enlargement. She was being treated with hydroxychloroquine (HCQ) 200 mg/day, oral pilocarpine 15 mg/day and rituximab every 6 months. Laboratory tests revealed elevated acute-phase reactant levels, anemia and lymphopenia, as well as hypergammaglobulinemia with an elevated IgG level and a monoclonal IgA kappa component. Tests for rheumatoid factor (RF), as well as anti-Ro and anti-La antibodies, were positive. During follow-up, she developed dyspnea on heavy exertion. Respiratory function tests revealed a mild restrictive ventilatory defect with a slightly reduced diffusing capacity of the lung for carbon monoxide (DLCO), and HRCT of the thorax

[☆] Please cite this article as: Masegosa-Casanova S, Riveros-Frutos A, Sanint J, Olivé A. Quistes pulmonares asociados a síndrome de Sjögren primario. *Reumatol Clin.* 2016;12:116–118.

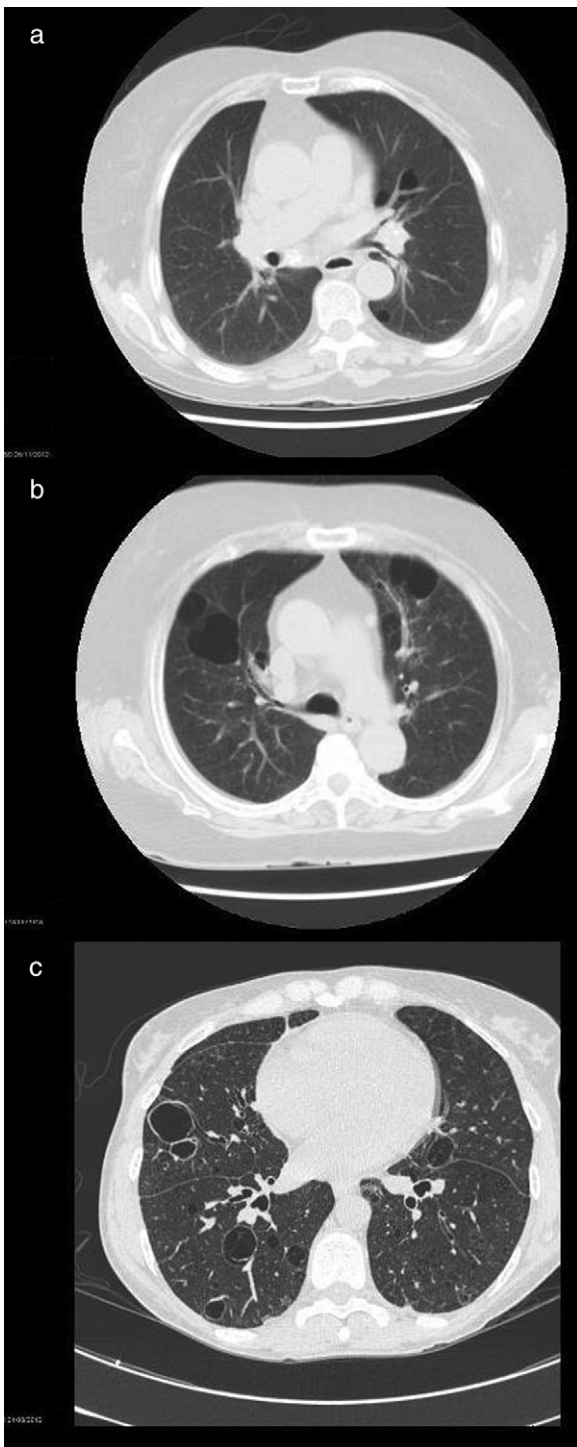


Fig. 1. High-resolution computed tomographic study: (a) image showing centrilobular emphysema and cysts; (b) bilateral cystic lung lesions, some with septa in their interior, traction bronchiectasis in both lower lobes, areas of centrilobular and paraseptal emphysema and zones of fibrotic tissue; and (c) image showing multiple bilateral thin-walled pulmonary cysts.

showed bilateral cystic lung lesions—some with septa in their interior—predominantly in the bases, traction bronchiectasis in both lower lobes, areas of centrilobular and paraseptal emphysema in upper lobes, together with linear opacities and areas of fibrotic tissue in both lung bases (Fig. 1b). No modifications were made in her treatment, and there were no changes in the cystic lesions in subsequent visits.

Patient no. 3

The third patient was a 78-year-old woman with a 15-year history of pSS who was also diagnosed with cutaneous amyloidosis. The manifestations were predominantly glandular (xerostomia and xerophthalmia), and there was no extraglandular involvement. She was receiving oral HCQ 200 mg/day. The laboratory tests revealed elevated acute-phase reactant levels, polyclonal hypergammaglobulinemia with an elevated IgG level, and positive tests for RF and anti-Ro and anti-La antibodies. During follow-up, she reported dyspnea on moderate exertion and, thus, underwent respiratory function tests, which revealed a mild restrictive ventilatory defect, with a severe reduction in DLCO. Thoracic HRCT (Fig. 1c) showed multiple bilateral thin-walled pulmonary cysts, with no evidence of nodules or changes in the air space. The findings were the same in subsequent visits.

Cystic lung disease is an uncommon condition that is rarely associated with an autoimmune inflammatory disease. The prevalence of pulmonary cysts in pSS ranges between 12% and 30% of the overall group of pulmonary manifestations. They can be found alone or in association with areas of ground glass attenuation.^{7–9} Two hypotheses have been proposed for the formation of these pulmonary cysts, both of which involve the infiltration of immunoglobulin-producing lymphocytes: a valve mechanism that causes cystic changes in the dilated alveolar region as a result of chronic inflammation and lymphoplasmocytic infiltration in peripheral regions; and the destruction of the alveolar wall, in which the direct lymphoplasmocytic infiltration of the alveoli destroys the alveolar structures and creates cystic areas. The most probable scenario involves both mechanisms.^{7,8,10} There have been few reports of pulmonary cysts associated with pSS, and the majority of the cases are found to be concomitant with other diseases, such as lymphoid interstitial pneumonitis,

lymphoproliferative processes and pulmonary amyloidosis.^{11,12} One common characteristic finding is the high erythrocyte sedimentation rate with hypergammaglobulinemia observed in all 3 cases, a direct reflection of the lymphocyte hyperactivity associated with the disease. Compared with the cases in the literature, our patients do not differ with respect to the characteristic radiological findings,¹⁰ although there have been reports of a significant association between seropositivity for anti-SSB/La and clonal lymphoproliferative disorders that we have not identified in our patients.⁷

References

- Carsons SE. Sjögren's syndrome. *Rheum Dis Clin North Am.* 2008;34:907–20.
- Hatron PY, Tillie-Leblond I, Launay D, Hachulla E, Fauchais AL, Wallaert B. Pulmonary manifestations of Sjögren's syndrome. *Presse Med.* 2011;40:e49–64.
- Crestani B, Schneider S, Adle-Biassette H, Debray MP, Bonay M, Aubier M. Respiratory manifestations during the course of Sjögren's syndrome. *Rev Respir Mal.* 2007;24:535–51.
- Yazisiz V, Arslan G, Ozbudak IH, Turker S, Erbasan F, Avci AB, et al. Lung involvement in patients with primary Sjögren's syndrome: what are the predictors. *Rheumatol Int.* 2010;30:1317–24.
- Foguem C, Launay D, Lambert M, Quemener T, Hachulla E, Wallaert B, et al. Cystic lung disease associated with Sjögren's syndrome: 2 cases. *Rev Med Interne.* 2006;27:620–4.
- Vitali C, Bombardieri S, Jonsson R, Moutsopoulos HM, Alexander EL, Carsons SE, et al., European Study Group on Classification Criteria for Sjögren's Syndrome. Classification criteria for Sjögren's syndrome: A revised version of the European criteria proposed by the American-European Consensus Group. *Ann Rheum.* 2002;61:554–8.
- Watanabe M, Naniwa T, Hara M, Arakawa T, Maeda T. Pulmonary manifestations in Sjögren's syndrome: correlation analysis between chest computed tomographic findings and clinical subsets with poor prognosis in 80 patients. *J Rheumatol.* 2010;37:365–73.
- Koyama M, Johkoh T, Honda O, Mihara N, Kozuka T, Tomiyama N, et al. Pulmonary involvement in primary Sjögren's syndrome: spectrum of pulmonary

- abnormalities and computed tomography findings in 60 patients. *J Thorac Imaging*. 2001;16:290–6.
9. Uffmann M, Kiener HP, Bankier AA, Baldt MM, Zontsich T, Herold CJ. Lung manifestation in asymptomatic patients with primary Sjögren syndrome: assessment with high resolution CT and pulmonary function tests. *J Thorac Imaging*. 2001;16:282–9.
 10. Egashira R, Kondo T, Hirai T, Kamochi N, Yakushiji M, Yamasaki F, et al. CT findings of thoracic manifestations of primary Sjögren syndrome: radiologic–pathologic correlation. *Radiographics*. 2013;33:1933–49.
 11. Hubscher O, Re R, Iotti R. Cystic lung disease in Sjögren's syndrome. *J Rheumatol*. 2002;29:2235–6.
 12. Kluka EM, Bauer PR, Aubry MC, Ryu JH. Enlarging lung nodules and cysts in a 53-year-old woman with primary Sjögren syndrome. *Chest*. 2013;143:258–61.

Sandra Masegosa-Casanova,^{a,*} Anne Riveros-Frutos,^b
Juana Sanint,^b Alejandro Olivé^b

^a Servicio de Reumatología, Hospital Universitario San Cecilio, Granada, Spain

^b Sección de Reumatología, Hospital Universitario Germans Trias i Pujol, Barcelona, Spain

* Corresponding author.

E-mail address: zuleya86@gmail.com (S. Masegosa-Casanova).

Adverse Effects of Immunosuppressive Therapy in Rheumatic Patients: Non-tuberculous Mycobacterial Infection[☆]



Efectos adversos de terapia inmunosupresora en paciente reumatológico: infección por micobacterias no tuberculosas

To the Editor,

Mycobacterium chelonae is a rapidly growing mycobacterium that causes skin and soft tissue infections after trauma in immunocompetent individuals and in immunocompromised hosts with disseminated disease, especially in patients with rheumatic diseases receiving immunosuppressive therapy.^{1–3}

We report the case of a 29-year-old woman whose medical record included systemic lupus erythematosus, sarcoidosis and a 4-year history of sickle cell anemia plus β -thalassemia. At the time of writing, she was being treated with rituximab (she had received 2 cycles of 1 g each), azathioprine 100 mg/day, methylprednisolone 16 mg/day and hydroxyurea 1 g/day. She was admitted to a quaternary care center with a 3-month history of pain in her right hip. Drug treatment with a variety of analgesics and multiple local injections in right hip and gluteus resulted in a partial improvement of her symptoms. One month later, the clinical symptoms returned and she presented with an abscess in right gluteus, with local inflammatory changes. Physical examination revealed the presence of a painful nodule. She underwent surgical drainage of the abscess, and cultures for the usual bacteria, fungi and mycobacteria (auramine–rhodamine stain and culture in Löwenstein–Jensen solid medium) were negative. Antibiotic therapy was initiated with ceftriaxone + vancomycin and ampicillin/sulbactam, with no improvement whatsoever. A biopsy was performed with the drained material, and the latter was analyzed by polymerase chain reaction (PCR) for the detection of mycobacteria, in which *M. chelonae* DNA was isolated. The patient began treatment with clarithromycin 1 g/day and moxifloxacin 400 mg/day in May 2014, with which she continued at the time of writing, with resolution of the clinical condition.

Nontuberculous mycobacteria constitute a group of species that includes *Mycobacterium abscessus* (with 3 subspecies), *M. chelonae* and *Mycobacterium fortuitum*, which are widely distributed in nature.⁴

As a pathogen in humans, *M. chelonae* has a number of clinical forms, the severity of which ranges from frequent mild skin and soft tissue infections to potentially fatal systemic infections.

Skin infection is the most common clinical condition in immunocompetent individuals, and is usually preceded by an

injury, open fracture, wound from a sharp, cutting weapon, or a surgical procedure (especially plastic surgery).⁵

In immunocompromised individuals, this pathogen causes disseminated skin infections, and the entry route or route of transmission is generally unidentified. The clinical manifestations consist of infections in organs and skin abscesses that generally affect the lower extremities. Localized injuries can also cause infections (cellulitis, abscesses and osteomyelitis), as can surgical wounds and catheters, although to a lesser degree.

It is important that general practitioners, when treating patients with autoimmune diseases and using biologic therapies, have a high index of suspicion of infection by *M. chelonae*, founded on 3 criteria: (a) a previous skin lesion, mainly from cosmetic or surgical procedures; (b) the presence of painful subcutaneous nodules and abscesses at the site of the lesion; and (c) a poor or inadequate response to the antibiotic therapy received.⁶

The diagnosis starts with the direct observation of mycobacteria in the aspirate of secretions or in the tissue obtained, using Ziehl–Neelsen or auramine–rhodamine stain, plus the performance of special cultures for the diagnosis. The classical Ziehl–Neelsen technique and the fluorescence technique with auramine–rhodamine are equally effective for the diagnosis, but around 30% of the rapidly growing mycobacteria can exhibit negative fluorescence with the auramine–rhodamine technique. Thus, when infection by rapidly growing mycobacteria is suspected, the procedure of choice is the Ziehl–Neelsen stain.

Bacteriological culture enables us to enhance the sensitivity of the diagnosis; even if the result of direct observation is negative, the disease is not ruled out. Therefore, sampling should be carried out for DNA amplification using the PCR technique, to obtain the patterns of sensitivity to first-line and second-line drugs that serve as a guide to the most adequate and effective treatment.⁷

Funding

The authors declare that they had no source of funding.

References

1. Lage R, Biccigo DG, Santos FB, Chimara E, Pereira ES, Costa AD. *Mycobacterium chelonae* cutaneous infection in a patient with mixed connective tissue disease. *An Bras Dermatol*. 2015;90:104–10.
2. Winthrop KL, Yamashita S, Beekmann SE, Polgreen PM, Infectious Diseases Society of America Emerging Infections Network. Mycobacterial and other serious infections in patients receiving anti-tumor necrosis factor and other newly approved biologic therapies: case finding through the Emerging Infections Network. *Clin Infect Dis*. 2008;46:1738–40.
3. Uslan D, Kowalski T, Wengenack N, Virk A, Wilson J. Skin and soft tissue infections due to rapidly growing *Mycobacteria*. *Arch Dermatol*. 2006;142:1287–90.
4. Alcaide F, Esteban J. Infecciones cutáneas y de partes blandas por micobacterias no tuberculosas. *Enferm Infecc Microbiol Clin*. 2010;28 Supl 1:46–50.
5. Piersimoni C, Scarparo C. Extrapulmonary infections associated with non-tuberculous *Mycobacteria* in immunocompetent persons. *Emerg Infect Dis*. 2009;15:1351–60.

[☆] Please cite this article as: Hurtado Hurtado JS. Efectos adversos de terapia inmunosupresora en paciente reumatológico: infección por micobacterias no tuberculosas. *Reumatol Clin*. 2016;12:118–119.