

7. Montenegro V, Monteiro RC. Elevation of serum IgA in spondyloarthropathies and IgA nephropathy and its pathogenic role. *Curr Opin Rheumatol*. 1999;11:265–72.

Samantha Rodríguez-Muguruza,\* Lourdes Mateo, Juana Sanint, Alejandro Olivé

Servicio de Reumatología, Hospital Universitario Germans Trias i Pujol, Badalona, Barcelona, Spain

\* Corresponding author.

E-mail address: [sam63100@hotmail.com](mailto:sam63100@hotmail.com) (S. Rodríguez-Muguruza).

## Septic Arthritis by *Streptococcus equi*\*



### Artritis infecciosa por *Streptococcus equi*

To the Editor,

*Streptococcus equi* is a Gram-positive, Lancefield group C coccal bacterium that has a close genetic link to *Streptococcus zooepidemicus*,<sup>1</sup> of which it is thought to be a direct ancestor, and is the cause of less than 2% of all the group C streptococcal infections.<sup>2</sup> It is a common pathogen in horses, cows and dogs, and can be isolated from the serous discharge of wounds.<sup>3,4</sup>

*Streptococcus equi* infection has been documented in humans who are in direct or indirect contact with animals, especially horses, although in most cases, the route of transmission has not been clarified.<sup>4</sup>

We report a case of septic arthritis caused by *Streptococcus equi* in a person who may have acquired the infection through a relative who was in contact with horses. The patient was a 72-year-old woman who presented with a 4-day history of pain, swelling and functional limitation in right knee. She had had no injuries. Her granddaughter was a veterinarian at a racetrack. She had a temperature of 38.5 °C, increased knee volume, fixed flexion of 30°, erythema and local warmth. There was no evidence of tegmental damage either in or around the knee. Ultrasound showed degenerative changes in the knee, a compressible anechoic area in both suprapatellar recesses associated with a marked proliferation of homogeneous synovial fluid (SF) (Fig. 1) and the power Doppler signal was 1+/3+. In the other knee, only similar degenerative changes were observed.

Arthrocentesis yielded 90 mL of synovial fluid with inflammatory features.

The results of laboratory tests included a leukocyte count of 16 000/mm<sup>3</sup> (90% neutrophils), C-reactive protein level of 210 mg/L and procalcitonin level of 1.70 ng/mL. In SF, there were no signs of microorganisms, the cell count was 20 000 cells/mL, and the glucose and protein concentrations were 30 mg/dL and 2.3 g/dL, respectively.

The patient underwent surgical lavage and was admitted to the hospital, and empirical treatment with ceftriaxone 2 g/day and cloxacillin 500 mg/6 h was begun.

As SF and peripheral blood cultures were positive for *Streptococcus equi*, treatment was changed to 1,200,000 U/day of penicillin G. As the patient's fever and pain persisted, surgical lavage was repeated 10 days after her admission. The outcome was favorable and she was discharged after 5 weeks of intravenous therapy.

*Streptococcus equi* is a pathogen that causes "strangles", a lymphoproliferative disease that can affect horses, donkeys and cattle, although subclinical infection has also been documented in dogs.<sup>3,5</sup> This disease produces enlargement of the cervical lymph nodes and is associated with upper airway symptoms in animals. The lympho-

cyte proliferation can produce skin necrosis and neck abscesses. Both the serous discharges from abscesses and saliva of the diseased animal are sources of transmission to other animals or to humans.<sup>3,5–7</sup> Infection in humans mediated by the consumption of dairy products from infected animals has also been documented.<sup>8,9</sup>

Although a number of cases of *Streptococcus equi* infection have been reported in humans,<sup>2,10–13</sup> septic arthritis is a highly uncommon finding.<sup>9,11,14–16</sup> Information on the epidemiological burden of this pathogen as the causative agent is not available.

A history involving a connection to horses, as occurred in our patient, has not been demonstrated in most of the case reports.<sup>17</sup> However, despite this link, it was not possible to determine the mechanism that produced the infection.

*Streptococcus equi* infection responds favorably to treatment with penicillins, although cases of drug resistance have been reported and the clinical course is variable.<sup>17</sup>

Another interesting finding was the marked synovial proliferation, which could hardly be attributed to the similar degenerative changes in both knees.

*Streptococcus equi* is an uncommon cause of arthritis due to group C streptococci that should be considered in the differential diagnosis of arthritis in a single joint in patients who are in contact with animals, especially horses. The clinical course is variable and, although, theoretically, it is sensitive to beta-lactams, antibiotic resistance has been documented. Our patient also had a marked synovial proliferation and an increased procalcitonin level, but the cellularity in SF was not consistent with joint infection. This protein is a precursor of calcitonin, and has been included as a key test in the diagnosis of inflammatory processes mediated by bacterial agents. Its concentration increases within the first 6 h of the production of bacteremia, and its specificity ranges between 91% and 93%, depending on the disease.<sup>18</sup> A recent study demonstrated the value of procalcitonin in cases in which the suspicion of septic arthritis overlapped that of gout.<sup>19</sup> It was this finding that, despite

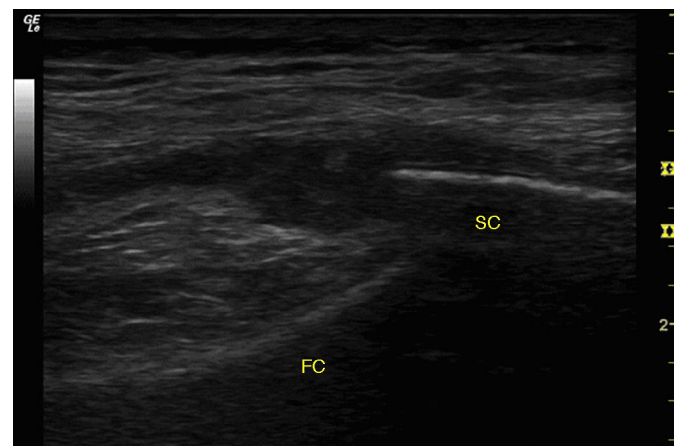


Fig. 1. Ultrasound of right knee. Longitudinal view of the external parapatellar recess showing marked synovial proliferation of homogeneous aspect. FC, femoral cortex immediately adjacent to the lateral femoral condyle; SC, superficial cortex of the lateral patellar border.

\* Please cite this article as: Guillén Astete CA, Sánchez Gómez N, Luque Alarcón M. Artritis infecciosa por *Streptococcus equi*. *Reumatol Clin*. 2016;12:237–238.

the low cellularity of the SF, induced us to continue to suspect septic arthritis.

## References

- Lindmark H, Nilsson M, Guss B. Comparison of the fibronectin-binding protein FNE from *Streptococcus equi* subspecies equi with FNZ from *S. equi* subspecies zooepidemicus reveals a major and conserved difference. *Infect Immun*. 2001;69:3159–63.
- Barnham M, Kerby J, Chandler RS, Millar M.R. Group C streptococci in human infection: a study of 308 isolates with clinical correlations. *Epidemiol Infect*. 1989;102:379–90.
- Abbott Y, Acke E, Khan S, Muldoon EG, Markey BK, Pinilla M, et al. Zoonotic transmission of *Streptococcus equi* subsp. zooepidemicus from a dog to a handler. *J Med Microbiol*. 2010;59:120–3.
- Pelkonen S, Lindahl SB, Suomala P, Karhukorpi J, Vuorinen S, Koivula I, et al. Transmission of *Streptococcus equi* subspecies zooepidemicus infection from horses to humans. *Emerg Infect Dis*. 2013;19:1041–8.
- Priestnall S, Eres K. *Streptococcus zooepidemicus*: an emerging canine pathogen. *Vet J Lond Engl*. 2011;188:142–8.
- Brouwer MC, Kasanmoentalib ES, Opstelten FWJ, van der Ende A, van de Beek D. A horse bite to remember. *Lancet*. 2010;376:1194.
- Collazos J, Echevarria MJ, Ayarza R, de Miguel J. *Streptococcus zooepidemicus* septic arthritis: case report and review of group C streptococcal arthritis. *Clin Infect Dis*. 1992;15:744–6.
- Kuusi M, Lahti E, Virolainen A, Hatakka M, Vuento R, Rantala L, et al. An outbreak of *Streptococcus equi* subspecies zooepidemicus associated with consumption of fresh goat cheese. *BMC Infect Dis*. 2006;6:36.
- Bordes-Benitez A, Sánchez-Oñoro M, Suárez-Bordón P, García-Rojas AJ, Saéz-Nieto JA, González-García A, et al. Outbreak of *Streptococcus equi* subsp. zooepidemicus infections on the island of Gran Canaria associated with the consumption of inadequately pasteurized cheese. *Eur J Clin Microbiol Infect Dis*. 2006;25:242–6.
- Behnes M, Mashayekhi K, Geginat G, Borggreffe M. Horse bacterium causes human pericardial and pleural effusion. *Infection*. 2010;38:501–4.
- Lee AS, Dyer JR. Severe *Streptococcus zooepidemicus* infection in a gardener. *Med J Aust*. 2004;180:366.
- Bhatia R, Bhanot N. Spondylodiscitis secondary to *Streptococcus equi* subspecies zooepidemicus. *Am J Med Sci*. 2012;343:94–7.
- Barnham M, Ljunggren A, McIntyre M. Human infection with *Streptococcus zooepidemicus* (Lancefield group C): three case reports. *Epidemiol Infect*. 1987;98:183–90.
- Gorman PW, Collins D.N. Group C streptococcal arthritis A case report of equine transmission. *Orthopedics*. 1987;10:615–6.
- González Terán B, Roiz MP, Ruiz Jimeno T, Rosas J, Calvo-Alén J. Acute bacterial arthritis caused by group C streptococci. *Semin Arthritis Rheum*. 2001;31:43–51.
- Steinfeld S, Galle C, Struelens M, De Gheldre Y, Farber CM, Appelboom T, et al. Pyogenic arthritis caused by streptococcus equisimilis (group-C streptococcus) in a patient with AIDS. *Clin Rheumatol*. 1997;16:314–6.
- Friederichs J, Hungerer S, Werle R, Militz M, Bühren V. Human bacterial arthritis caused by *Streptococcus zooepidemicus*: report of a case. *Int J Infect Dis*. 2010;14 Suppl. 3:e233–5.
- Name Bayona O, Fernández López A, Luaces Cubells C. Procalcitonina: una nueva herramienta diagnóstica en la infección bacteriana. *Med Clin (Barc)*. 2002;119:706–14.
- Guillen Astete C, Medina Quiñones C, Bachiller Corral J. Valor de la procalcitonina en el diagnóstico diferencial de la monoartritis microcristalina e infecciosa. *Emergencias*. 2013;25:237–8.

Carlos Antonio Guillén Astete,<sup>a,\*</sup> Nancy Sánchez Gómez,<sup>b</sup>  
Mónica Luque Alarcón<sup>c</sup>

<sup>a</sup> Servicio de Reumatología y Servicio de Urgencias, Hospital Universitario Ramón y Cajal, Madrid, Spain

<sup>b</sup> Servicio de Medicina Interna, Hospital Universitario Ramón y Cajal, Madrid, Spain

<sup>c</sup> Servicio de Neurología, Hospital del Tajo, Aranjuez, Madrid, Spain

\* Corresponding author.

E-mail address: [cguillen.hrc@salud.madrid.org](mailto:cguillen.hrc@salud.madrid.org) (C.A. Guillén Astete).

## *Serratia marcescens* septic sternoclavicular joint arthritis: A case report<sup>☆</sup>



### Artritis séptica esternoclavicular por *Serratia marcescens*: a propósito de un caso

To the Editor,

Septic arthritis of the sternoclavicular joint accounts for less than 1% of all the cases of septic arthritis. It is frequently associated with predisposing conditions, such as intravenous drug abuse or diabetes. Given the infrequency of the disease, the diagnosis is often delayed.<sup>1</sup> *Serratia marcescens* is a Gram-negative enterobacterium associated with a wide range of nosocomial infections.<sup>2</sup>

We report a case of sternoclavicular joint septic arthritis caused by this enterobacterium. The patient was a 70-year-old man diagnosed with hypertension, type 2 diabetes, dyslipidemia and chronic ischemic heart disease in the form of unstable angina, with percutaneous revascularization of anterior descending and circumflex arteries. On admission to the hospital for unstable angina, catheterization revealed no evidence of new coronary lesions. On the third day of his hospital stay, he experienced chills, pain in his left shoulder and dysphagia. On clinical examination, the only notable findings were an arterial blood pressure of 150/76 mmHg, body temperature of 38 °C, edema and erythema in left sternoclavicular joint, and pain on moving his left arm. The analytical findings included a hemoglobin level of 11.2 g/dL and leukocyte count at 3600/mm<sup>3</sup>, with 7.5% lymphocytes and 85.8% neutrophils, platelet

count of 84,000/mm<sup>3</sup> and C-reactive protein at 325 mg/L. Blood cultures revealed the presence of *Serratia marcescens* sensitive to quinolones, carbapenems, aminoglycosides and third-generation cephalosporins. Computed tomography of his neck and chest (Fig. 1) confirmed the presence of an infectious process in the sternoclavicular joint, with no signs of local complications. The results of an otorhinolaryngological examination were normal. It was not possible to obtain a sample of joint fluid. There was no evidence of endocarditis on transthoracic echocardiography. He was treated with 1 g/day of intravenous ertapenem for 4 weeks, followed by a

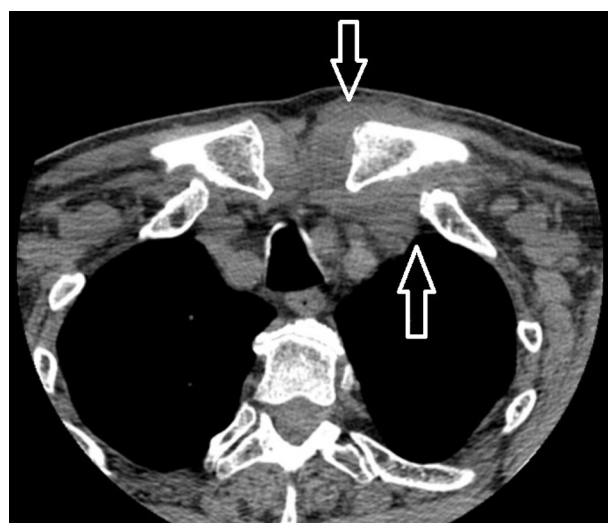


Fig. 1. Augmentation of soft tissue and obliteration of fat planes associated with the inflammatory-infectious process in left sternoclavicular joint (arrows).

<sup>☆</sup> Please cite this article as: Amao-Ruiz E, Correa-Fernandez AM, de la Fuente Galán L. Artritis séptica esternoclavicular por *Serratia marcescens*: a propósito de un caso. *Reumatol Clin*. 2016;12:238–239.