



Sociedad Española
de Reumatología -
Colegio Mexicano
de Reumatología

Reumatología Clínica

www.reumatologiaclinica.org



Images in Clinical Rheumatology

Hybrid SPECT/CT using 3D reconstruction with ^{99m}Tc -HMPAO-labeled leukocytes in the diagnosis of an infectious process of unknown origin in foot[☆]



SPECT/TC con leucocitos autólogos marcados con ^{99m}Tc -HMPAO y reconstrucción 3D híbrida en el diagnóstico de proceso infeccioso no filiado en pie

Juan José Martín-Marcuarta,^{*} Víctor Manuel Pachón-Garrudo, Jose Antonio Lojo-Ramírez, Rosario García-Jiménez

Servicio de Medicina Nuclear, Hospital Universitario Virgen del Rocío, Sevilla, Spain

ARTICLE INFO

Article history:

Received 1 February 2016

Accepted 20 February 2016

Available online 3 February 2017

The patient was a 45-year-old man with nothing remarkable in his medical records, who presented with a 6-month history of pain and swelling in the dorsum of right foot (Fig. 1D) with purulent exudate between 4th and 5th toes. Cultures had repeatedly been negative, and he did not improve with intensive antibiotic therapy. The radiological images were not conclusive, and he came to our department to undergo scintigraphy¹ with ^{99m}Tc -hexamethylpropyleneamine oxime (HMPAO)-labeled leukocytes (Fig. 1A and B). There was an increased uptake of the tracer

in the fourth metatarsal 3 h after injection of the radiotracer.² The study was completed with the acquisition of a single photon emission computed tomography/computed tomography and 3D reconstruction (3D SPECT/CT) which made it possible to locate the infectious process in soft tissue of the dorsum of the foot. It was related to a foreign body in the distal third of the fourth metatarsal (Fig. 1C), unknown until then. After its surgical removal, the patient's improvement was excellent in a few weeks.

[☆] Please cite this article as: Martín-Marcuarta JJ, Pachón-Garrudo VM, Lojo-Ramírez JA, García-Jiménez R. SPECT/TC con leucocitos autólogos marcados con ^{99m}Tc -HMPAO y reconstrucción 3D híbrida en el diagnóstico de proceso infeccioso no filiado en pie. Reumatol Clin. 2017;13:178–179.

^{*} Corresponding author.

E-mail address: jjmarcuarta@gmail.com (J.J. Martín-Marcuarta).

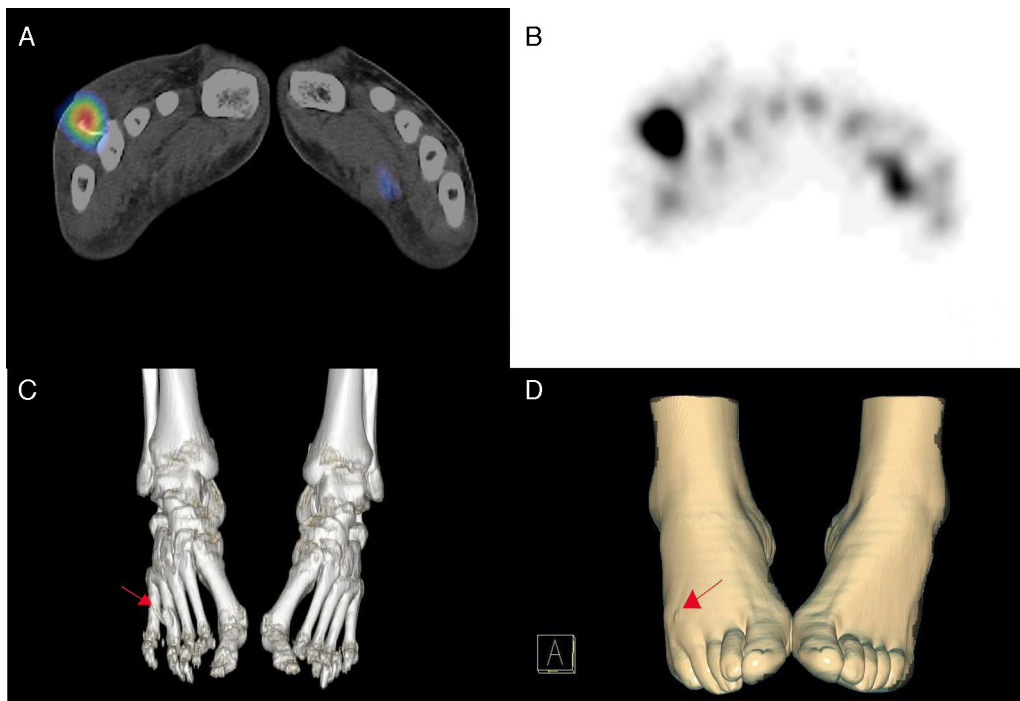


Fig. 1. Single photon emission computed tomography/computed tomography (SPECT/CT) after the intravenous administration of autologous leukocytes labeled with 20 mCi of ^{99m}Tc -hexamethylpropyleneamine oxime (HMPAO). Hybrid SPECT/CT image (A) and SPECT image (B) showing the increased uptake in the fourth metatarsal of right foot. 3D reconstruction with bone window (C) that enables the correlation of the scintigraphic findings with the presence of a foreign body (arrow), that can be discerned by the impression it leaves on the surface of the skin (D).

Informative Message

The hybrid SPECT/CT image with ^{99m}Tc -HMPAO-labeled autologous leukocytes and 3D reconstruction is a highly accurate tool for the noninvasive diagnosis of infectious processes associated with invisible foreign bodies using morphological imaging techniques.

Ethical Disclosures

Protection of human and animal subjects. The authors declare that no experiments were performed on humans or animals for this study.

Confidentiality of data. The authors declare that they have followed the protocols of their work center on the publication of patient data.

Right to privacy and informed consent. The authors declare that no patient data appear in this article.

Conflicts of Interest

The authors declare they have no conflicts of interest.

References

1. Gludemans AW, de Vries EF, Vermeulen LE, Slart RH, Dierckx RA, Signore A. A large retrospective single-centre study to define the best image acquisition protocols and interpretation criteria for white blood cell scintigraphy with ^{99m}Tc -HMPAO-labelled leucocytes in musculoskeletal infections. *Eur J Nucl Med Mol Imaging*. 2013;40:1760–9.
2. Erba PA, Gludemans AW, Veltman NC, Sollini M, Pacilio M, Galli F, et al. Image acquisition and interpretation criteria for ^{99m}Tc -HMPAO-labelled white blood cell scintigraphy: results of a multicentre study. *Eur J Nucl Med Mol Imaging*. 2014;41:615–23.