




Sociedad Española  
de Reumatología -  
Colegio Mexicano  
de Reumatología

# Reumatología Clínica

www.reumatologiaclinica.org



## Case report

# Necrotizing fasciitis in a patient receiving tocilizumab for rheumatoid arthritis – Case report



Diana Rosa-Gonçalves\*, Miguel Bernardes, Lúcia Costa

Rheumatology Department, Centro Hospitalar São João, Portugal

## ARTICLE INFO

### Article history:

Received 3 August 2016

Accepted 28 October 2016

### Keywords:

Rheumatoid arthritis

Infection

Necrotizing fasciitis

Skin

Tocilizumab

Tumor necrosis factor antagonists

## ABSTRACT

We present a case of necrotizing fasciitis in a 66-year-old Caucasian woman with rheumatoid arthritis receiving tocilizumab, and provide a review of published cases. The patient exhibited no systemic symptoms and discreet cutaneous inflammatory signals at presentation. She was successfully treated with broad-spectrum empiric antibiotic therapy and surgical debridement.

© 2016 Elsevier España, S.L.U. and Sociedad Española de Reumatología y Colegio Mexicano de Reumatología. All rights reserved.

### Palabras clave:

Artritis reumatoide

Infección

Fascitis necrosante

Piel

Tocilizumab

Antagonistas del factor de necrosis tumoral alfa

## Fascitis necrosante en un paciente bajo tocilizumab para la artritis reumatoide. Presentación de un caso

### R E S U M E N

Presentamos un caso de fascitis necrosante en una mujer caucásica de 66 años de edad con artritis reumatoide en tratamiento con tocilizumab y se ha realizado una revisión de casos publicados. La paciente ha presentado falta de síntomas sistémicos y señales inflamatorias cutáneas discretas. Ha sido tratada con éxito con terapia antibiótica empírica de amplio espectro y desbridamiento quirúrgico.

© 2016 Elsevier España, S.L.U. y Sociedad Española de Reumatología y Colegio Mexicano de Reumatología. Todos los derechos reservados.

## Background

Necrotizing fasciitis (NF) is a rare severe infection affecting subcutaneous tissue and superficial fascia associated with considerable mortality (70–80%).<sup>1–3</sup> The infections are the most feared adverse events of tocilizumab (TOC); there are few published post-marketing data.

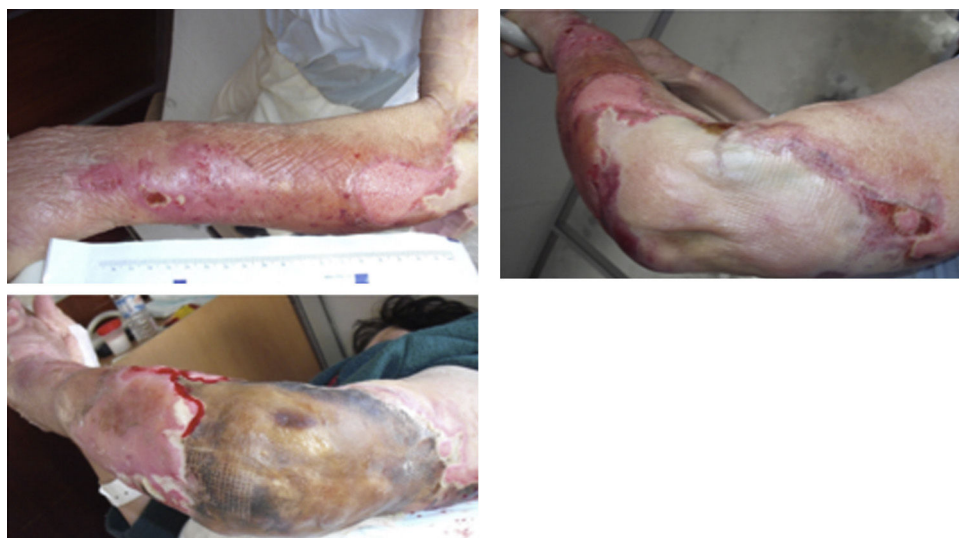A case report of NF is presented with a published cases review through PubMed database and several European Biologics Registers.

## Case report

A 66-year-old Caucasian woman with a seropositive RA presented with sudden onset of severe and progressive forearm and elbow pain with 3 days of evolution. She denied fever and history of trauma or animal bite. Since fourteen years ago, she has been consecutively treated with methotrexate (up to 20 mg/week), etanercept (50 mg weekly) and adalimumab (40 mg fortnightly), which were discontinued owing to lack of efficacy. For three years, she has been treated with prednisolone (7.5 mg/day), leflunomide (LEF) (10 mg/day) and TOC (8 mg/kg intravenous (iv) every 4 weeks). The prior medical history was significant for bacterial osteomyelitis (foot fifth digit) under TOC monotherapy for a year. Vital signs were as follow: pulse, 86beats/min; blood pressure, 135/72 mmHg; body temperature, 36.8 °C. Had active synovitis in

\* Corresponding author.

E-mail address: di9.goncalves@hotmail.com (D. Rosa-Gonçalves).



**Figure 1.** Evolution of skin lesions at first five days of internment: áreas of extensive skin detachment in the context of ruptura of blisters and severe exudation and necrotic áreas.

metacarpophalangeal, interphalangeal and wrist joints. Left upper limb presented diffusely oedematous with a slight erythematous rash and increased temperature. Laboratory tests were as follow: hemoglobin 12.3 g/dl; white blood cell (WBC) count  $11.8 \times 10^9/l$

(neutrophils  $10.6 \times 10^9/l$ ); platelets  $149 \times 10^9/l$ ; C-reactive protein (CRP) 74.6 mg/L; creatinine 1.51 mg/dl; sodium 138 mEq/l and glucose 91 mg/dl. Arteriovenous Doppler ultrasound excluded venous thrombosis.

**Table 1**  
Characterization of reported cases of necrotizing fasciitis with tocilizumab and TNF $\alpha$  blockers.

Case (reference)	1 <sup>5</sup>	2 <sup>3</sup>	3 <sup>6</sup>	4 <sup>7</sup>	5 <sup>8</sup>	6 <sup>9</sup>
Biological	TCZ	TCZ	TCZ	Etanercept	Infliximab	Etanercept
Gender	F	F	M	M	M	F
Age (years)	59	65	53	39	54	37
RA duration (years)	3	15	?	2	12	21
TNF $\alpha$ blockers/TCZ therapy duration (months)	2	12	48	24	?	7
Current cDMARD	No	No	?	AZA	i.m MTX	No
Previous DMARD	MTX, HCQ, adalimumab, etanercept	MTX, SSZ, tracolimus, infliximab, etanercept	?	No	SSZ, AZA, cyclosporin, i.m. gold, MTX	Gold, HCQ, SSZ, MTX, AZA, LEFL
CCTs	No	?	?	No	?	Yes
DM	No	No	No	No	No	No
Previous infection under biologics	No	No	No	No	No	No
Area	Pectoral region Shoulder	Hand, Forearm	Leg	Shoulder	Thigh	Lower limb
Fever at presentation	No	No	No	Yes	No	No
WBC (/mm <sup>3</sup> )	Normal	5300	22,100	Normal	14,820	Normal
Neutrophils (/mm <sup>3</sup> )	?	4900	19,669	Raised	13,990	?
CRP (mg/dl)	Normal	0.04	25.3	Raised	?	?
Fasciitis in CT/MRI	Yes/not done	Not done/not done	Yes/not done	Yes/not done	Not done/not done	Not done/not done
Isolated agents in skin swabs/blood cultures	Group A Streptococcus (pyogenes)/None	Group A Streptococcus/none	Group A Streptococcus/none	No/No	Group A Streptococcus/Group A Streptococcus/DIC treatment	Group A Streptococcus/Group A Streptococcus/Clindamicina, vancomicina, levofloxacin, IVIGs
Treatment	Gentamicin, penicillin, clindamycin, (+IVIGs + hydrocortisone)	?	Penicillin G, meropenem	Cefotaxime, metronidazol, vancomycin, ciprofloxacin; clindamycin, ciprofloxacin, flucloxacillin, benzylpenicillin		
Surgical debridement/skin graft	Yes/no	Yes/no	Yes/yes	Yes/no	Yes/yes	Yes/no
Sepsis/death	Yes/yes	Yes/no	No/no	No/no	Yes (DIC)/yes	Yes/yes

AZA, azathioprine; cDMARD, classic disease-modifying antirheumatic drugs; CCT, corticotherapy; CRP, C-reactive protein; CT, computerized tomography; DIC, disseminated intravascular coagulation; DM, diabetes mellitus; F, female; HCQ, hydroxychloroquine; IVIG, intravenous immunoglobulin; LEFL, leflunomide; MRI, magnetic resonance imaging; M, male; MTX, methotrexate; RA, rheumatoid arthritis; SSZ, sulfasalazine; TCZ, tocilizumab; WBC, white blood cell; ?, unknown.

Three days later, erythrocyte sedimentation rate was 58 mm and CRP 188.3 mg/L. Differential diagnosis included cellulitis and septic arthritis. Immunosuppressants drugs were discontinued, cholestyramine and empiric antibiotic therapy (vancomycin and imipenem) were initiated. Magnetic resonance showed periponeurosis and muscle edema (especially deltoid muscle), signs of cellulitis, without organized collections. At day 5 of treatment, lesions rapidly progressed to extensive areas of skin detachment and necrosis with severe exudation (Fig. 1). She had now periodic fever. *Enterobacter aerogenes*, *Pseudomonas aeruginosa* and *Stenotrophomonas maltophilia* were identified in the skin; blood cultures were negative. Surgical debridement with subsequent partial skin graft and a twenty-days period of antibiotics led to progressive improvement. She was discharged at day 39.

After one-year follow-up there was no recurrence of infections. She is under hydroxychloroquine (400 mg/day) and prednisolone (7.5 mg/day). Methotrexate was added but soon discontinued due to oral mucositis. TOC was permanently withdrawn.

### Literature review and discussion

We identified three case reports of NF in RA patients receiving TOC<sup>3–5</sup> and three under TNF antagonists<sup>6–8</sup> (Table 1). Published rates of serious skin and soft tissue infections in RA patients vary widely between different European Biologics Registers, from 12–18 per 1000 patient-years in the British register to 37–76 per 1000 patient-years in German register.<sup>9</sup> Results from British register showed that the majority were cellulitis (227/309; 73%) and only four cases were NF (all with anti-TNF).<sup>10</sup>

A German cohort study concluded that longer disease duration, history of severe infections, previous exposure to multiple DMARDs and concomitant treatments with LEF, prednisone or proton-pump inhibitor increase the risk of infections under TOC. This is our patient profile. In the TOWARD study, infections were more prevalent among patients receiving TOC and DMARDs simultaneously; however, there was no explicitly assigned association to LEF.<sup>11</sup> Thus, we cannot overlook that our patient was under LEF and glucocorticoids and we should attribute the adverse event to their association with TOC rather than to TOC alone. TOC contribution remains speculative and causality can neither be asserted nor ruled out with certainty. So, we believe that is important to report such infections in the post-marketing surveillance.

In conclusion, physician should keep in mind that infections may mimic a disease flare and the absence of fever does not exclude serious infections in RA patients under biologics.

### Ethical disclosures

**Protection of human and animals subjects.** The authors state that no human or animal experiments have been performed for this investigation.

**Confidentiality of data.** The authors state that they have followed the protocols of their work center on the publication of patient data.

**Right to privacy and informed consent.** The authors declare that they have received written consent from the patients and/or subjects mentioned in the article. The author for correspondence must be in possession of this document.

### Conflict of interest

All authors declare no conflicts of interest.

### References

- Bannwarth B, Richez C. Clinical safety of tocilizumab in rheumatoid arthritis. *Expert Opin Drug Saf.* 2011;10:123–31.
- Campbell L, Chen C, Bhagat SS, Parker RA, Östör AJ. Risk of adverse events including serious infections in rheumatoid arthritis patients treated with tocilizumab: a systematic literature review and meta-analysis of randomized controlled trials. *Rheumatology (Oxford).* 2011;50:552–62.
- Yoshida A, Ota T, Sasaoka S, Matsuura H, Fujimoto W, Morita Y. Necrotizing fasciitis in a patient with rheumatoid arthritis treated with tocilizumab. *Mod Rheumatol.* 2012;22:317–8.
- van de Sande MG, van Slobbe-Bijlsma ER. Necrotizing fasciitis in a rheumatoid arthritis patient treated with tocilizumab. *Rheumatology.* 2012;51:577–8.
- Hashimoto N, Yamaoka T, Koguchi-Yoshioka H, Tanaka A, Tanemura A, Azukizawa H, et al. Development of necrotising fasciitis in a patient treated for rheumatoid arthritis with tocilizumab. *Acta Derm Venereol.* 2015;95:370–1.
- Smyth A, Houlihan DD, Tuite H, Fleming C, O’Gorman TA. Necrotising fasciitis of the shoulder in association with rheumatoid arthritis treated with etanercept: a case report. *Med Case Rep.* 2010;4:367.
- Chan AT, Cleeve V, Daymond TJ. Necrotising fasciitis in a patient receiving infliximab for rheumatoid arthritis. *Postgrad Med J.* 2002;78:47–8.
- Baghai M, Osmon DR, Wolk DM, Wold LE, Haidukewych GJ, Matteson EL. Fatal sepsis in a patient with rheumatoid arthritis treated with etanercept. *Mayo Clin Proc.* 2001;76:653–6.
- Hernández MV1, Sanmartí R, Cañete JD, Descalzo MA, Alsina M, Carmona L, et al. Cutaneous adverse events during treatment of chronic inflammatory rheumatic conditions with tumor necrosis factor antagonists: study using the Spanish registry of adverse events of biological therapies in rheumatic diseases. *Arthritis Care Res (Hoboken).* 2013;65:2024–31.
- Galloway JB, Mercer LK, Moseley A, Dixon WG, Ustianowski AP, Helbert M, et al. Risk of skin and soft tissue infections (including shingles) in patients exposed to anti-tumour necrosis factor therapy: results from the British Society for Rheumatology Biologics Register. *Ann Rheum Dis.* 2013;72:229–34.
- Lang VR, Englbrecht M, Rech J, Nüsslein H, Manger K, Schuch F, et al. Risk of infections in rheumatoid arthritis patients treated with tocilizumab. *Rheumatology (Oxford).* 2012;51:852–7.