




Sociedad Española
de Reumatología -
Colegio Mexicano
de Reumatología

Reumatología Clínica

www.reumatologiaclinica.org



Case report

Myositis as the Initial Presentation of Panarteritis Nodosa[☆]

Romina Calvo, Melina Negri, Alberto Ortiz, Susana Roverano, Sergio Paira*

Servicio de Reumatología, Hospital J.M. Cullen, Santa Fe, Argentina



ARTICLE INFO

Article history:

Received 15 May 2017

Accepted 16 June 2017

Available online 24 October 2018

Keywords:

Vasculitis

Myositis

Polyarteritis nodosa

ABSTRACT

A 47-year-old man presented with weight loss, bilateral calf pain, fever, hypertension, orchitis and oligoarthritis. Lab tests: anemia and elevated muscle enzymes. Resonance magnetic imaging: hyperintensity in gastrocnemius muscles (myositis). Histologic exam of the muscles: inflammatory infiltrate with atrophy and perifascicular regeneration. Treatment: methylprednisone (bolus) and cyclophosphamide. Muscle pain and swelling and difficulty in walking are common in panarteritis nodosa (PAN), whereas histologically demonstrated myositis is not. Even more rare is myositis as the initial presentation of this vasculitis.

© 2017 Elsevier España, S.L.U. and Sociedad Española de Reumatología y Colegio Mexicano de Reumatología. All rights reserved.

Miositis como forma de presentación de panarteritis nodosa

RESUMEN

Varón de 47 años que consulta por pérdida de peso, dolor con tumefacción en pantorrillas, fiebre, hipertensión arterial, orquitis y oligoartritis. Laboratorio: anemia y aumento de enzimas musculares. Resonancia magnética: hiperintensidad en gemelos (miositis). Histología de músculo: infiltrado inflamatorio con atrofia y regeneración perifascicular. Tratamiento: pulsos de metilprednisolona y ciclofosfamida. Mialgias, tumefacción muscular y deambulación dificultosa son hallazgos comunes en poliarteritis nodosa (PAN), no así la miositis demostrada histológicamente y más infrecuente aún como forma de inicio de esta vasculitis.

© 2017 Elsevier España, S.L.U. y Sociedad Española de Reumatología y Colegio Mexicano de Reumatología. Todos los derechos reservados.

Palabras clave:

Vasculitis

Miositis

Poliarteritis nodosa

Introduction

Polyarteritis nodosa (PAN) is a necrosing arthritis of the small and medium-sized arteries, with no glomerulonephritis and not associated with ANCA.¹ The organs most affected are the skin, gastrointestinal tract, kidney, peripheral nerves, heart, liver, pancreas, testicles, the nervous system and the muscles.²

Muscular manifestations are common (51%), consisting of muscular swelling, gait difficulty and myalgia, which might be due to compromised intramuscular arteries, neuropathy due to involvement of the peripheral nervous system or, more rarely, to myositis.^{3–8}

We describe a case of PAN presenting with calf pain due to myositis as a form of onset of this vasculitis.

Clinical Observation

A 47-year-old male consulted with a one-month history of weight loss (10 kg) and spontaneous, incapacitating calf pain. Physical examination: fever (38.5 °C) predominantly in the evening, tachycardia, blood pressure 160/100 mmHg, erythematous lumps in the twin muscles (approximately 6 × 10 cm), of hard-elastic consistency and warm, and thermalgesic sensitivity was preserved (Fig. 1). Erythematous purpuric macules were also observed on the anterior and posterior surfaces of the legs, testicular pain on palpation, and arthritis in carpi, metacarpophalangeal and proximal interphalangeal joints.

Laboratory tests: anaemia with haemoglobin: 10 g/dl (11.9–15 g/dl), white cells 25,160 k/μl (4500–10,000), platelets 634,000 k/μl (150,000–400,000), GTO: 144 U/l (up to 38), TGP:

[☆] Please cite this article as: Calvo R, Negri M, Ortiz A, Roverano S, Paira S. Miositis como forma de presentación de panarteritis nodosa. Reumatol Clin. 2019;15:e24–e26.

* Corresponding author.

E-mail address: pairasergio@hotmail.com (S. Paira).

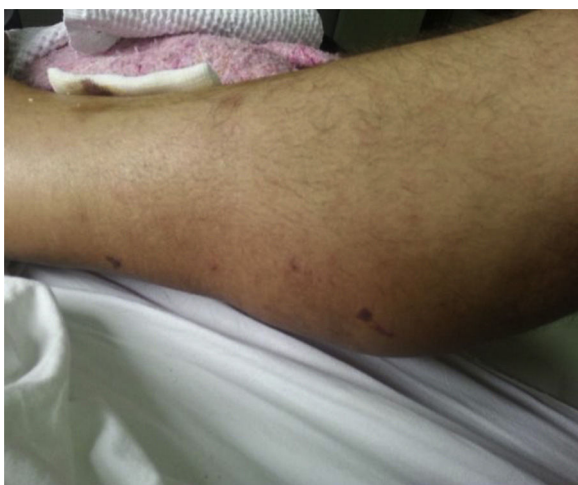

Fig. 1. Calf swelling.

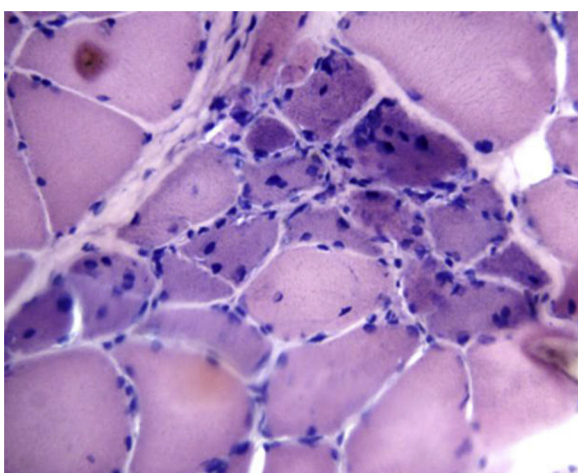


Fig. 2. Muscle biopsy: inflammatory infiltration, with atrophy and perifascicular regeneration.

192 U/l (up to 46), alkaline phosphatase 448 U/l (35–105), direct bilirubin .31 mg/dl (up to .20), CPK 1232 IU/l (<135), LDH 233 (<460), aldolase 10 U/l (<3), ESR 119 mm/1 h (up to 20), CRP 317 mg/l (0–5). Renal function and serologies for hepatitis B and C; HIV, ANF (HeP-2), nDNA (*Crithidia*), ENA, p-ANCA and c-ANCA and complements: negative or normal. MRI showed hyperintensity in the twin muscles compatible with myositis, while electromyography of the upper and lower limbs showed a motor-sensitive polyneuropathy with decreased sural nerve conduction speed. Inflammatory infiltration, atrophy and focal perifascicular regeneration was found on muscle biopsies (Fig. 2). Biopsy of the sural nerve showed moderate myelinated fibre depletion and signs of axonal degeneration along with extensive lymphocytic infiltration around the small epineurial vessels and the wall of the median artery.

The skin biopsy showed acute and chronic inflammatory infiltration of septal distribution and medium-sized vessels with vasculitic phenomena and fibrinoid necrosis of the septal wall with erythrocyte extravasation in the hypodermis. Aortography and total bone scan were normal.

With a diagnosis of PAN (Chapell Hill and ACR criteria: weight loss of more than 4 kg, testicular pain, myalgia, polyneuritis demonstrated by electromyography, diastolic blood pressure higher than 90 mmHg and medium-sized artery biopsy compatible with vasculitis) 3 pulses of intravenous methylprednisolone 1 g/day

were given, continuing with 60 mg/day of oral meprednisone and monthly intravenous cyclophosphamide. The patient made good progress.

Discussion

PAN is a vasculitis that predominantly affects the small and medium-sized arteries. It affects the skin (20%), gastrointestinal tract (50%), kidneys (40%–60%) and peripheral nerves (60%). Muscle compromise is not a feature of this disease. Although myalgia, swelling and impossibility of walking can present in 51% of patients,⁸ myositis is found in 19% of these diseases,³ and there are only 14 cases reporting this compromise as a form of onset of this vasculitis.^{2,6,7}

The muscle enzymes are elevated in only 5% of cases, as occurred in the case we describe. The CPK enzymes (5%–25%) are the most altered, and elevated LDH and aldolase have been reported in some cases.

These cases must be differentiated from polymyositis and myositis of other origins, and therefore diagnosis relies on anatomical pathology. It is appropriate to choose the biopsy site by MRI, which shows increased signal intensity on the T2 and STIR sequences, indicating inflammatory changes.^{4–7} Almost all the patients reported underwent a muscular biopsy, compatible with vasculitis.^{3,9,10}

This is the first described case with myositis demonstrated by histology. These histological signs might have gone unnoticed in previous cases.

Conclusion

Perhaps we ought to broaden the spectrum when analysing muscle biopsies for PAN and look for signs of vasculitis as well as myositis.

Ethical Disclosures

Protection of people and animals. The authors declare that no experiments were performed on humans or animals for this study.

Confidentiality of data. The authors declare that no patient data appear in this article.

Right to privacy and informed consent. The authors declare that no patient data appear in this article.

Conflict of Interest

The authors have no conflict of interest to declare.

References

- Jennette JC, Falk RJ, Bacon PA, Basu N, Cid MC, Ferrario F, et al. 2012 Revised International Chapel Hill Consensus Conference Nomenclature of Vasculitides. *Arthritis Rheum.* 2013;65:1–11.
- Plumley SG, Rubio R, Alasfar S, Jasim HE. Polyarteritis nodosa presenting as polymyositis. *Semin Arth Rheum.* 2002;31:377–83.
- Fort JG, Griffin R, Tahmouh A, Abruzzo JL. Muscle involvement in polyarteritis nodosa: report of a patient presenting clinically as polymyositis and review of the literature. *J Rheumatol.* 1994;21:945–8.
- Haroon M, Birmingham N, Keohane C, Harney S. Polyarteritis nodosa presenting with clinical and radiologic features suggestive of polymyositis. *Rheumatol Int.* 2012;32:1079–81.
- Benz N, Daikeler T, Frank S, Mehling M, Tyndall A, Trendelenburg M. Three cases of primary small vessel vasculitis of the skeletal muscle – an own entity. *BMJ Case Rep.* 2011;2011. <http://dx.doi.org/10.1136/bcr.08.2011.4631>, pii:bcr0820114631.
- Ahmed S, Kitchen J, Hamilton S, Brett F, Kane D. A case of polyarteritis nodosa limited to the right calf muscles, fascia and skin: a case report. *J Med Case Rep.* 2011;5:540.

7. Balbir-Gurman A, Nahir AM, Braun- Moscovici Y. Intravenous immunoglobulins in polyarteritis nodosa restricted to the limbs: case report and review of the literature. *Clin Exp Rheum.* 2007;25:28–30.
8. Lupoli S, Gargiulo A, Rossi R, Ames PR. Myositis as a presenting feature of polyarteritis nodosa. *Clin Exp Rheumatol.* 2004;22:507–8.
9. Nakamura T, Tomoda K, Yamamura Y, Tsukano M, Honda I, Iyama K. Polyarteritis nodosa limited to calf muscles: a case report and review of the literature. *Clin Rheumatol.* 2003;22:149–53.
10. Sümer M, Oksüzoglu B, Sungur C, Gungen Y. Muscle involvement in polyarteritis nodosa: report of a case presenting clinically as myopathy. *Clin Exp Rheum.* 2002;20:434.