



Sociedad Española
de Reumatología -
Colegio Mexicano
de Reumatología

Reumatología Clínica

www.reumatologiaclinica.org



Images in Clinical Rheumatology

Diffuse Large B-cell Lymphoma of the Lung in a Patient With Nonspecific Interstitial Pneumonia[☆]

Linfoma difuso de células B grandes pulmonar en paciente con neumonía intersticial no específica

Luis Gorospe Sarasúa,^{a,*} Paola Arrieta,^b Anabelle China-Rodríguez,^c Carlos de la Puente-Bujidos^d

^a Servicio de Radiodiagnóstico, Hospital Universitario Ramón y Cajal, Madrid, Spain

^b Servicio de Neumología, Hospital Universitario Ramón y Cajal, Madrid, Spain

^c Servicio de Hematología, Hospital Universitario Ramón y Cajal, Madrid, Spain

^d Servicio de Reumatología, Hospital Universitario Ramón y Cajal, Madrid, Spain

ARTICLE INFO

Article history:

Received 17 June 2017

Accepted 13 July 2017

Available online 29 November 2018

We present the case of a 66 year-old patient who presented at surgery with dyspnoea. A chest X-ray revealed multiple opacities in the right lung (Fig. 1A). Of note in the patient's medical history was high blood pressure, type 1 diabetes mellitus (both controlled), and nonspecific interstitial pneumonia (NSIP) which had been confirmed several years previously by means of a biopsy. Computerised tomography (CT) of the chest confirmed the presence of multiple right lung masses (Fig. 1B), with aerial bronchogram, with no pleural or lymph node effusion, and with interstitial involvement (Fig. 1C). Trans-bronchial biopsy confirmed high grade diffuse large B-cell non-Hodgkin lymphoma (DLBCL). Positron emission tomography/CT (PET/CT) ruled out other tumours. The patient was treated with chemotherapy (R-CHOP regimen), with complete response after 6 cycles.

Lung DLBCL is a rare subtype of primary lung lymphoma (PLL) which may be associated with states of immunosuppression (infection by human immunodeficiency virus, common variable immunodeficiency), a tobacco habit and autoimmune diseases.¹ Of the latter, Sjögren's syndrome and rheumatoid arthritis are the most common. Our case is interesting since none of the described associations presented, but NSIP did. NSIP may be idiopathic or secondary (among other causes) to autoimmune diseases. In order of frequency the following are of note: systemic sclerosis, polymyositis/dermatomyositis and mixed connective tissue disease. Interstitial lung diseases which may be complicated with cancer are the usual interstitial pneumonitis² (bronchogenic carcinoma) and lymphoid interstitial pneumonitis³ (PLL, particularly in patients with Sjögren syndrome), but no descriptions of lung DLBCL associated with an NSIP have been found.

[☆] Please cite this article as: Gorospe Sarasúa L, Arrieta P, China-Rodríguez A, de la Puente-Bujidos C. Linfoma difuso de células B grandes pulmonar en paciente con neumonía intersticial no específica. Reumatol Clin. 2019;15:e151–e152.

* Corresponding author.

E-mail address: luisgorospe@yahoo.com (L. Gorospe Sarasúa).

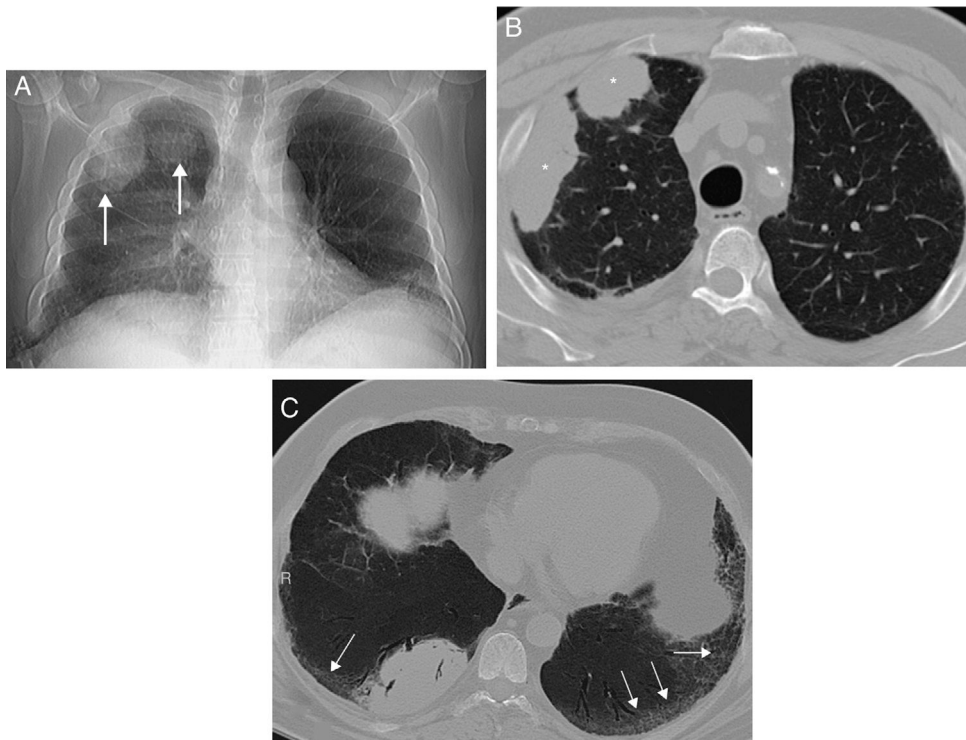


Fig. 1. (A) Posteroanterior X-ray of the chest in which several nodular opacities are observed in the right lung (arrow). Note the presence of a subtle bibasal enlargement of the lung interstitium. (B) Axial image of chest CT which confirms the presence of right lung masses (asterisks). (C) Axial image of chest CT (minimum intensity projection) in which a bibasal lung interstitium reticulation (arrows) may be observed in relation to the patient's interstitial lung disease. Note the presence of small traction bronchiectasis.

Ethical Disclosures

Protection of human and animal subjects. The authors declare that for this research no experimentation has been carried out on human beings or animals.

Confidentiality of data. The authors declare that no patient data appear in this article.

Right to privacy and informed consent. The authors declare that no patient data appear in this article.

Conflict of Interests

The authors have no conflicts of interests to declare.

References

1. Piña-Oviedo S, Weissferdt A, Kalhor N, Moran CA. Primary pulmonary lymphomas. *Adv Anat Pathol.* 2015;22:355–75.
2. Song DH, Choi IH, Ha SY, Han KM, Lee JJ, Hong ME, et al. Usual interstitial pneumonia with lung cancer: clinicopathological analysis of 43 cases. *Korean J Pathol.* 2014;48:10–6.
3. Kokosi M, Riemer EC, Highland KB. Pulmonary involvement in Sjögren syndrome. *Clin Chest Med.* 2010;31:489–500.