

**Facial erysipelas after secukinumab therapy<sup>☆</sup>****Erisipela facial tras tratamiento con secukinumab**

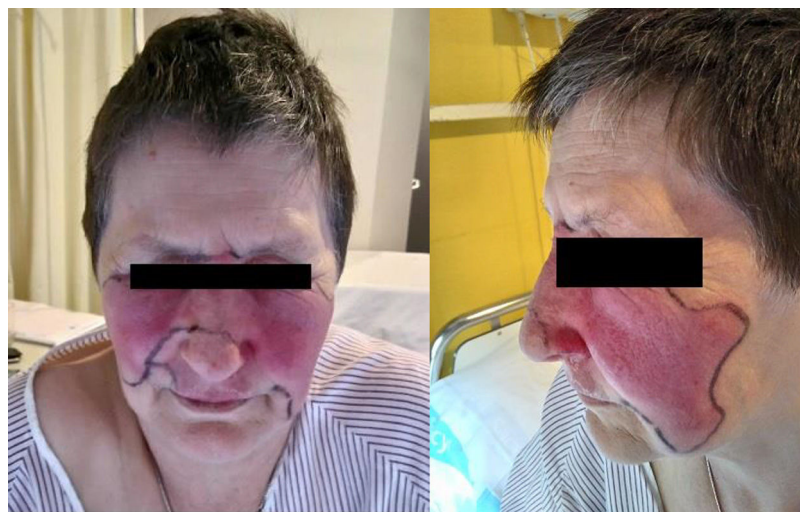Dear Editor,

Erysipelas is an acute infection of the epidermis and superficial dermis that generally affects the elderly or immunocompromised people.<sup>1</sup> The use of biological therapies implies an increased risk of infection, often skin infections,<sup>2,3</sup> and therefore it is essential to start antibiotic therapy when suggestive signs appear. We present the case of a woman with psoriatic arthritis who developed facial erysipelas following treatment with secukinumab, which to date has not been described with this monoclonal anti-IL17A antibody.

A 61-year-old woman with a history of hiatus hernia and smoker of 30 packs/year until 10 years earlier, diagnosed with peripheral psoriatic arthritis in January 2008, continued treatment with methotrexate from diagnosis to cessation due to dyspepsia (2016), adalimumab (2009–2010) and etanercept (2010–2017), both discontinued due to secondary inefficiency. In February 2017 she started treatment with subcutaneous secukinumab 300 mg/month in monotherapy combined with naproxen 500 mg/12 h and lansoprazol. After 10 months of treatment with secukinumab, 24 h after the injection, an erythematous lesion appeared in the left nasogenian sulcus spreading to both cheeks, eyes and dorsum of the nose, with no feeling of dysthermia. She received oral erythromycin for 48 h with no improvement. On admission she was in a good general condition, blood pressure 200/98, temperature 37.4 °C, and systemic examination was normal. Erythematous lesions on the dorsum of the nose, both malar and periorbital regions, with a well-defined border, were observed, with some blisters on the left side and on the upper lip (Fig. 1). Of note in the blood tests were leukocytes 11.3 cell/ $\mu$ l (neutrophils 8.6 cell/ $\mu$ l), normal biochemistry, ESR 70 mm/h, CRP 3.9 mg/dl and procalcitonin <.12 ng/ml (normal: 0–.5). Blood cultures were negative. Empirical treatment with intravenous antibiotic therapy with vancomycin and ceftriaxone was initiated, and due to good clinical progress over 48 h

replaced by amoxicillin-clavulanic acid for 10 days, with resolution of symptoms. To date, the patient, whose articular disease is stable, did not want to restart biological therapy, and methotrexate has been reintroduced.

Erysipelas is an acute superficial cellulitis characterised by the onset of a small erythematous lesion that rapidly spreads and causes inflammation and redness of the dermis with well-defined edges, located in the legs (68%–90%) or face (2.5%–9%).<sup>4,5</sup> The infection may progress to bulla formation and necrosis. In up to 40% of cases patients have a systemic disease, and in 78% there is a predisposing factor, among which age and immunosuppression stand out; although there is usually fever and general malaise, 15% are afebrile. *Streptococcus* is the most frequent aetiological agent, principally group A *beta*-haemolytic *Streptococcus*, and *Staphylococcus aureus* is found in 10%–17%, especially in immunosuppressed patients in whom other types of bacteria can be isolated.<sup>4</sup> Diagnosis is clinical, blood cultures are of poor yield, being positive in 5%, and the causative agent can only be isolated by culture of the skin lesions.<sup>5</sup> The treatment of choice is penicillin or macrolides in cases of allergy to beta-lactams, although oral or intravenous administration or courses of 5 or 10 days appear to be equally effective in curing and preventing relapses.<sup>6</sup> Recurrence is common and up to 29% of subjects have a further episode in the following 3 years, which seems to be more frequent for group C and G *Streptococcus*.<sup>5,6</sup> Treatment with biological therapy involves an increased risk of infection, often in the skin. Recently a case of a woman presenting with erysipelas in the leg following treatment with tocilizumab has been described,<sup>7</sup> but in the literature reviewed no cases of erysipelas associated with secukinumab have been described, although in the study by Baeten et al. on ankylosing spondylitis, one of the patients had a subcutaneous abscess of the foot due to *S. aureus*.<sup>8</sup> Erysipelas is an infectious complication that is easily recognisable and treatable, with a good prognosis provided antibiotic therapy is initiated early. The relative frequency of recurrences in a third of subjects must be taken into account due to the greater susceptibility of our patients, especially if they continue with biological therapy.



**Fig. 1.** Erythematous lesions with well-defined border on the nose, malar, periorbital regions and on the upper lip. The limits of the lesions were drawn to better observe how they evolved.

<sup>☆</sup> Please cite this article as: Pantoja Zarza L, Díez Morrondo C. Erisipela facial tras tratamiento con secukinumab. *Reumatol Clin.* 2020;16:431–32.

## References

- Celestin R, Brown J, Kihiczak G, Sxhwartz RA. Erysipelas: a common potentially dangerous infection. *Acta Dermatovenerol Alp Pannonica Adriat.* 2007;16:123–7.
- Pérez-Sola MJ, Torre-Cisneros J, Pérez-Zafrilla B, Carmona L, Descalzo MA, Gómez-Reino JJ, et al. Infections in patients treated with tumor necrosis factor antagonists: Incidence, etiology and mortality in the BIOBADASER registry. *Med Clin (Barc).* 2011;137:533–40.
- Wallis D. Infection risk and biologics: current update. *Current Opin Rheumatol.* 2014;26:404–9.
- Bonnetblanc JM, Bédane C. Erysipelas, recognition and management. *Am J Clin Dermatol.* 2003;4:157–63.
- Bläckberg A, Trell K, Rasmussen M. Erysipelas, a large retrospective study of aetiology and clinical presentation. *BMC Infect Dis.* 2015;15:402–7.
- Morris AD. Cellulitis and erysipelas. *BMJ Clin Evid.* 2008;2008:1708–15. Available from: <https://www.ncbi.nlm.nih.gov/pmc/articles/PMC2907977/> [accessed 18.04.18].
- Yéléhé-Okouma M, Henry J, Petitpain N, Schmutz JL, Gillet P. Érysipéle sans fièvre ni syndrome inflammatoire lors d'un traitement par tocilizumab. *Ann Dermatol Venerol.* 2017;144:434–7.
- Baeten D, Baraliakos X, Braun J, Sieper J, Emery P, van der Heijde D, et al. Anti-interleukin-17A monoclonal antibody secukinumab in treatment of ankylosing spondylitis: a randomised, double-blind, placebo-controlled trial. *Lancet.* 2013;382:1705–13.

Lucía Pantoja Zarza,\* Carolina Díez Morrondo

Unidad de Reumatología, Hospital del Bierzo, Ponferrada, León, Spain

\* Corresponding author.

E-mail address: [lpantojazarza@gmail.com](mailto:lpantojazarza@gmail.com) (L. Pantoja Zarza).

2173-5743/ © 2018 Elsevier España, S.L.U. and Sociedad Española de Reumatología y Colegio Mexicano de Reumatología. All rights reserved.

### Migratory arthralgia as the initial sign of systemic toxicity associated with chronic nitrofurantoin treatment\*



#### Artralgias migratorias: manifestación inicial de toxicidad sistémica asociada al tratamiento crónico con nitrofurantoína

Dear Editor,

Nitrofurantoin is an antibiotic widely used in the treatment and prevention of urinary tract infections (UTI). The most common adverse effects are gastrointestinal but cases of pulmonary and hepatic<sup>1</sup> toxicity, and even vasculitis<sup>2</sup> have been reported.

We present the case of a 63-year-old woman with a history of repetitive UTI, with no other relevant medical history. Prophylaxis with nitrofurantoin had been initiated a year prior to the presentation of symptoms. She was referred to the rheumatology department for migratory asymmetrical arthralgias of 4-month onset. During examination she referred to dyspnoea with moderate effort which had appeared after the arthralgias. Auscultation revealed bilateral crackling sounds. A chest X-ray showed a bilateral interstitial pattern and high resolution computerised tomography (HRCT) showed ground glass areas corresponding to acute/sub acute interstitial pneumonia (Fig. 1). Blood tests highlighted GOT 360 U/l, GPT 432 U/l and GGT 279 U/l with normal abdominal ultrasound. The hepatopos virus serology and autoimmune antibody study tested negative. Autoimmunity studies detected ANCA+ 1/640 perinuclear staining (negative anti-myeloperoxidase and anti-proteinase 3). Due to these findings toxicity by nitrofurantoin was suspected and the drug was withdrawn. Treatment with prednisone was established, with a good response at respiratory level, a drop in hepatic enzymes and a complete resolution of arthralgias. During follow-up, the transaminase values remained normal, respiratory symptoms disappeared and posterior lung imaging tests were normal. The arthralgias abated and the ANCAs tested negative.

There have been case reports of concomitant pulmonary and hepatic toxicity attributed to the use of nitrofurantoin.<sup>3</sup> Pulmonary toxicity and hepatic toxicity have 2 types of presentations: acute and chronic. Chronic pulmonary toxicity symptoms develop after

several months of treatment. The most common are dyspnoea, irritative cough and fatigue. Crackling sounds, especially around the lung bases<sup>4</sup> are usually the result of auscultation. All types of radiographic anomalies in most patients exist, mostly in inferior and bilateral fields. In the HRCT scan ground glass areas may be observed, together with septal enlargement and traction bronchiectasias.<sup>5</sup>

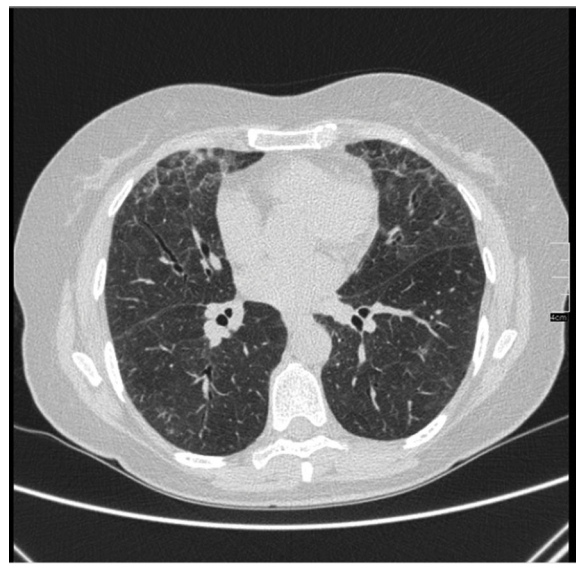


Fig. 1. High resolution computerized tomography. Axial slice at lung base level. Ground glass pattern is observed which corresponds to acute/sub acute pneumonia. There are no areas of fibrosis or any distortion of the lung architecture.

The acute form of hepatic toxicity generally presents after only a few weeks of treatment and is uncommon. It is usually accompanied by fever and rash.<sup>6</sup> Normally withdrawing the medication resolves this, although cases of fulminant hepatitis<sup>3</sup> have been known to exist. The more common chronic disorder may present months or years later. Symptoms are usually fatigue, muscle weakness and jaundice and an increase of transaminases in lab tests. Autoimmunity markers are occasionally detected (ANA+, anti-ML antibodies and elevated IgG).<sup>1</sup> Recovery after the removal of the drug is usually slow and hepatic damage may persist.<sup>6</sup>

\* Please cite this article as: Arévalo Ruales K, Ivorra Cortés J, Román Ivorra J, Martínez Francés M. Artralgias migratorias: manifestación inicial de toxicidad sistémica asociada al tratamiento crónico con nitrofurantoína. *Reumatol Clin.* 2020;16:432–33.