

Francisca Aguiar^{a,b,*}, Iva Brito^{a,b}, Jean Sibilía^{c,d}^a Department, of Rheumatology, Centro Hospitalar São João, Porto, Portugal^b Faculty of Medicine of Porto University, Porto, Portugal^c Department of Rheumatology, University Hospital of Strasbourg, France^d Centre National de Référence “Maladies auto-immunes systémiques rares”, France

* Corresponding author.

E-mail address: francisca.ra@hotmail.com (F. Aguiar).

<https://doi.org/10.1016/j.reuma.2019.01.001>**Valvulopathy in scleroderma is not always autoimmunity[☆]****Valvulopatía en la esclerodermia, no siempre es autoinmunidad**

Dear Editor,

Cardiac complications in scleroderma (SD) are associated with a poor prognosis. Up to 15% of patients, generally with limited forms and anticentromere antibodies, develop pulmonary hypertension (PHT). Early diagnosis improves the prognosis, so that routine transthoracic echocardiograms (TTE) are recommended.¹ Pericardial bleeding has also been described, as have valvulopathies, myocarditis and hypertrophy or myocardial fibrosis.^{2,3} We believe it is of interest to present the case of a patient with limited SD who developed mitral-aortic valvulopathy that was finally attributed to ergotamine toxicity.

A 59 year-old woman diagnosed SD based on Reynaud's phenomenon, characteristic capillaroscopy and anticentromere antibodies. At the moment of diagnosis TTE showed insignificant aortic and mitral insufficiency, normal systolic function and the absence of PHT data. 11 years later the valvulopathy had evolved to become severe mitral and tricuspid insufficiency, moderate aortic insufficiency and severe PHT (PSAP: 75 mmHg). Two mechanical prostheses were therefore implanted at mitral and aortic levels.

Two years later she visited due to general syndrome and dyspnoea. She was treated with Furosemide, Ranolazine, Acenocumarol, Spironolactone, Omeprazol and Bromazepam.

Physical examination only found distal metacarpophalangeal sclerodactyla, with no scarring, ulcers or telangiectasias, and mild cutaneous sclerosis on the legs.

Relevant analytical data are shown in Table 1.

A thoracic-abdominal CT scan showed an extensive area of retroperitoneal (RPF) and pelvic fibrosis with bilateral ureterohydronephrosis. Subsequently a PET-CT scan with ¹⁸F-FDG (Fig. 1) confirmed the mass of soft tissues in front of the sacrococcygeal region, with low glucidic avidity (SUVmax: 2.16 g/ml).

Table 1
Analytical results.

Biochemistry		Haemogram		Immunology	
Creatinine	1.23 mg/dl	Haemoglobin	12.5 g/dl	ANA	Positive 1/1,280, centromere
AST	44 UI/l	Leukocytes	7,620	Anti-DNA, ENA, ANCA	Negative
AP	716 UI/l	Platelets	13,700	Anticardiolipin antibodies, anti-2-glycoprotein antibodies	Negative
GGT	290 UI/l	PCR	46 m/h	IgG4	Normal (0.05)
PCR	2.54 mg/dl	–	–	Plasmablasts in peripheral blood	Negative

ANA: antinuclear antibodies; ANCA: antineutrophil cytoplasm antibodies; Anti-DNA: anti-DNA antibodies; AST: aspartate aminotransferase; ENA: extractable nuclear antigens; AP: alkaline phosphatase; GGT: gamma glutamyl transpeptidase; PCR: polymerase chain reaction.

[☆] Please cite this article as: Suárez Pérez L, Caminal Montero L, Trapiella Martínez L, Rugeles Niño J. Valvulopatía en la esclerodermia, no siempre es autoinmunidad. Reumatol Clin. 2021;17:56–57.

Given these findings a double J catheter was implanted and the fibrotic retroperitoneal lesions were biopsied. In the valves resected 2 years previously and in the retroperitoneal lesions only areas of fibrosis with negative immunofluorescence for IgG4 were observed.

The patient then remembered taking Hemicraneal® (paracetamol, caffeine and 2 mg ergotamine tartrate) almost every day for several years in suppository format for headaches, without medical prescription.

It was finally assumed that the RPF as well as the valvulopathy were side effects of the ergotamines.

RPF is a fibroinflammatory disease that is now considered to be within the spectrum of diseases associated with IgG4, although it has also been associated with other systemic diseases.⁴ Differential diagnosis of this disease includes carcinoid tumours, actinomycosis, radiotherapy or abdominal surgery and Erdheim-Chester's disease, although drugs also have to be considered. They include anti-migraine medication (metisergide and ergotamine), dopaminergic agonists used in Parkinson's disease (pergolide and cabergoline), anorexigenic drugs (fenfluramine, dexfenfluramine and benfluorex) and anti-TNF⁵ drugs. However, the list includes recreational drugs as well, such as 3,4-methylenedioxymethamphetamine, known as ecstasy.⁶ These drugs have strong affinity for the 5HT_{2A} serotonin receptor that is found in valvular tissue, and they cause lesions similar to those observed in carcinoid tumours, with thickening and accumulation of collagen and the proliferation of myofibroblasts and smooth muscle cells.

Ergotamine is used as migraine prophylaxis. It is sold over the counter and its use is contraindicated in Raynaud as it causes vasospasm. The first case of valvulopathy due to ergotamines was described in 1974⁵ and, although its toxicity is well-known, it is rarely diagnosed. It is probably under-diagnosed as it is taken without supervision, and its toxicity appears after prolonged use.^{6,7}

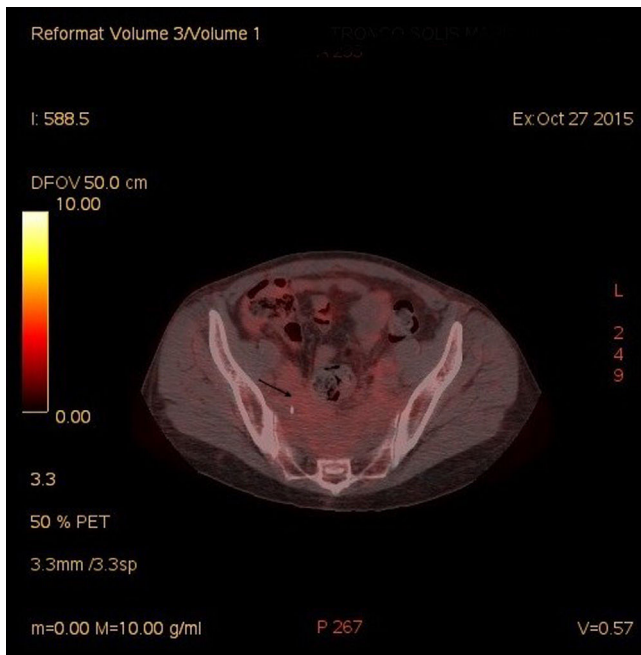


Fig. 1. PET-CT scan image with 18F-FDG showing presacral capture with little glucidic avidity.

Our patient, with limited SD, developed valvulopathy and RPF due to ergotamines. Although both toxicities are well-known, they are exceptional in the same patient. On the other hand, the association of SD and RPF, profibrotic diseases that may have similar physiopathological mechanisms, is exceptional.^{8,9} In spite of sophisticated current diagnostic procedures, our diagnosis is still based on directed anamnesis, which is often overlooked. In SD, as is the case for other systemic diseases,¹⁰ other processes and drugs which may simulate their clinical manifestations must always be taken into account.

Financing

This research received no specific grant from any agency in the public or private sector or those which are not-for-profit.

References

1. Denton CP, Khanna D. Systemic sclerosis. *Lancet*. 2017;390:1685–99.
2. Bissell LA, Anderson M, Burgess M, Chakravarty K, Coghlan G, Dumitru RB, et al. Consensus best practice pathway of the UK Systemic Sclerosis Study group: management of cardiac disease in systemic sclerosis. *Rheumatology (Oxford)*. 2017;56:912–21.
3. Plasín M, Luch E, Piulats R, Trullàs JC, Espinosa G. Acute cardiomyopathy as a clinical manifestation of systemic sclerosis [Article in Spanish]. *Rev Clin Esp*. 2011;211:e51–53.
4. Vaglio A, Maritati F. Idiopathic retroperitoneal fibrosis. *J Am Soc Nephrol*. 2016;27:1880–9.
5. Andrejak M, Tribouilloy C. Drug-induced valvular heart disease: an update. *Arch Cardiovasc Dis*. 2013;106:333–9.
6. Bhattacharyya S, Schapira AH, Mikhailidis DP, Davar J. Drug-induced fibrotic valvular heart disease. *Lancet*. 2009;374:577–85.
7. Martínez Quintana E, Llorens León R, Redondo Martínez E, Nieto Lago V, Jiménez Cabrera F, Gross Kastanovitz E. Valvular heart disease associated with ergotamine. *Rev Esp Cardiol*. 2005;58:97–9.
8. Cochat P, Colon S, Laville M, Maillet P, Lefrançois N, Moskovtchenko JF, et al. Retroperitoneal fibrosis and generalized scleroderma [Article in French]. *Nephrologie*. 1985;6:27–30.
9. Gerth HU, Willeke P, Sunderkötter C, Spieker T, Köhler M, Pavenstädt H, et al. Systemic sclerosis and collagenous colitis in a patient with retroperitoneal fibrosis. *Scand J Rheumatol*. 2011;40:322–3.
10. López-Mato P, Zamora-Martínez C, Carbajal S, Estevez M, Rodríguez-Pinto I, Cervera R, et al. All that glitters is not lupus. *Lupus*. 2017;961203317742713. <http://dx.doi.org/10.1177/0961203317742713>.

Lucía Suárez Pérez^a, Luis Caminal Montero^a,
Luis Trapiella Martínez^b, Jessica Rugeles Niño^a

^a Unidad de Enfermedades Autoinmunes Sistémicas, Unidad de Gestión Clínica de Medicina Interna, Hospital Universitario Central de Asturias, Oviedo, Asturias, Spain

^b Servicio de Medicina Interna, Hospital Universitario San Agustín, Avilés, Asturias, Spain

* Corresponding author.

E-mail address: luciasuarezp27@gmail.com (L. Suárez Pérez).

2173-5743/ © 2020 Published by Elsevier España, S.L.U.

Extension of the RENACER Study: 12-Month Efficacy, Safety and Certolizumab PEGol Survival in 501 Rheumatoid Arthritis Patients



Ampliación del estudio RENACER: eficacia, seguridad y supervivencia a 12 meses de 501 pacientes de artritis reumatoide tratados con Certolizumab PEGol

Dear Editor:

Regarding with our previous RENACER (Registro NAcional Certolizumab) Study,¹ we would like to present data in a larger population of Rheumatoid Arthritis (RA) patients on the use of Certolizumab-PEGol (CZP). CZP is a biological agent approved for RA which inhibits Tumor Necrosis Factor-alpha (TNFi). Its unique molecular structure allows its use in particular situations.^{2,3} Our study collected data in clinical practice from 2011 to present in 37 different sites in Spain, collecting socio-demographics, smoking status, clinical and safety data at baseline, 3-, 6- and 12-month visits. Clinical outcomes were defined by completion of

EULAR Good/Moderate and DAS28 Remission. Drug survival was also assessed (Kaplan–Meier curve). A total of 501 RA patients were included: 78.6% women, mean age 53.6 yr (± 13.2 SD), 23% were aged >65 yr; mean disease duration 7.5 yr (± 7.3 SD), 27.7% having early RA (<2 yr); prior csDMARD number 1.5 (± 1.1 SD); mean prior bDMARD number was 0.8 (± 1.2 SD); mean exposure time to CZP was 9.8 months (± 3.4 SD); concomitant steroids intake 12.6%, csDMARD 24.2% and csDMARD plus steroids 54.9%; 69.8% never smoked, 12.9% former smoker and 17.3% current smoker. A total of 135 discontinued CZP (27%). Clinical and treatment outcomes are shown in Table 1, statistically significant improvement in all parameters at 12-month visit compared to baseline was observed. 12-month EULAR Response was reached in 69.8% of patients, 64.4% when using CZP as 2nd-line treatment after 1st-bDMARD clinical failure ($N = 90$, data not shown). 12-month DAS28 Remission was achieved in 40.5% of patients (34.4% in 2nd-line). Overall CZP 12-month survival was 73.1%. We found CZP survival rate in bio-naïve patients was higher than in those who used previous bDMARD, 77.2% vs. 68.5% ($p = 0.029$), respectively (Fig. 1).