




Sociedad Española
de Reumatología -
Colegio Mexicano
de Reumatología

Reumatología Clínica

www.reumatologiaclinica.org



Images in Clinical Rheumatology

The bull's head sign of SAPHO syndrome[☆]

Signo de la cabeza de toro en el síndrome SAPHO

Pablo Finucci Curi,^{a,*} Lorena Ramos,^b Mariela Agolti^c

^a Sección de Reumatología, Hospital San Martín, Paraná, Argentina

^b Sección de Dermatología, Hospital San Martín, Paraná, Argentina

^c Departamento de Medicina Nuclear, Clínica Modelo, Paraná, Argentina



ARTICLE INFO

Article history:

Received 18 November 2019

Accepted 10 December 2019

Available online 26 October 2020

SAPHO syndrome (synovitis, acne, pustulosis, hyperostosis and osteitis) is a rare and under-diagnosed chronic inflammatory disorder with cutaneous and osteoarticular manifestations of unknown aetiology. Although previously included within the spondyloarthropathies, recent evidence suggests it is a pri-

mary inflammatory osteitis in the spectrum of autoinflammatory diseases.¹ We present the case of a 17-year-old male with no known history, with a history of acne fulminans (Fig. 1A) of 7 months' duration and pain in the anterior aspect of the thorax and both hips of 2 months' duration. Chest and pelvic X-rays and pelvic

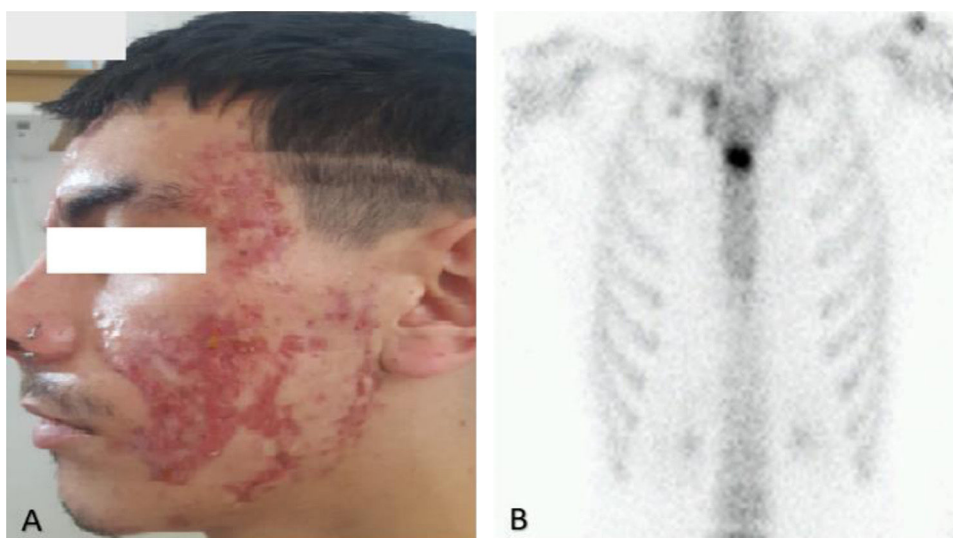


Fig. 1. (A) Acne fulminans. (B) Bull's head sign on bone scan.

[☆] Please cite this article as: Finucci Curi P, Ramos L, Agolti M. Signo de la cabeza de toro en el síndrome SAPHO. Reumatol Clin. 2021;17:298–301.

* Corresponding author.

E-mail address: pablofinu@hotmail.com (P. Finucci Curi).

tomography were normal. The bone scan showed a symmetrical increase in tracer uptake in the sacroiliac joints and sternoclavicular region, with a “bull’s head” appearance (Fig. 1B), pathognomonic of the disease.² The patient was treated with low-dose steroids, methotrexate and doxycycline, achieving resolution of the joint symptoms and slight improvement of the acne.

Although there are no validated diagnostic criteria for SAPHO syndrome, those formulated by Benhamou et al. may be useful.³ Radiography that can demonstrate osteolysis, sclerosis, periosteal reaction and enthesopathy, is often normal, and its usefulness is limited when there is involvement of the upper thorax. Tomography is the best technique for evaluating the upper chest wall and particularly the sternoclavicular joints; the most common findings are bone sclerosis, erosions and hyperostosis.⁴ The bone scan is very valuable, since increased tracer uptake checks all affected bones and helps rule out infection and malignancy. In addition, it is useful to evaluate the response to treatment,² since it is a very sensitive technique that has excellent correlation with tomography.⁴ From the bone scan osteoarticular involvement can be classified into 3 types, with different clinical characteristics: sternoclavicular, costal and spinal.⁵ The image similar to a bull’s head was first described in nuclear medicine in 1994,⁶ in which the head corresponds to increased tracer uptake by the sternal manubrium joint and the horns to the sternoclavicular joints. There are no standardized treatment protocols available, although different drugs with variable response have been tested, such as NSAIDs, systemic corticosteroids, doxycycline, pamidronate, immunosuppressants, anti-TNF and anti-IL-1.^{1,7,8}

Conflict of interests

The authors have no conflict of interests to declare.

References

1. Firinu D, Garcia-Larsen V, Manconi PE, del Giacco SR. SAPHO syndrome: current developments and approaches to clinical treatment. *Curr Rheumatol Rep.* 2016;18:35, <http://dx.doi.org/10.1007/s11926-016-0583-y>.
2. Nguyen MT, Borchers A, Selmi C, Naguwa SM, Cheema G, Gershwin ME. The SAPHO syndrome. *Semin Arthritis Rheum.* 2012;42:254–65, <http://dx.doi.org/10.1016/j.semarthrit.2012.05.006>.
3. Benhamou CL, Chamot AM, Kahn MF. Synovitis-acne-pustulosis-hyperostosis-osteomyelitis syndrome (SAPHO). A new syndrome among the spondyloarthropathies? *Clin Exp Rheumatol.* 1988;6(2):109–12.
4. Sallés M, Olivé A, Perez-Andres R, Holgado S, Mateo L, Riera E, et al. *Clin Rheumatol.* 2011;30:245–9, <http://dx.doi.org/10.1007/s10067-010-1560-x>.
5. Cao Y, Li C, Yang Q, Wu N, Xu P, Li Y, et al. Three patterns of osteoarticular involvement in SAPHO syndrome: a cluster analysis based on whole body bone scintigraphy of 157 patients. *Rheumatology (Oxford).* 2019;58:1047–55.
6. Kasperczyk A, Freyschmidt J. Pustulotic arthroosteitis: spectrum of bone lesions with palmoplantar pustulosis. *Radiology.* 1994;191:207–11.
7. Colina M, La Corte R, Trotta F. Sustained remission of SAPHO syndrome with pamidronate: a follow-up of fourteen cases and a review of the literature. *Clin Exp Rheumatol.* 2009;27:112–5.
8. Abourazzak FE, Hachimi H, Kadi N, Berrada K, Tizniti S, Harzy T. Etanercept in the treatment of SAPHO syndrome: which place? *Eur J Rheumatol.* 2014;1:125–8, <http://dx.doi.org/10.5152/eurjrheumatol.2014.037>.