




Sociedad Española
de Reumatología -
Colegio Mexicano
de Reumatología

Reumatología Clínica

www.reumatologiaclinica.org



Case Report

Temporal arteritis in a young patient. A clinical case[☆]

Silvia Blanco-Alonso,^{a,*} Susana Mellor-Pita,^a Fernando Alfageme,^b Laura Najera Botella,^c
Pedro Duran-Campo,^a Pablo Tutor-Ureta^a

^a Servicio Medicina Interna, Hospital Universitario Puerta de Hierro Majadahonda, Madrid, Spain

^b Servicio Dermatología, Hospital Universitario Puerta de Hierro Majadahonda, Madrid, Spain

^c Servicio Anatomía Patológica, Hospital Universitario Puerta de Hierro Majadahonda, Madrid, Spain



ARTICLE INFO

Article history:

Received 7 January 2020

Accepted 10 April 2020

Available online 3 December 2020

Keywords:

Juvenile arteritis

Kimura disease

ABSTRACT

Introduction: Temporal arteritis is an uncommon disorder in young people. A 39-year-old woman with juvenile temporal arteritis is described and we performed a literature review of all cases of juvenile temporal arteritis described to date.

Case presentation: A 39-year-old woman presented with a subcutaneous temporal nodule in the right temple with no other associated symptoms or background and unremarkable physical examination. Ultrasonography of the nodule revealed an anechoic perivascular halo surrounding the temporal artery. The nodule was excised resulting in the patient's recovery. The results of the histopathological study showed features of juvenile temporal arteritis.

Conclusions: Juvenile temporal arteritis is a very uncommon disorder. Systemic manifestations should be ruled out by physical examination and complementary tests. Histopathology establishes the definitive diagnosis. Treatment is surgical excision and a follow-up should be conducted to rule out complications.

© 2020 Elsevier España, S.L.U. and Sociedad Española de Reumatología y Colegio Mexicano de Reumatología. All rights reserved.

Arteritis de la temporal en paciente joven. A propósito de un caso clínico

RESUMEN

Introducción: La arteritis de la temporal es un proceso infrecuente en paciente jóvenes. Se presenta el caso de una paciente de 39 años con arteritis de la temporal con revisión de casos descritos hasta el momento. **Presentación del caso:** Mujer de 39 años sin antecedentes de interés que consulta por un nódulo subcutáneo temporal derecho, sin otros síntomas ni hallazgos a la exploración. En las pruebas realizadas destacaba la presencia de signo del halo ecográfico alrededor de la arteria temporal en la localización del nódulo. Se realizó escisión con curación de la paciente y la histopatología mostró hallazgos de arteritis temporal juvenil.

Conclusiones: La arteritis temporal en pacientes jóvenes es una entidad infrecuente, ante la cual siempre hay que descartar manifestaciones sistémicas mediante una anamnesis, exploración física reglada y pruebas complementarias. La anatomía patológica establecerá el diagnóstico definitivo. El tratamiento suele ser quirúrgico. Tras dicho tratamiento, se deberá seguir a la paciente por el posible desarrollo posterior de otras enfermedades.

© 2020 Elsevier España, S.L.U. y Sociedad Española de Reumatología y Colegio Mexicano de Reumatología. Todos los derechos reservados.

Palabras clave:

Arteritis temporal juvenil

Enfermedad de Kimura

[☆] Please cite this article as: Blanco-Alonso S, Mellor-Pita S, Alfageme F, Najera Botella L, Duran-Campo P, Tutor-Ureta P. Arteritis de la temporal en paciente joven. A propósito de un caso clínico. Reumatol Clin. 2021;17:295–297.

* Corresponding author.

E-mail address: blancoalonsosilvia@gmail.com (S. Blanco-Alonso).

Table 1
Cases of juvenile arteritis described in the literature.

	N of cases	Sex	Age	Manifestation	Pathological anatomy	Treatment	Outcome
Meyers 1948	1	F	22	Temporal headache	IH, periarteritis	Excision	Cure
Bethlenfalvay 1964	1	M	35	Headache	IH, intraluminal thrombus	Corticosteroids	Recurrence of headache after discontinuation
Lie et al., 1975 ⁶ and 1995	5	4M/1F	7/8/21/22	Palpable nodule without headache	IP with lymphocytes and Eo	Excision/corticosteroids	Resolution
Bollinger et al., 1986	1	M	23	Tortuous temporal	NF, CG, IE	No treatment	No changes
Tomlinson et al., 1994 ⁷	1	M	8	Painful nodule	PI, IE	Excision	Resolution
Fielding 1994	1	M	30	Temporal pain	IH with mononuclear infiltration	Excision	No recurrence
Fujimoto et al., 1996	1	M	39	Nodule	PI, IE, Microaneurysms	Tocopherol/nicotinamide	No changes
Andonopoulos 2004	1	M	31	Growing mass, eosinophilia	IE, Intimal disruption	Excision	Cure
Brown 2005 ⁸	1	M	38	Painless temporal nodule	Panarteritis with EI, follicular hyperplasia	Excision	Cure
Fukunaga 2005	1	M	23	Painless temporal nodule, Eosinophilia	Panarteritis with EI	Excision	No recurrence
Nesher 2008 ⁵	1	M	18	Temporal pulsating nodule	Non-granulomatous panarteritis, no EI	Excision	No recurrence
Kolman 2010 ⁹	1	F	36	Painful nodule, headache	Extravascular lymphocyte infiltration with Eo	Excision	Persistence of headache
Durant 2011 ²	1	F	44	Temporal headache	Non-granulomatous panarteritis, EI	Excision	Cure
Mcgeoch 2012 ³	2	M	31/40	Painful nodule/Headache	Panarteritis, GC/NGC infiltration	Excision/Corticosteroids	Cure
Journeau ¹⁰	12	10 M/2F	38.5	Headache/Painful nodule	Periarteritis, IH, EI, IP	Excision/corticosteroids	Cure/ Recurrence 2
Current	1	M	39	Painful nodule	IH, EI, IF	Excision	Cure

EI: Eosinophilic infiltration; Eo: Eosinophils; F: Female; FN: Fibrinoid necrosis; GC: Giant cells; IF: Intimal fibrosis; IH: Intimal hyperplasia; IP: Intimal proliferation; M: Male; NGC: Non-giant cells;

Introduction

We present a review of the cases to date of temporal artery vasculitis in young patients in relation to a case in a 39-year-old patient.

Presentation of the case

This is an obese female, smoker of 25 packs/year and with hypoventilation-obesity syndrome treated with continuous positive airway pressure (CPAP). She was under treatment with fluoxetine and clordiazepoxide for reactive depression and had no personal or family history of rheumatological disease.

A tumour was found of 1 cm in diameter in the left temporal region, not painful with local bleeding after scratching and minimal growth over the last three months. She reported bitemporal headache of tension characteristics of one year's duration. She did not present girdle weakness, impaired vision, joint symptoms, or other signs of systemic disease. On examination this nodule was slightly sensitive and with a palpable pulse, with no other findings.

Complementary tests were performed showing a normal haemogram, with a first-hour erythrocyte sedimentation rate of 8 mm (normal 0–25), C-reactive protein 4.4 mg/L (0–10), coagulation tests with no abnormalities and complete biochemistry with nutritional profile, liver tests, renal function, thyroid function, ions, ferrokinetic profile, vitamin B12, vitamin D and folic acid within normal limits. The proteinogram, quantification of immunoglobulins including IgE, antinuclear antibodies and neutrophil antibody, rheumatoid factor and complement were negative or normal. Syphilis, HIV and hepatotropic virus serologies were negative. Chest X-ray, ophthalmological examination and urinary sediment were performed without findings. An ultrasound scan of the nodular zone was performed, and a halo in the shape of a hypoechogenic

perivascular cuff and with arterial flow was obtained, suggesting a branch of the temporal artery (Fig. 1).

The lesion was excised which revealed an artery with hyperplasia and intimal fibrosis, and presence in the periarterial connective tissue of an angiolymphoid hyperplasia with some eosinophils. No multinucleated giant cells were observed. This microscopic description is compatible with juvenile arteritis.

Discussion

Ultrasound findings in the presence of giant cell arteritis are described in Maldini et al.¹ in patients under 50 years of age and arise in a young patient in the case of Durant et al.² In the case of a temporal arteritis in a young patient, a differential diagnosis should be considered between juvenile temporal arteritis, giant cell arteritis and temporal arteritis in the context of a systemic vasculitis, due to both prognosis and the different treatment possibilities.³

The most common temporal arteritis is giant cell arteritis. It is a segmental granulomatous vasculitis of large and medium vessels. It is rare in young patients and 99% of cases occur in patients over 50 years of age.

Temporal arteritis has been described in association with different systemic vasculitis: polyarteritis nodosa,⁴ eosinophilic granulomatosis, granulomatosis with polyangiitis, or even vasculitis secondary to infections (borreliosis, syphilis, human immunodeficiency virus).⁵ In these cases, it is usually accompanied by manifestations in other locations, analytical findings of an immunological nature or radiological manifestations.

Juvenile temporal arteritis is a condition described for the first time by Lie et al.⁶ In 1994, Tomlinson described some diagnostic criteria associated with this entity⁷ that were used for the diagnosis of our patient: onset in children and young people, absence of associated manifestations such as myalgias, visual alterations, fever,

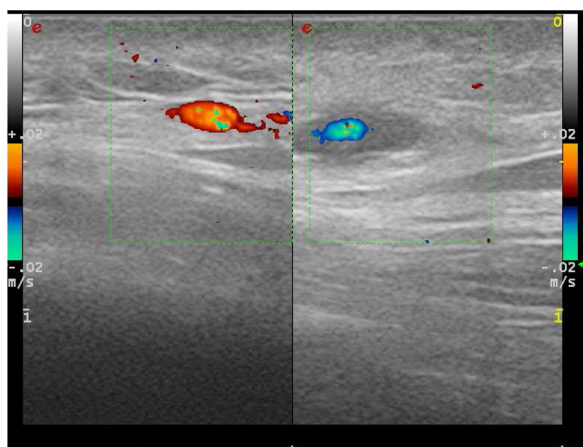


Fig. 1. Doppler ultrasound with linear probe on palpable painful nodule. On the right, we can see a perivascular hypoechoic area corresponding to a clinical nodule. On the left, contralateral temporal artery without signs of disease.

anaemia, painless temporal nodule, normal sedimentation rate, eosinophilic panarteritis and thrombosis with or without microaneurysmal rupture of the artery, intimal proliferation, disruption of the media and extensive infiltration consisting of lymphocytes, eosinophils and plasma cells, absence of granulomatous infiltration and giant cells. Described cases of juvenile arteritis have subsequently appeared which as they progressed were associated with different processes, including Kimura's disease^{8,9} in these cases linked to eosinophilia, lymph node and salivary involvement, T lymphoma and angiolymphoid hyperplasia with eosinophilia (ALHE), a rare disease characterised by single or multiple angioma-tous lesions usually located on the scalp and face.

We reviewed the cases of juvenile arteritis described in the literature, including the cases recently described in the French multicentre experience¹¹ (Table 1). A total of 32 patients have been described, the condition being more frequent among males (26 cases) with an average age of 32.5 years (between 7 and 44 years). In terms of clinical presentation, 31.2% debuted with headache and

65.6% with palpation of a nodule. Seventy-five percent were treated with surgical excision without subsequent recurrence, with persistence of headache in one patient. Other treatments were systemic corticosteroids in combination with surgery, or as the only treatment in one case whose headache recurred after the corticosteroids were discontinued. In our case, after surgical excision of the lesion, the patient was asymptomatic, with no other manifestations or development of complications after 18 months of follow-up.

Juvenile arteritis is a rare entity, which requires a high rate of suspicion. It usually manifests with local symptoms such as a nodule or temporal headache and may show ultrasound halo signs like temporal arteritis. The outcome is usually favourable, with recovery in most patients after surgical excision.

References

- Maldini C, Dépinau-Dhellemmes C, Tra TT, Chauveau M, Allanore Y, Gossec L, et al. Limited value of temporal artery ultrasonography examinations for diagnosis of giant cell arteritis: Analysis of 77 subjects. *J Rheumatol*. 2010;37:2326–30, <http://dx.doi.org/10.3899/jrheum.100353>.
- Durant C, Connault J, Graveleau J, Toquet C, Brisseau JM, Hamidou M. Juvenile temporal vasculitis: a rare case in a middle-aged woman. *Ann Vasc Surg*. 2011;25:23–5, <http://dx.doi.org/10.1016/j.avsg.2010.10.006>.
- McGeoch L, Silecky WB, Maher J, Carette S, Pagnoux C. Temporal arteritis in the young. *Jt Bone Spine*. 2013;80:324–7, <http://dx.doi.org/10.1016/j.jbspin.2012.09.012>.
- Bert RJ, Antonacci VP, Berman L, Melhem ER. Polyarteritis nodosa presenting as temporal arteritis in a 9-year-old child. *Am J Neuroradiol*. 1999;20:167–71.
- Nesher G, Oren S, Lijovetzky G, Nesher R. Vasculitis of the temporal arteries in the young. *Semin Arthritis Rheum*. 2009;39:96–107, <http://dx.doi.org/10.1016/j.semarthrit.2008.03.001>.
- Lie JT, Gordon LP, Titus JL. Juvenile temporal arteritis: biopsy study of four cases. *JAMA*. 1975;234:496–9, <http://dx.doi.org/10.1001/jama.1975.03260180036019>.
- Tomlinson FH, Lie JT, Nienhuis BJ, Konzen KM, Groover RV. Juvenile temporal arteritis revisited. *Mayo Clin Proc*. 1994;69:445–7, [http://dx.doi.org/10.1016/S0025-6196\(12\)61641-3](http://dx.doi.org/10.1016/S0025-6196(12)61641-3).
- Brown I, Adkins G, McClymont K. Juvenile temporal arteritis: a case report. *Pathology*. 2005;37:559–60, <http://dx.doi.org/10.1080/00313020500368386>.
- Kolman OK, Spinelli HM, Magro CM. Juvenile temporal arteritis. *J Am Acad Dermatol*. 2010;62:308–14, <http://dx.doi.org/10.1016/j.jaad.2009.04.013>.
- Journeau L, Pistorius M, Michon-pasturel U, Lambert M, Labèpie F, Bura-Riviere A, et al. Autoimmunity Reviews Juvenile temporal arteritis: a clinicopathological multicentric experience. *Autoimmun Rev*. 2019;18:476–83, <http://dx.doi.org/10.1016/j.autrev.2019.03.007>.