




Sociedad Española  
de Reumatología -  
Colegio Mexicano  
de Reumatología



## Images in Clinical Rheumatology

### Synovial osteochondromatosis of the knee

### Osteocondromatosis sinovial de la rodilla

Sreoshy Saha<sup>a</sup>, Latika Gupta<sup>b,\*</sup>

<sup>a</sup> Mymensingh Medical College, Mymensingh, Bangladesh

<sup>b</sup> Department of Clinical Immunology, Sanjay Gandhi Postgraduate Institute of Medical Sciences, C block, Rai Bareilly Road, 226014 Lucknow, India

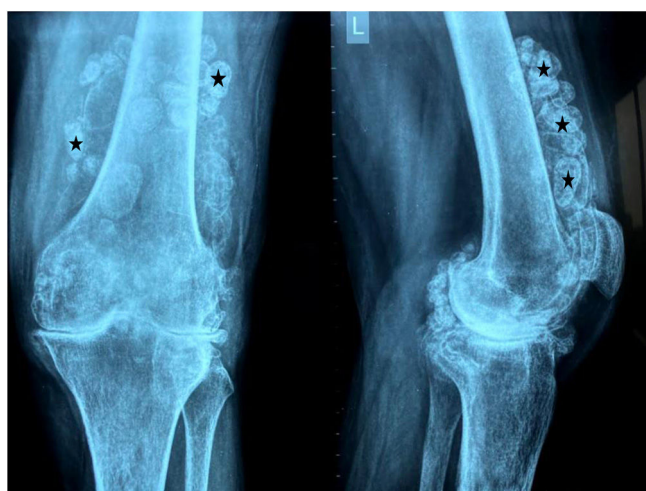


#### ARTICLE INFO

##### Article history:

Received 30 November 2020

Accepted 10 December 2020



**Fig. 1.** Anteroposterior and lateral radiographs of knee. Multiple loose calcified bodies are seen within it (asterisks).

A 55-year-old lady presented in the outpatient clinic, with the complaints of mechanical knee pain of three-year duration. Radiographs (Fig. 1) of the knee were suggestive of multiple loose radio-opaque calcified bodies around the knee joint.

The radiographs are pathognomonic of Synovial Osteochondromatosis, an atypical neoplastic disease, with an occurrence rate of 1 in 100,000 people.<sup>1</sup> People are likely to get affected by Syno-

vial Osteochondromatosis in their 3rd to 5th decades of life, occurs almost 2 times more frequently in men than women. The pathogenesis includes hyperplastic metaplasia of connective tissue where hyaline cartilage gets calcified into multiple intra-articular loose bodies in synovial tissues, within the joint, bursa or tendon sheaths. Though knee is mostly affected, hip, shoulder, ankle, elbow, and wrist joints can also be affected. Joint swelling and tenderness, locking, pain, restrictions of range of motion in affected joints are some common clinical features. This disease has potential to transform into chondrosarcoma, in very few cases.<sup>2</sup> Surgical excision of the chondromal nodules and synovectomy are the mainstay of treatment to prevent late degenerative transformation. Overall with a reported recurrence of 3–60% in primary disease, the recurrence rate goes below 10% after surgery.<sup>1,2</sup>

#### Ethics approval and consent to participate

Participant provided informed consent for the photographs included in this paper.

#### Availability and data sharing

The data used during the current study is available from the corresponding author on reasonable request.

#### Consent for publication

Consent for publication of pictures was given by the participant.

#### Disclosure

The authors have nothing to disclose.

\* Corresponding author.

E-mail address: [drlatikagupta@gmail.com](mailto:drlatikagupta@gmail.com) (L. Gupta).

### **Contributions**

All authors were involved in manuscript ideation and preparation.

### **Funding**

This research did not receive any specific grant from funding agencies in the public, commercial, or not-for-profit sectors.

### **Conflict of interest**

None.

### **Acknowledgements**

The authors thank Connecting Researchers and Dr Mallke Asaad for their help with this work.

### **References**

1. Díaz Fernández JF, Peraza Mc Liberty RA. Synovial osteochondromatosis of the shoulder: case report and literature review. *Reumatol Clin.* 2018;14:56–8, <http://dx.doi.org/10.1016/j.reumae.2017.09.001>.
2. Khodae M, Seyfert J. Not a typical case of bilateral knee osteoarthritis. *BMJ.* 2016;352, <http://dx.doi.org/10.1136/bmj.i39>.