




Sociedad Española
de Reumatología -
Colegio Mexicano
de Reumatología

Reumatología Clínica

www.reumatologiaclinica.org



Letter to the Editor

A small dose of intraarticular triamcinolone plus mepivacaine provides a rapid and sustained relief for gout flares



Una pequeña dosis de triamcinolona intraarticular más mepivacaína proporciona un alivio rápido y sostenido de los ataques de gota

Dear Editor:

Most patients describe gout attacks as especially painful. Effective treatments – colchicine, NSAIDs, systemic or intra-articular corticosteroids, interleukin-1 blockers – result in an effective resolution of the attacks; however, it usually requires 1–3 days^{1–4} to relieve the symptoms, and at least a few hours to start lessening them. After an initial observation, intra-articular triamcinolone with added 2% mepivacaine has become a usual procedure in our clinics, as we have repeatedly observed a very rapid and persistent subsidence of pain. Here we aimed to prospectively document this outcome.

Consecutive patients with crystal-proven gout, suffering from an acute, monoarticular and still untreated flare were recruited. All cases were treated with an intra-articular injection of triamcinolone acetonide (16 mg in knees, 8 mg in 1st metatarso-phalangeal (1stMTP) joint and 12 mg in intermediate sized joints) adding 2 ml of 2% mepivacaine in knees, 1–1.5 ml

in intermediate sized joints, and 0.2–0.4 ml in 1stMTP joints, in accordance to our usual clinical practice.⁵ Joint pain was registered using a 0–4 Likert semiquantitative scale (0 = absent; 4 = severe) at baseline and 15 min, 6 h, 24 h, and 72 h after the injection. Presence of joint swelling and erythema were also collected at baseline and after 72 h. Treatment response after 72 h was evaluated by both the physician and the patient on a 0–4 Likert scale (0 = no effect; 4 = complete resolution). Between-after comparisons were analysed using Friedman and Wilcoxon signed-rank tests.

Twenty-four patients were recruited; median (\pm SD) aged 64.8 years (\pm 12.7), 22 males. Involved joints were sixteen 1stMTPs, five knees, two wrists, and one ankle. Median (p25–75) pain score at baseline was 3 (2.0–3.8), joint swelling was present in all cases, and in 13 cases (54.2%) erythema was observed. After a few minutes of the intra-articular injection, a rapid pain reduction was observed and maintained up to 72 h, the end of the registrations, as patients reported it (Fig. 1). In only three cases (12.5%), all with 1stMTP attacks, the pain intensity rebounded between 15 min and 6 h after the injection. Treatment was clearly effective as assessed by both patients and rheumatologists (3 (3–4) and 3.5 (3–4), respectively).

This small study supports our observation from clinical practice: adding mepivacaine to a low dose of intra-articular triamcinolone acetonide leads to an almost immediate relief of gout attacks, with a clear response even 15 min after the injection and maintenance of a symptom – free to tolerable pain until subsidence of the symptoms.

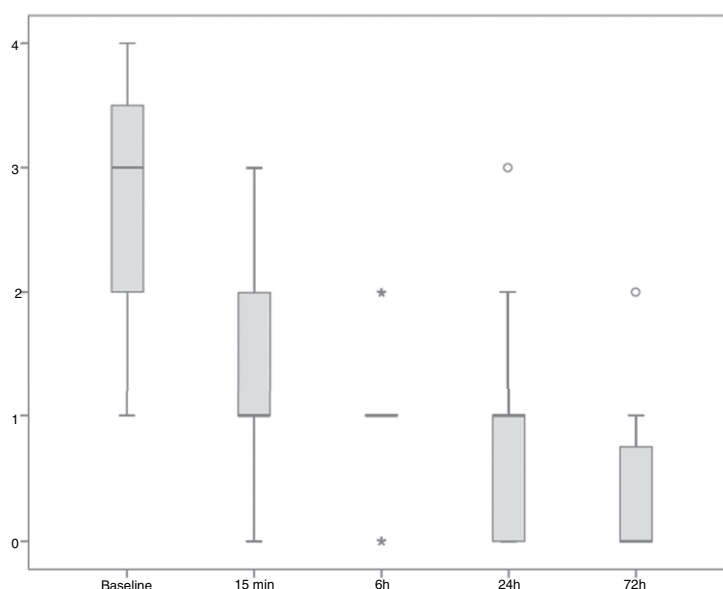


Fig. 1. Pain assessed by the study participants on a 0–4 Likert semiquantitative scale during the follow-up. $P < 0.001$ for the whole pain reduction throughout the study. $P < 0.001$ for all the individual comparisons between 15 min, 6 h, 24 h and 72 h time-points and baseline.

The almost immediate pain relief can be attributed to mepivacaine. There are few data on the duration of anaesthesia with this agent, but when used for brachial plexus blockade, it lasts between 3 and 4 h.⁶ Interestingly, dexamethasone added to mepivacaine in brachial plexus anaesthesia prolonged the time of anaesthesia from a mean of 228 min up to 332 min, a highly significant change.⁷ A similar effect may occur when triamcinolone and mepivacaine are conjointly injected in a joint affected by a gout flare. An early effect of triamcinolone on the synovial irrigation could reduce the local inflammation-related blood flow, retarding mepivacaine clearance from the joint. The pain reappeared in a number of patients after its initial marked reduction, but with a moderate intensity, likely indicating that by that time, the steroid action has already begun; afterwards the flare totally subsided, although the total time to subsidence in some patients maybe as long as it would be if only steroids would have been injected. These results were highly welcomed both by physicians and especially by patients.

Funding

This study had no external funding source

Conflict of interest

MA has received speaking and advisory fees from Menarini, Grünenthal and Horizon. FS has received speaking and advisory fees from Menarini, Grünenthal and Horizon. The rest of authors declare no conflicts of interest in relation to this work.

References

1. Terkeltaub RA, Furst DE, Bennett K, Kook KA, Crockett RS, Davis MW. High versus low dosing of oral colchicine for early acute gout flare: twenty-four-hour outcome of the first multicenter, randomized, double-blind, placebo-controlled, parallel-group, dose-comparison colchicine study. *Arthritis Rheum.* 2010;62:1060–8.
2. Rubin BR, Burton R, Navarra S, Antigua J, Londoño J, Pryhuber KG, et al. Efficacy and safety profile of treatment with etoricoxib 120 mg once daily compared with indomethacin 50 mg three times daily in acute gout: a randomized controlled trial. *Arthritis Rheum.* 2004;50:598–606.
3. van Durme CM, Wechalekar MD, Buchbinder R, Schlesinger N, van der Heijde D, Landewé RB. Non-steroidal anti-inflammatory drugs for acute gout. *Cochrane Database Syst Rev.* 2014. CD010120.
4. Schlesinger N, Alten RE, Bardin T, Schumacher HR, Bloch M, Gimona A, et al. Canakinumab for acute gouty arthritis in patients with limited treatment options: results from two randomised, multicentre, active-controlled, double-blind trials and their initial extensions. *Ann Rheum Dis.* 2012;71:1839–48.
5. Fernández C, Noguera R, González JA, Pascual E. Treatment of acute attacks of gout with a small dose of intra-articular triamcinolone acetate. *J Rheumatol.* 1999;26:2285–6.
6. Covino BC. Pharmacology of local anaesthetic agents. *Br J Anaesth.* 1986;58:701–16.
7. Parrington SJ, O'Donnell D, Chan VW, Brown-Shreves D, Subramanyam R, Qu M, et al. Dexamethasone added to mepivacaine prolongs the duration of analgesia after supraclavicular brachial plexus blockade. *Reg Anesth Pain Med.* 2010;35:422–6.

Mariano Andrés^{a,b}, Alejandra Begazo^c, Francisca Sivera^{d,b}, Paloma Vela^{a,b}, Pedro Zapater^{e,f}, Eliseo Pascual^{a,g,*}

^a Sección de Reumatología, Hospital General Universitario de Alicante, Instituto de Investigación Sanitaria y Biomédica de Alicante, Alicante, Spain

^b Departamento de Medicina Clínica, Universidad Miguel Hernández, Alicante, Spain

^c Sección de Reumatología, Hospital General Universitario Los Arcos del Mar Menor, Murcia, Spain

^d Sección de Reumatología, Hospital General Universitario de Elda, Alicante, Spain

^e Sección de Farmacología Clínica, Hospital General Universitario de Alicante, Instituto de Investigación Sanitaria y Biomédica de Alicante, Alicante, Spain

^f Departamento de Farmacología, Pediatría y Química Orgánica, Universidad Miguel Hernández, Alicante, Spain

^g Catedrático emérito de Medicina (Reumatología), Universidad Miguel Hernández, Alicante, Spain

* Corresponding author.

E-mail address: pascual.eli@gva.es (E. Pascual).