




Sociedad Española
de Reumatología -
Colegio Mexicano
de Reumatología

Reumatología Clínica

www.reumatologiaclinica.org



Images in Clinical Rheumatology

Hydroxychloroquine induced melanosis

Melanosis inducida por hidroxiclороquina

Beatriz Samões*, Joana Abelha-Aleixo, Patrícia Pinto, Romana Vieira

Rheumatology Department, Centro Hospitalar de Vila Nova de Gaia e Espinho, Vila Nova de Gaia, Portugal

ARTICLE INFO

Article history:

Received 13 June 2021

Accepted 23 September 2021

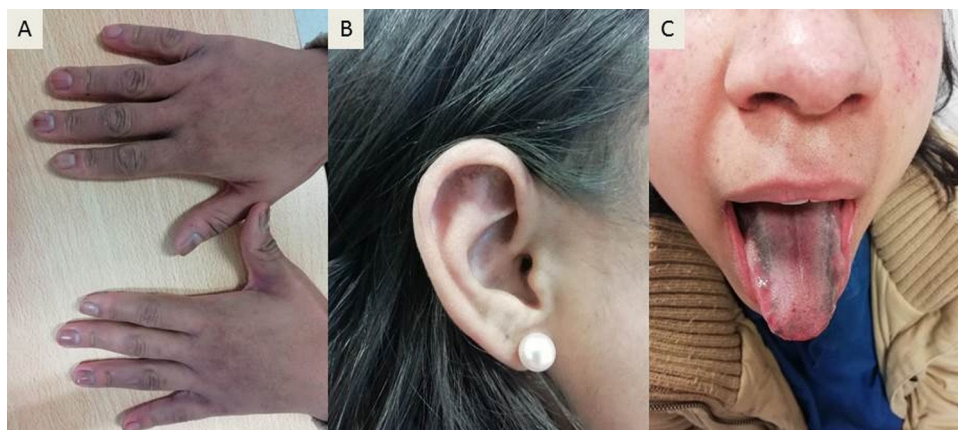

Fig. 1. Hydroxychloroquine induced melanosis. Hydroxychloroquine induced melanosis of the nails of the hands (Panel A), the scapha and triangular fossa of the ears (Panel B) and the tongue (Panel C).

A 29-year-old Brazilian woman with a previous diagnosis of Systemic Lupus Erythematosus with articular, cutaneous, serous and hematological involvement who immigrated to Portugal 7 months prior presented to our rheumatology department for continuation of care. She was chronically medicated with hydroxychloroquine 400 mg for the past 10 years as well as prednisolone 10 mg and levothyroxine 88 mcg. The objective examination showed hyperpigmentation of the nails of the hands (Fig. 1 – Panel A), the scapha and triangular fossa of the ears (Fig. 1 – Panel B) and the tongue (Fig. 1 – Panel C) that was suggestive of hydroxychloro-

quine induced hyperpigmentation. Other causes of pigmentary changes such as endocrine or metabolic disorders as well as other drug-induced pigmentation were excluded. An ophthalmologic evaluation with OCT was performed and retinopathy was excluded.

Hydroxychloroquine induced hyperpigmentation is an under-reported adverse event that may appear in about 10–25% of the patients after long-term use.^{1–3} It appears mainly on the anterior side of the legs but can also affect other less reported areas such as the nail bed, head, and mucosa.^{1,2,4} The pathogenesis of this adverse event is poorly understood.^{2,3} It is important to consider that hydroxychloroquine induced hyperpigmentation may mimic other pigmented conditions, namely melasma, Addison's disease, hemochromatosis, Wilson's disease and vitamins deficiencies.⁵ It usually improves after drug discontinuation.⁵

* Corresponding author.

E-mail address: bia_samoeshotmail.com (B. Samões).

Informed consent

Informed consent has been obtained from the patient.

Funding

This research did not receive any specific grant from funding agencies in the public, commercial, or not-for-profit sectors.

Conflict of interest

None.

References

1. Jallouli M, Francès C, Piette J-C, Huong DLT, Moguelet P, Factor C, et al. Hydroxychloroquine-induced pigmentation in patients with systemic lupus

- erythematosus: a case-control study. *JAMA Dermatol.* 2013;149:935–40, <http://dx.doi.org/10.1001/jamadermatol.2013.709>.
2. Eljaaly K, Alireza KH, Alshehri S, Al-Tawfiq JA. Hydroxychloroquine safety: a meta-analysis of randomized controlled trials. *Travel Med Infect Dis.* 2020;36:101812, <http://dx.doi.org/10.1016/j.tmaid.2020.101812>.
3. Sharma NA, Mesinkovska NA, Paravar T. Characterizing the adverse dermatologic effects of hydroxychloroquine: a systematic review. *J Am Acad Dermatol.* 2020;83:563–78, <http://dx.doi.org/10.1016/j.jaad.2020.04.024>.
4. Bahloul E, Jallouli M, Garbaa S, Marzouk S, Masmoudi A, Turki H, et al. Hydroxychloroquine-induced hyperpigmentation in systemic diseases: prevalence, clinical features and risk factors: a cross-sectional study of 41 cases. *Lupus.* 2017;26:1304–8, <http://dx.doi.org/10.1177/0961203317700486>.
5. Dereure O. Drug-induced skin pigmentation: epidemiology, diagnosis and treatment. *Am J Clin Dermatol.* 2001;2:253–62, <http://dx.doi.org/10.2165/00128071-200102040-00006>.